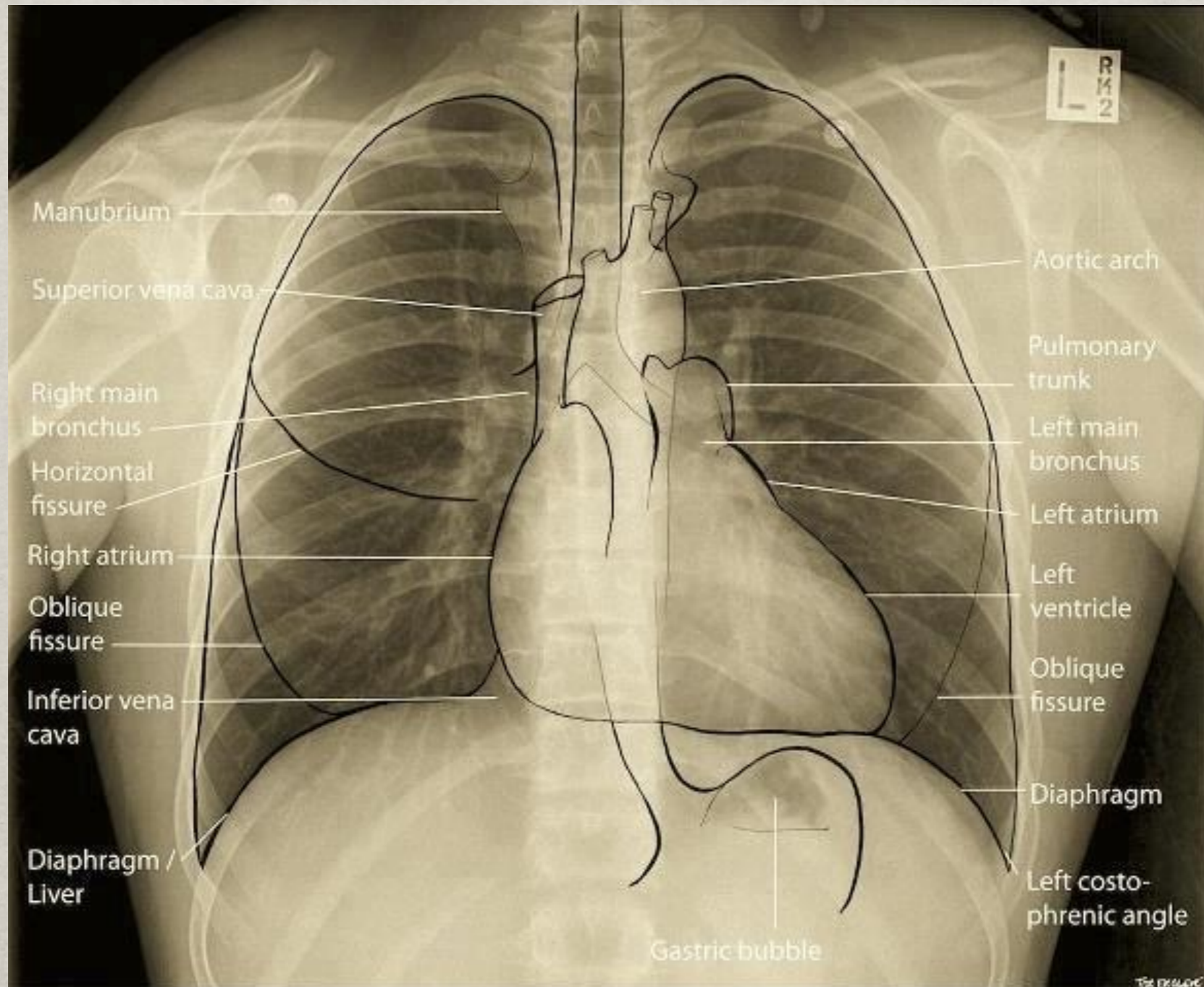


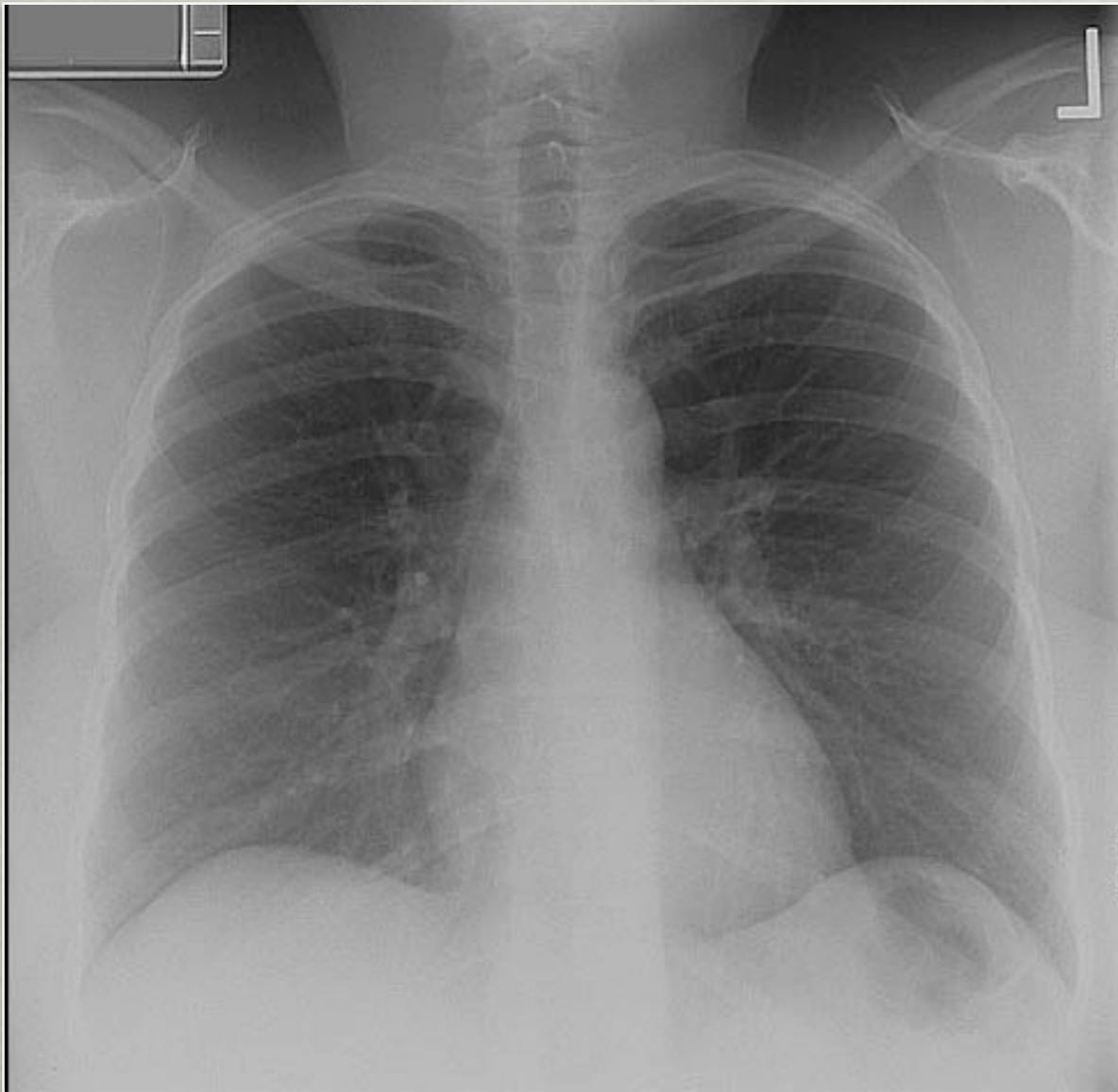
ΑΠΕΙΚΟΝΙΣΤΙΚΗ ΑΝΑΤΟΜΙΚΗ

ΘΩΡΑΚΑΣ

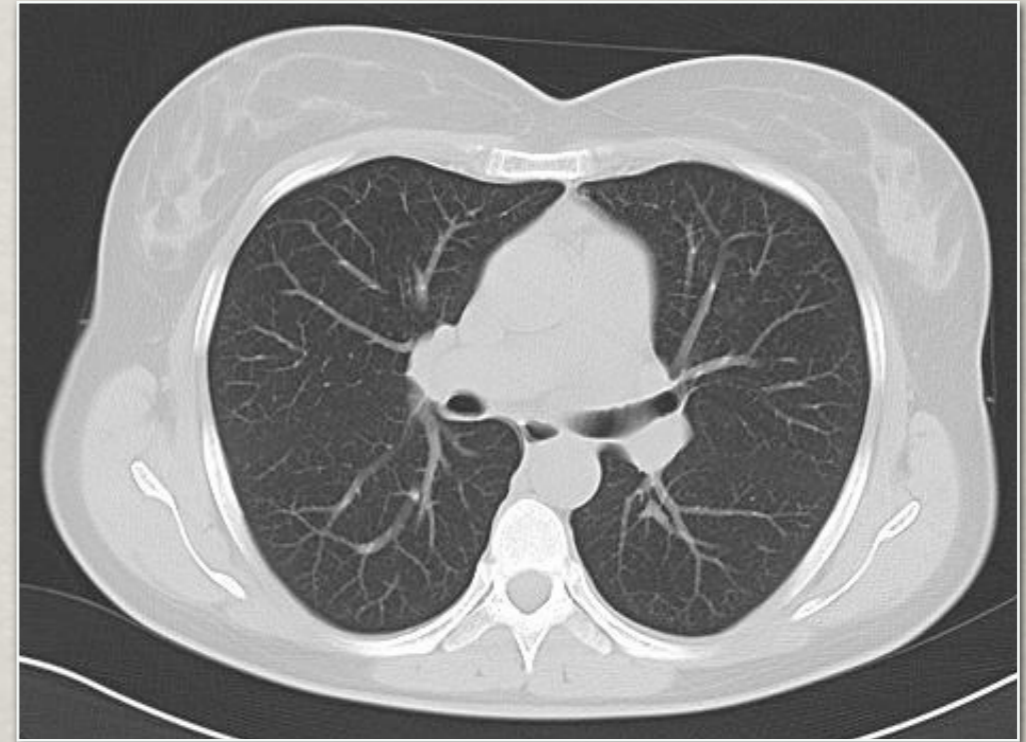


ΒΑΣΙΟΥ ΑΙΚΑΤΕΡΪΝΗ
ΑΝΑΠΛ. ΚΑΘ. ΑΝΑΤΟΜΙΑΣ ΙΑΤΡΙΚΟΥ ΤΜΗΜΑΤΟΣ
ΠΑΝ/ΜΙΟΥ ΘΕΣΣΑΛΙΑΣ

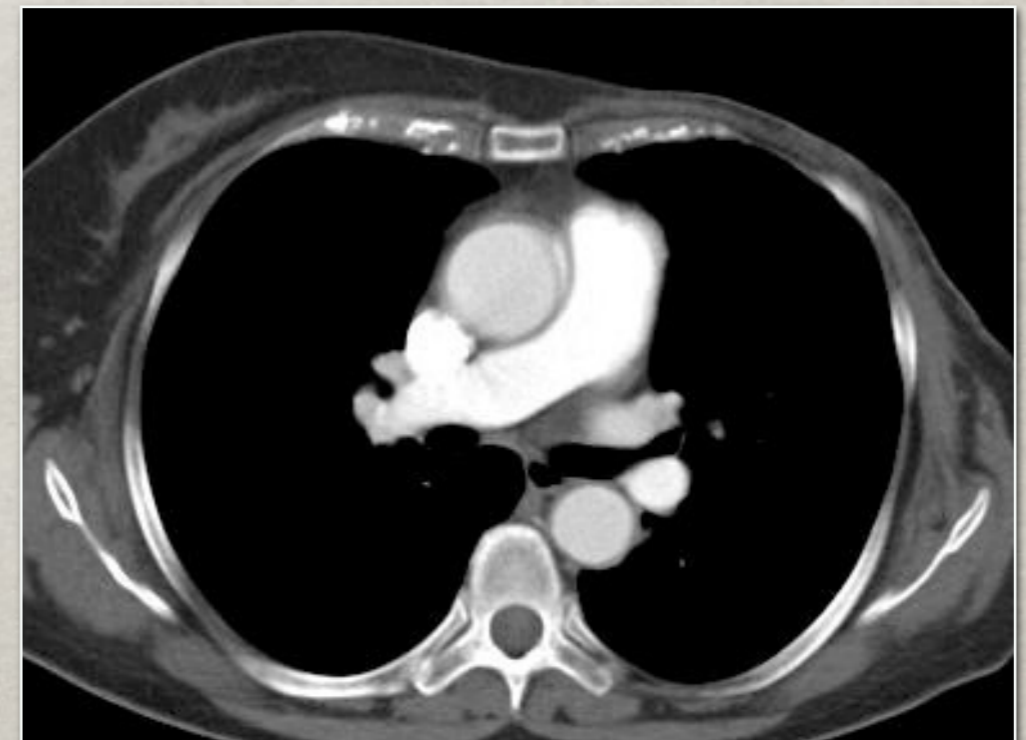


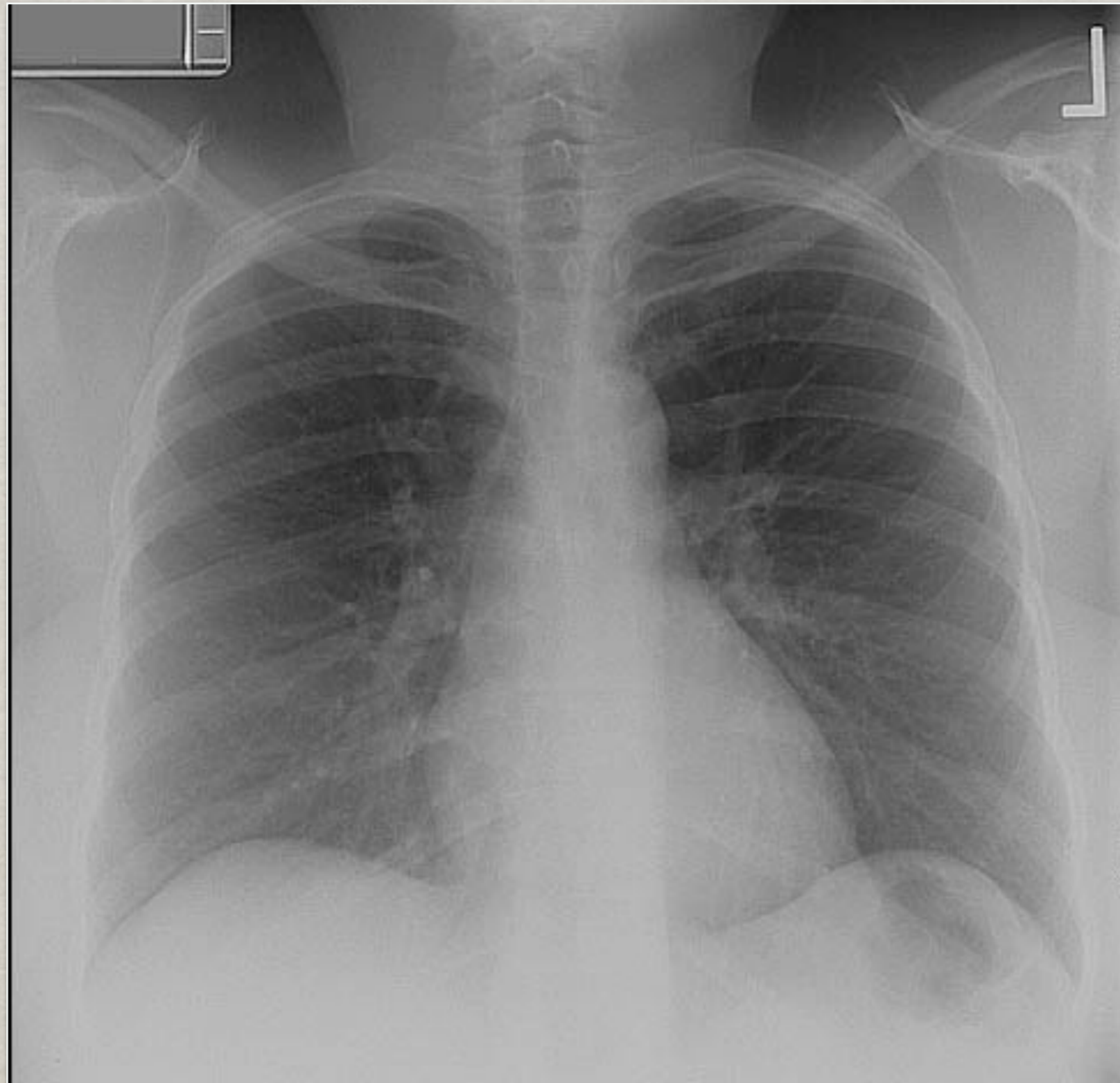


Απλή ακτινογραφία θώρακος

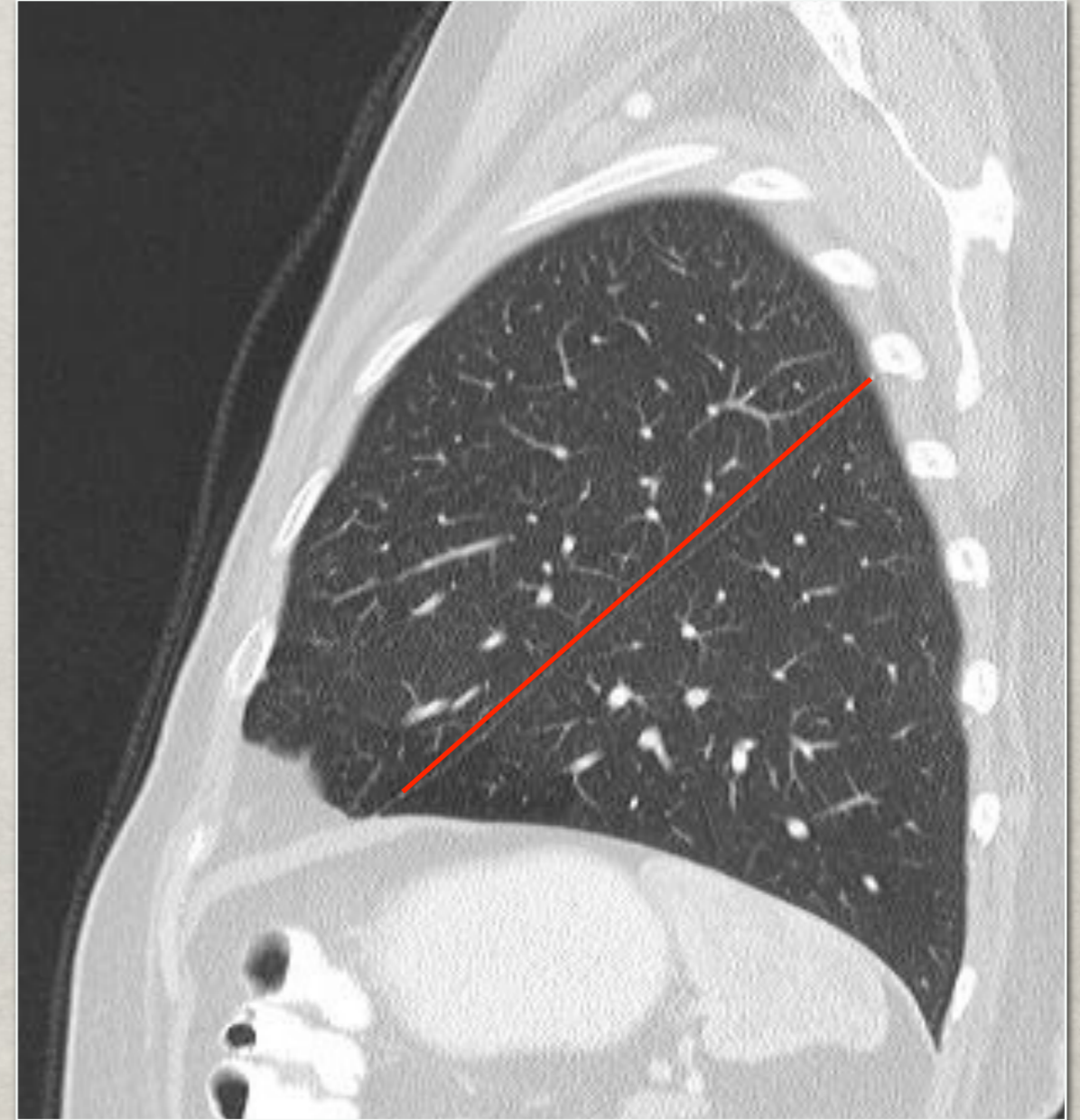
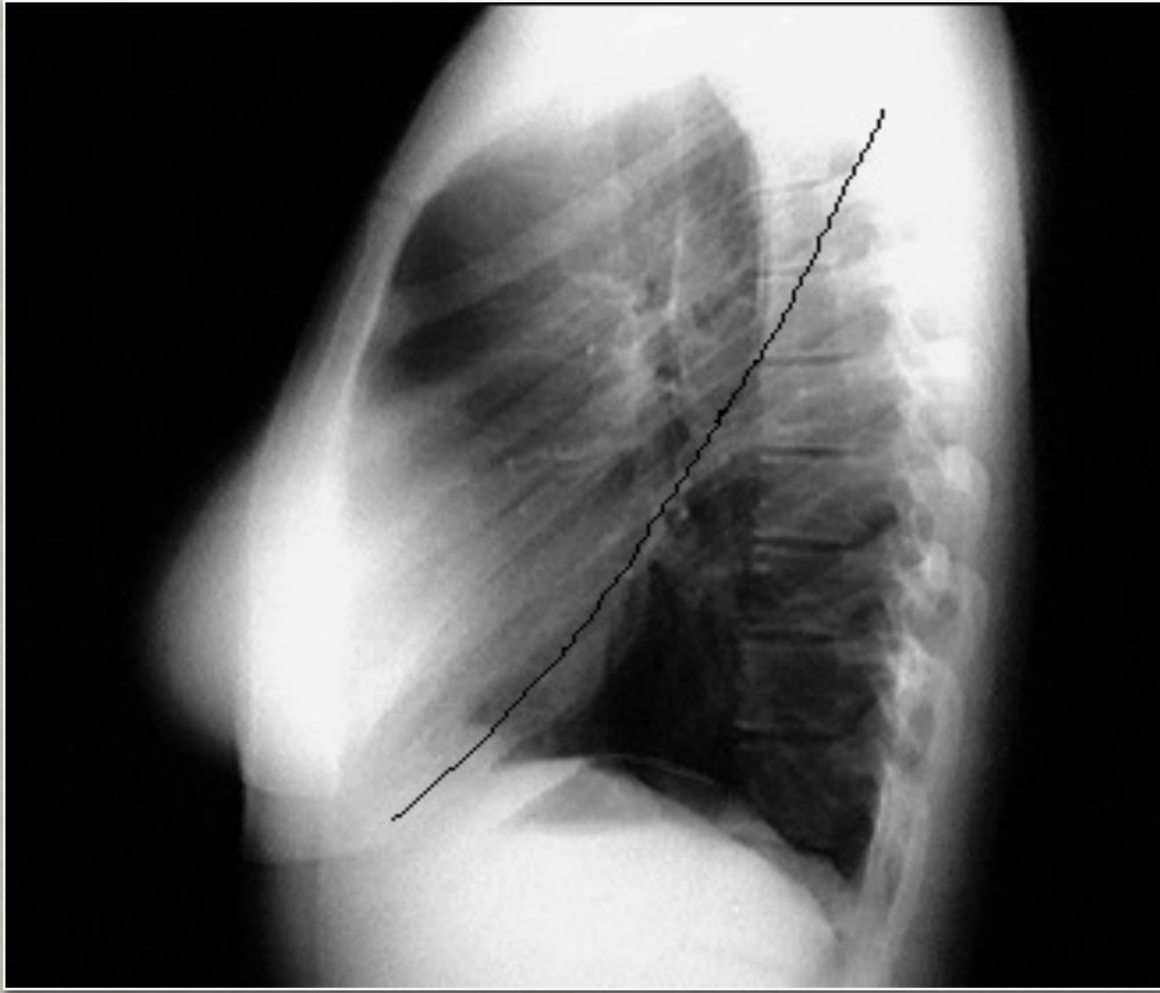

Αξονική Τομογραφία

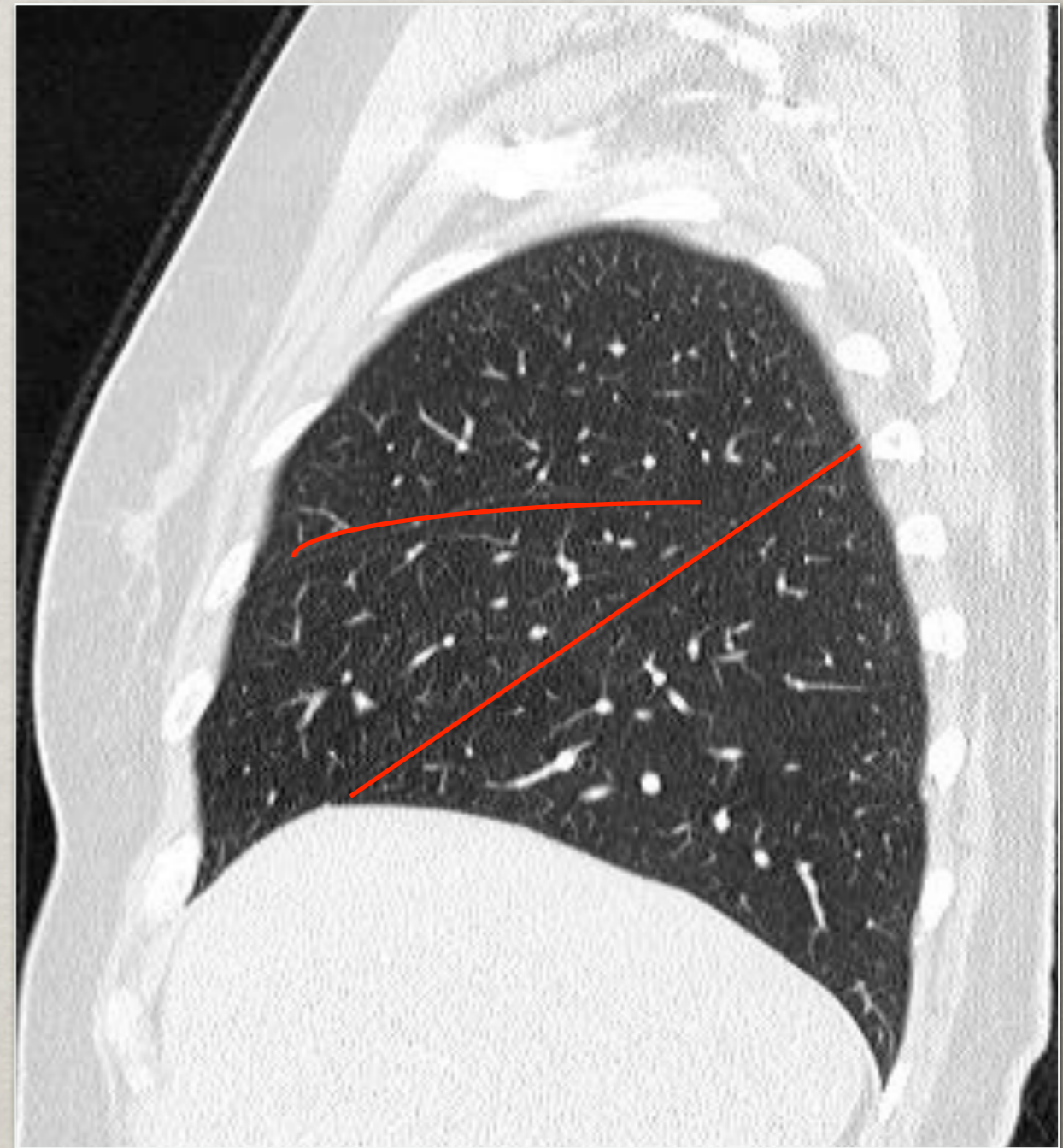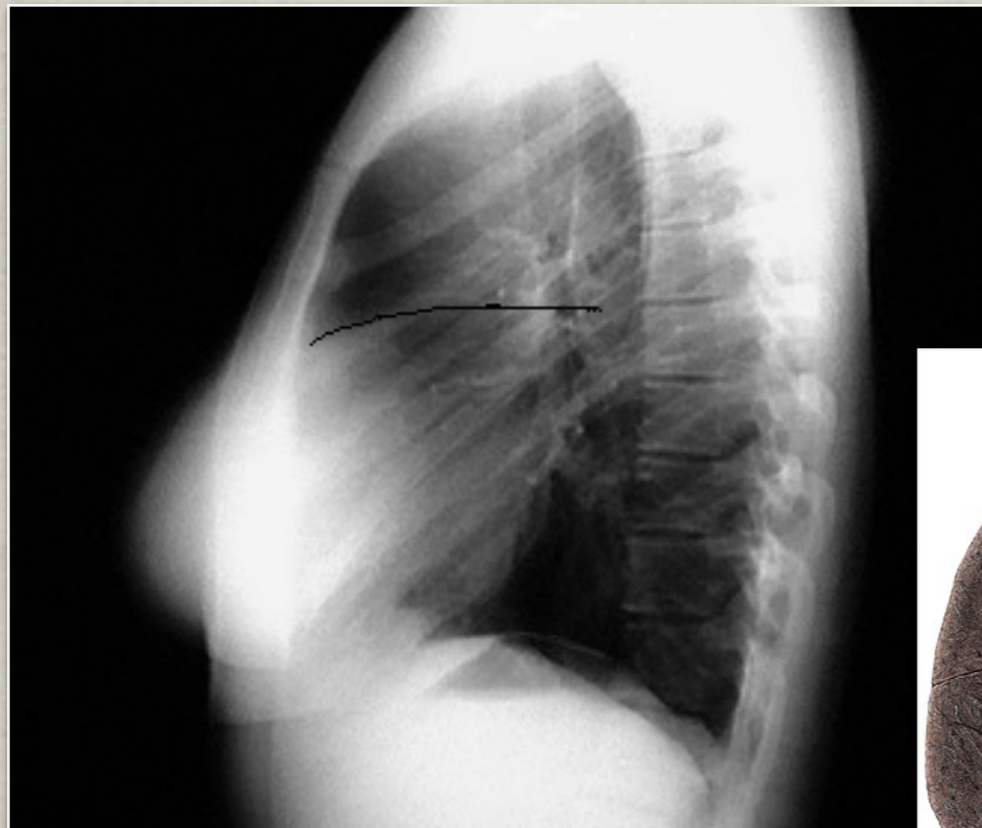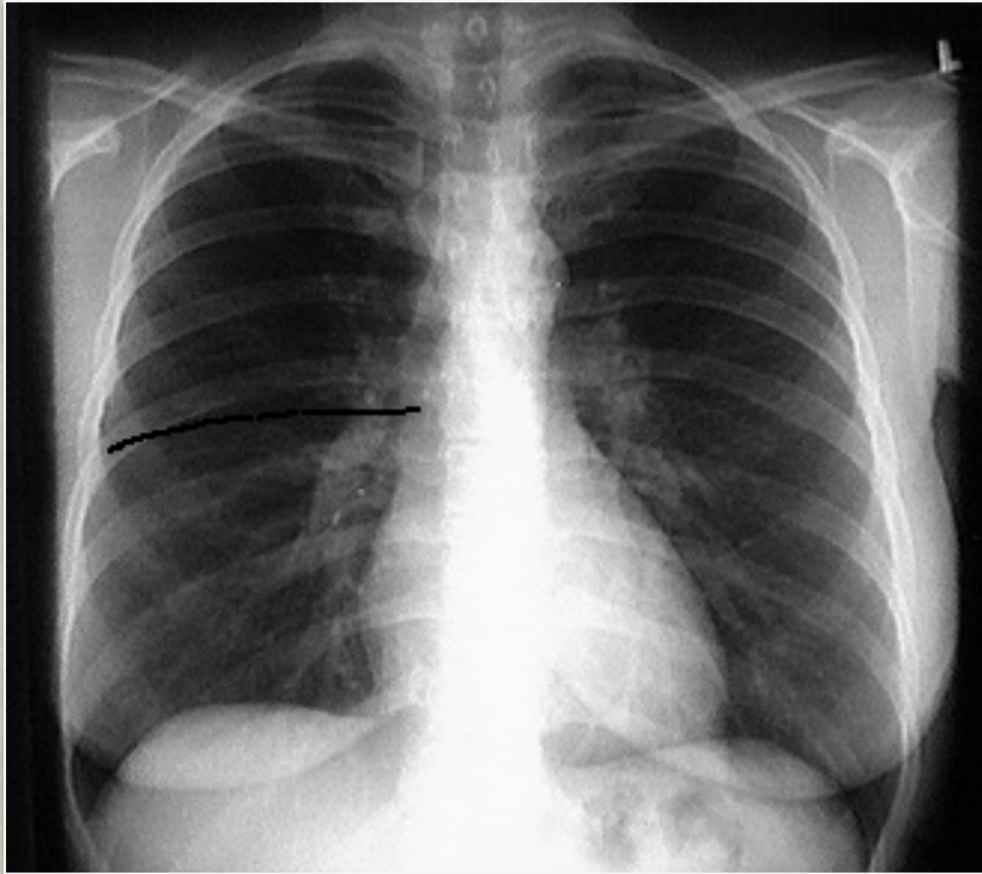


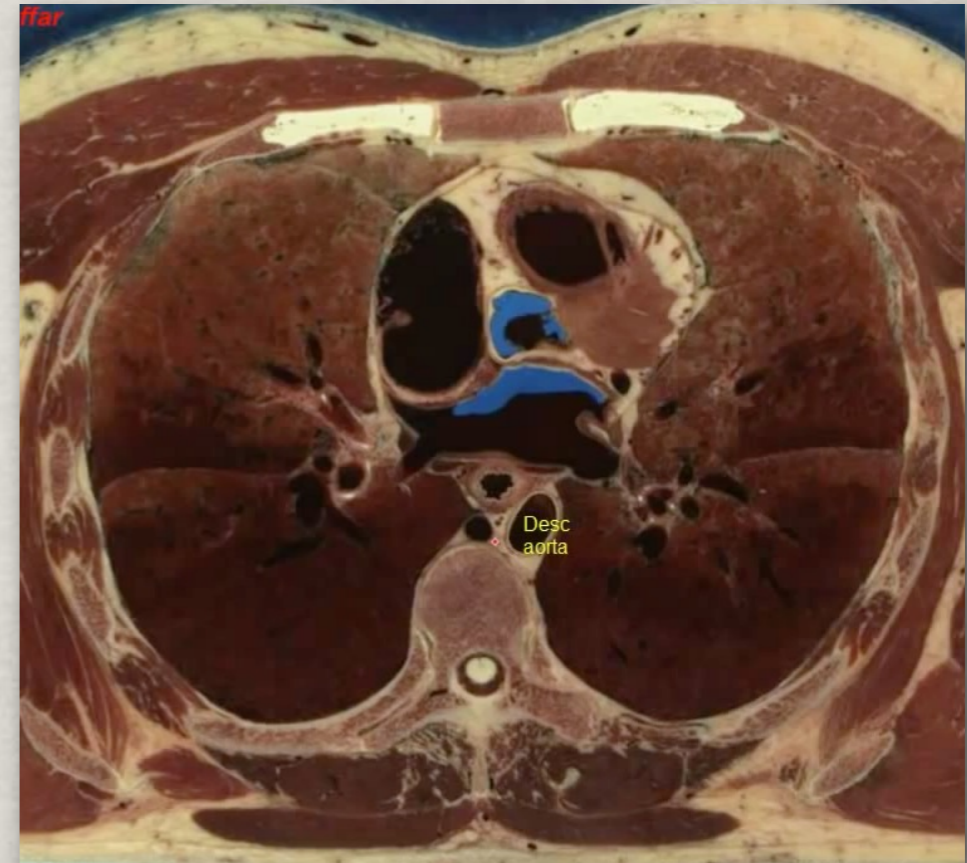
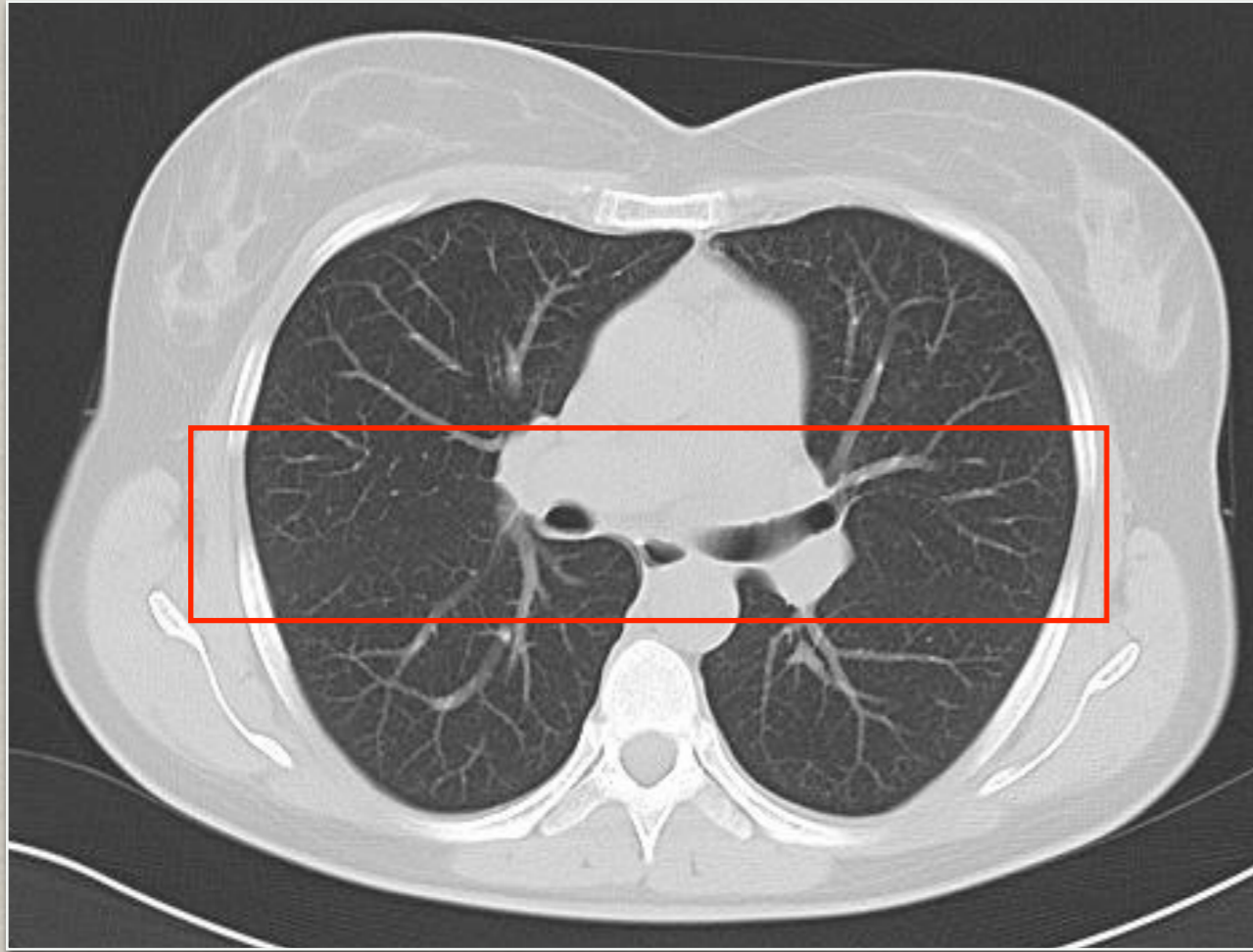


ΜΕΙΖΩΝ ΜΕΣΟΛΟΒΙΑ ΣΧΙΣΜΗ

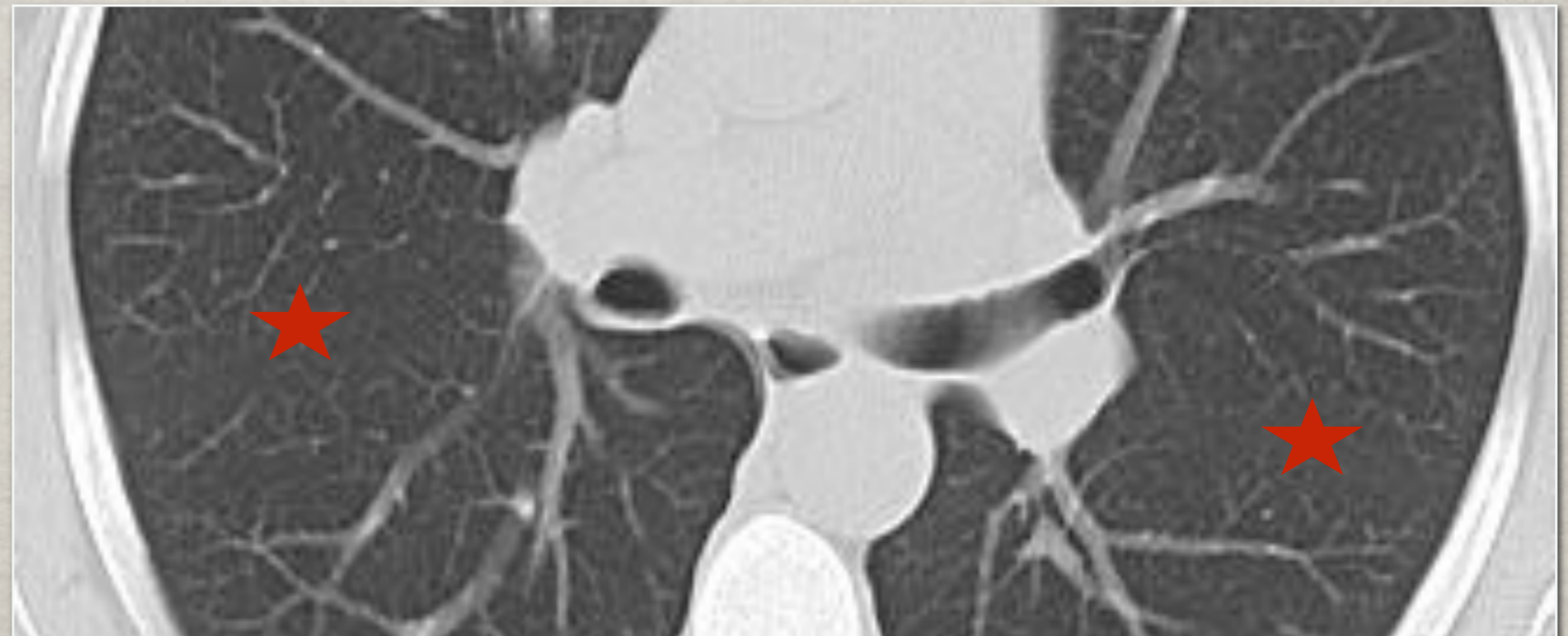

ΕΛΑΣΣΩΝ ΜΕΣΟΛΟΒΙΑ ΣΧΙΣΜΗ



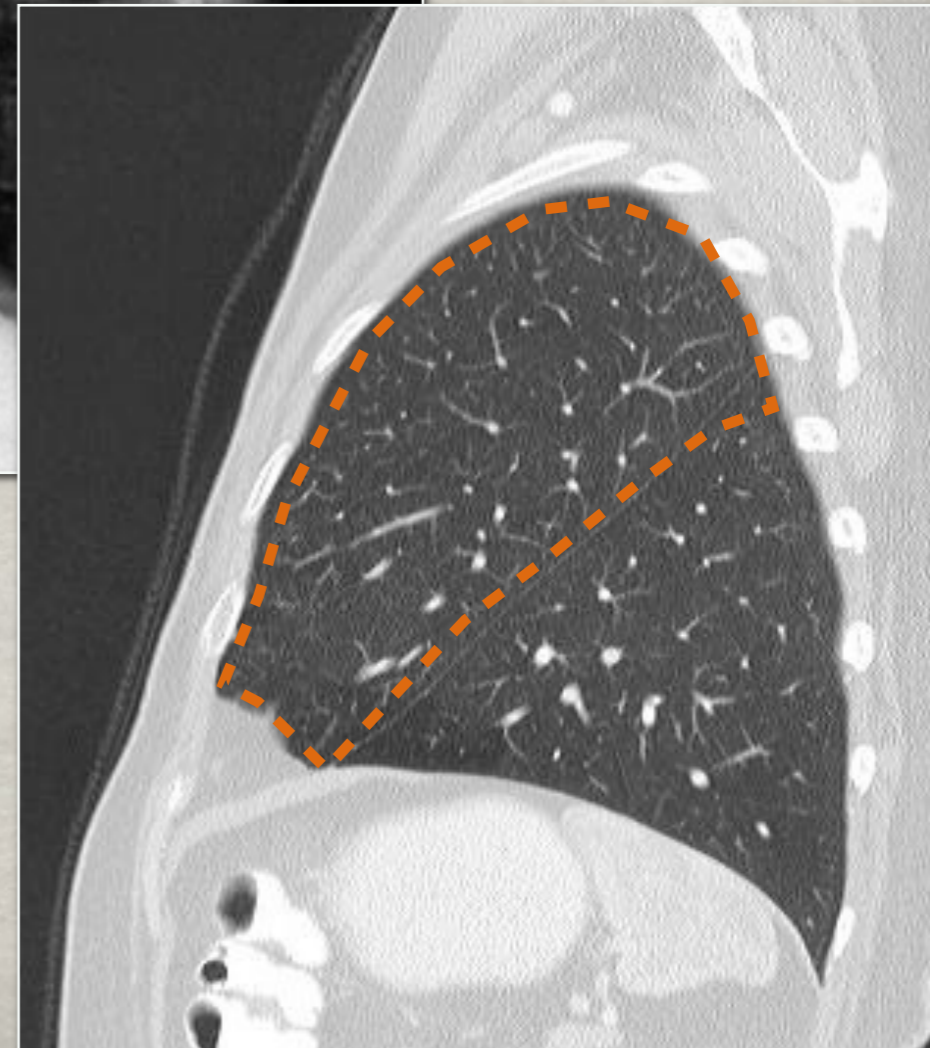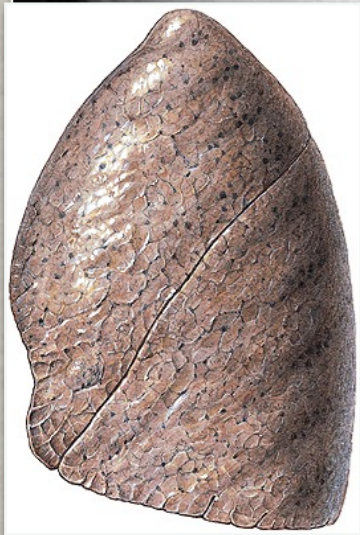
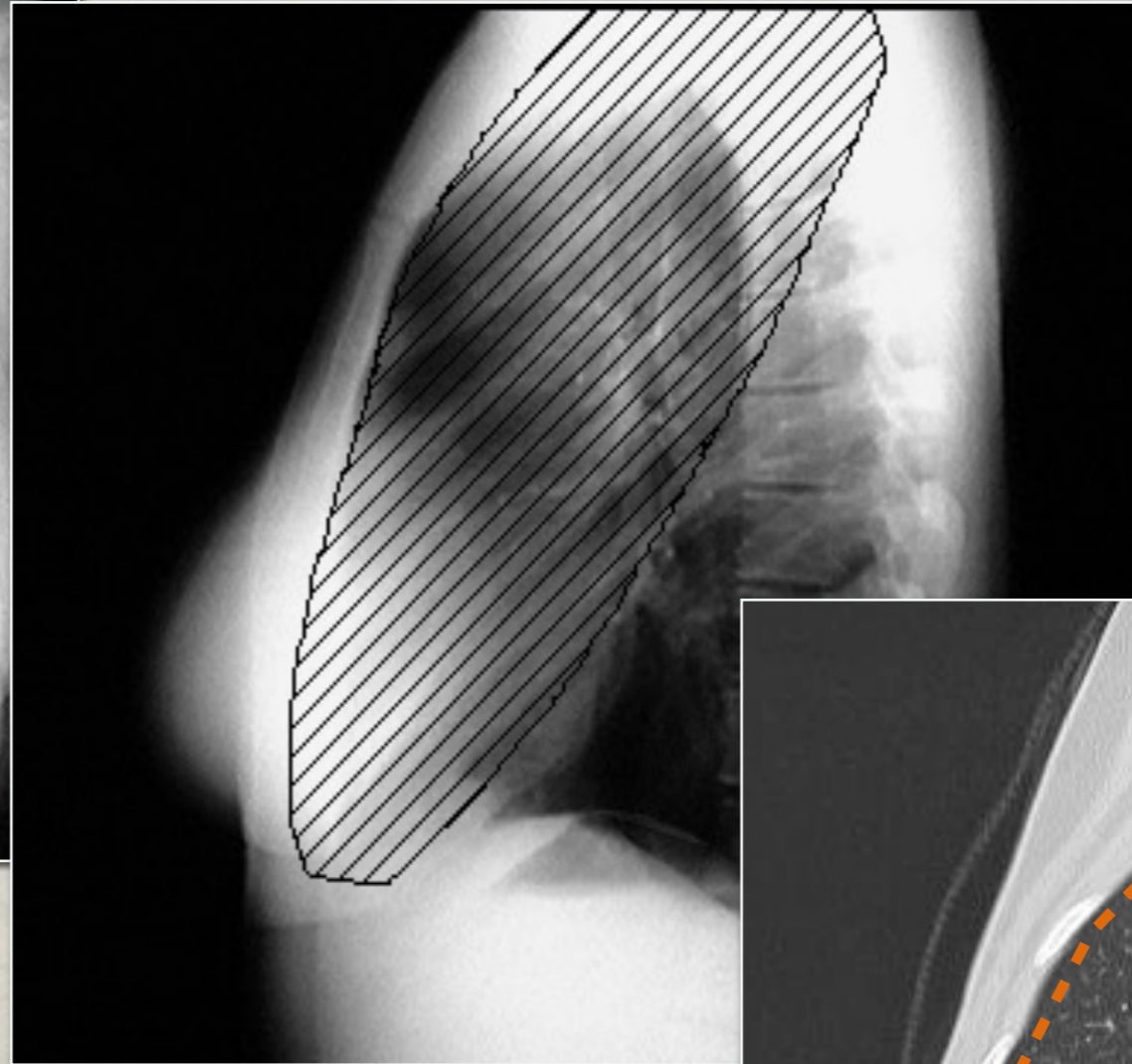
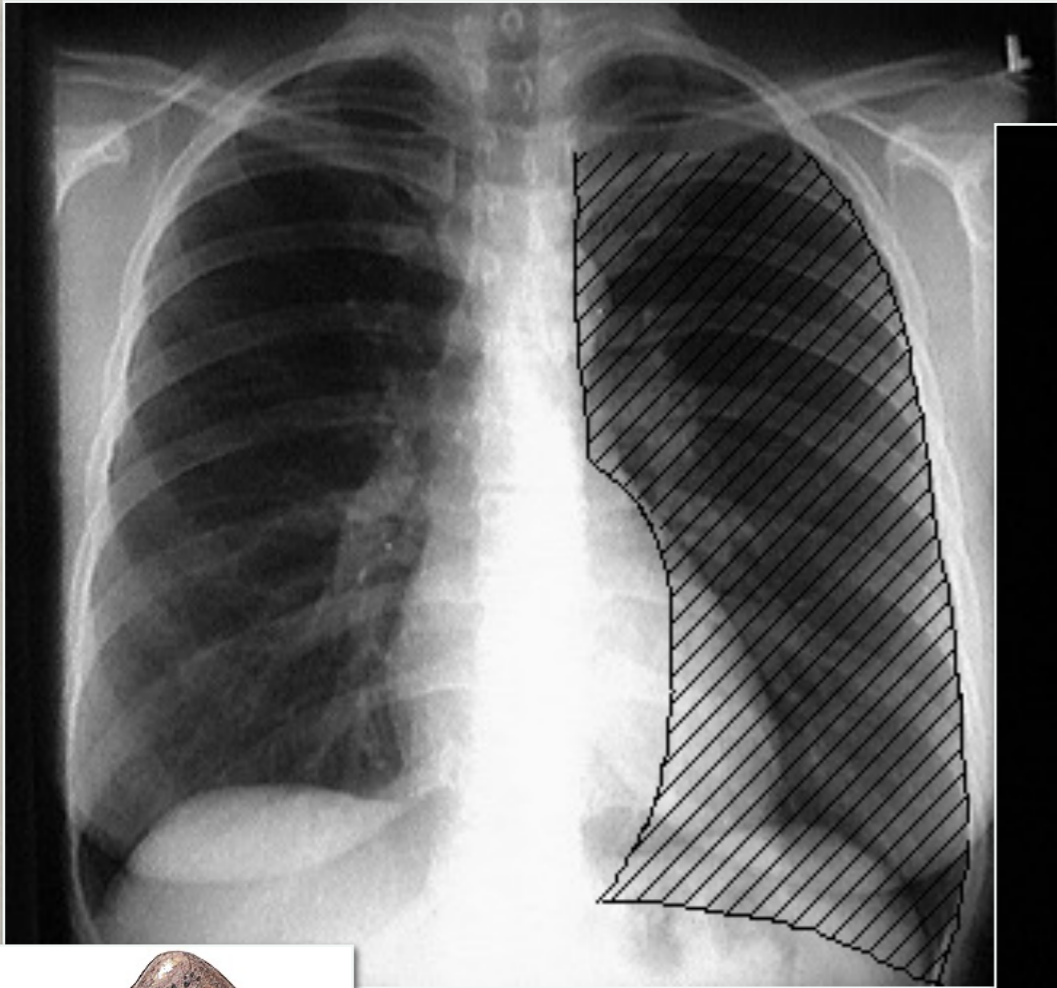


ΜΕΙΖΩΝ ΜΕΣΟΛΟΒΙΑ ΣΧΙΣΜΗ



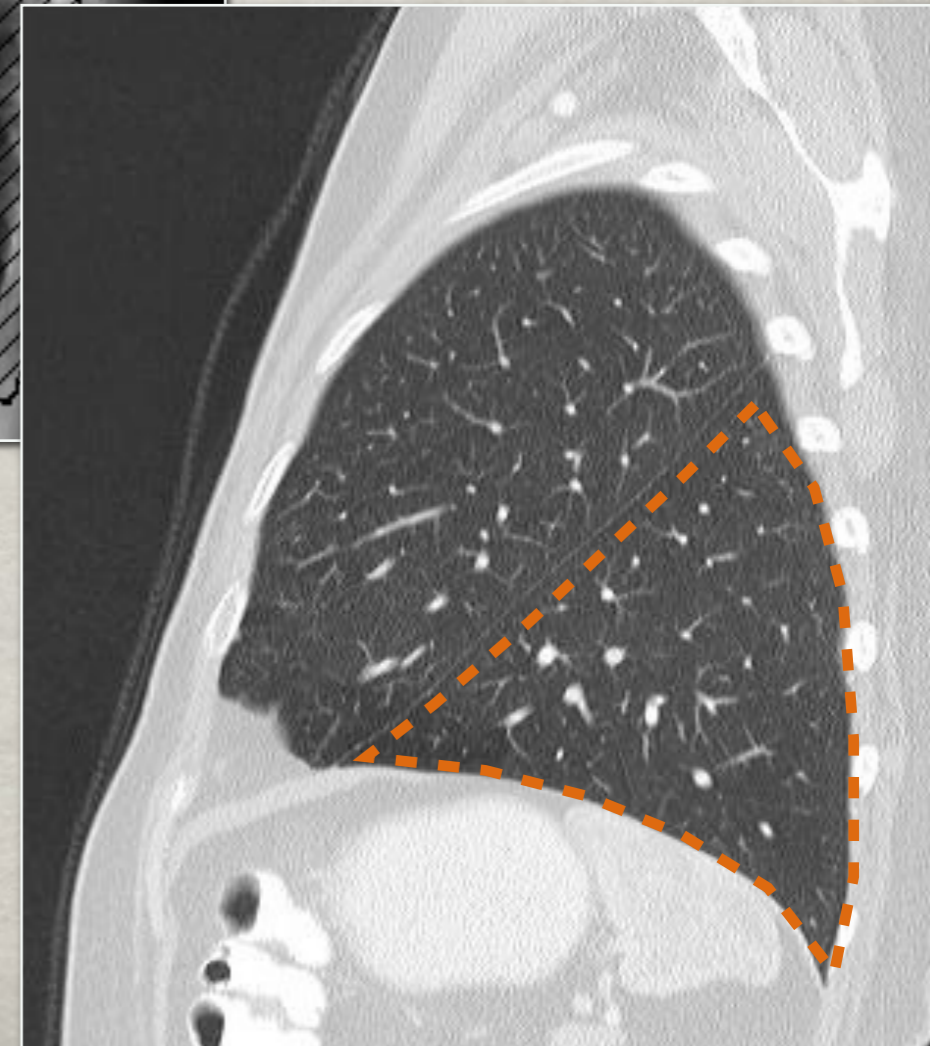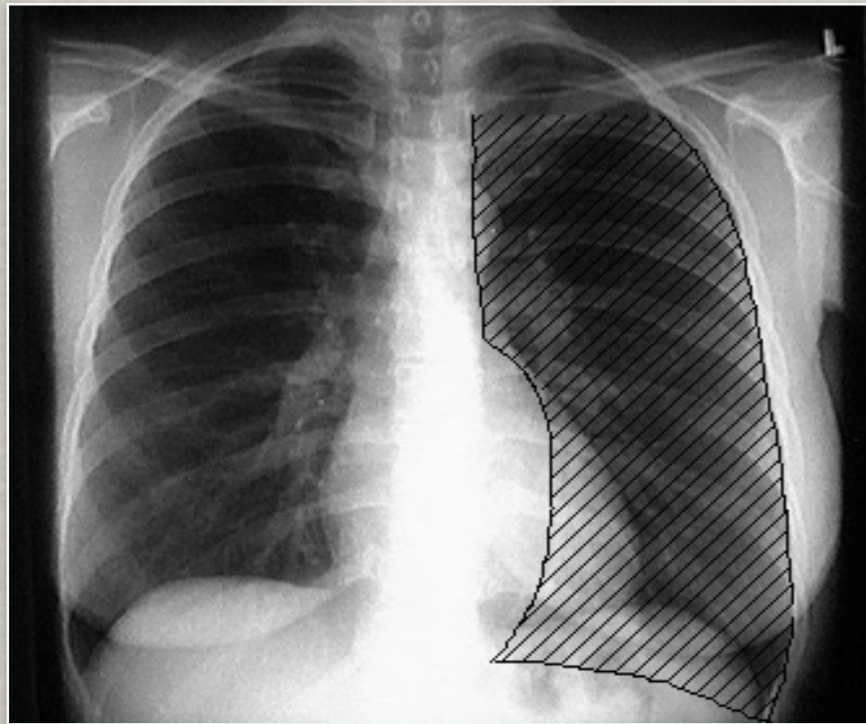
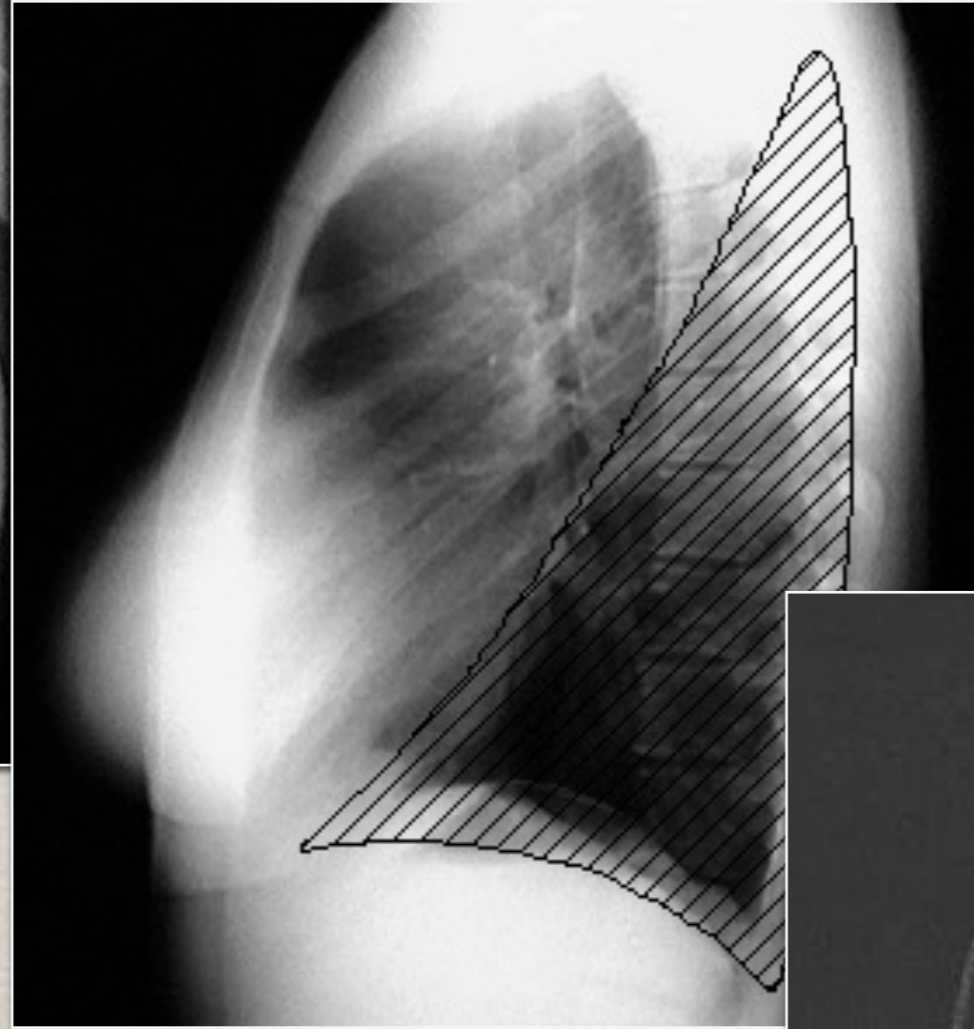
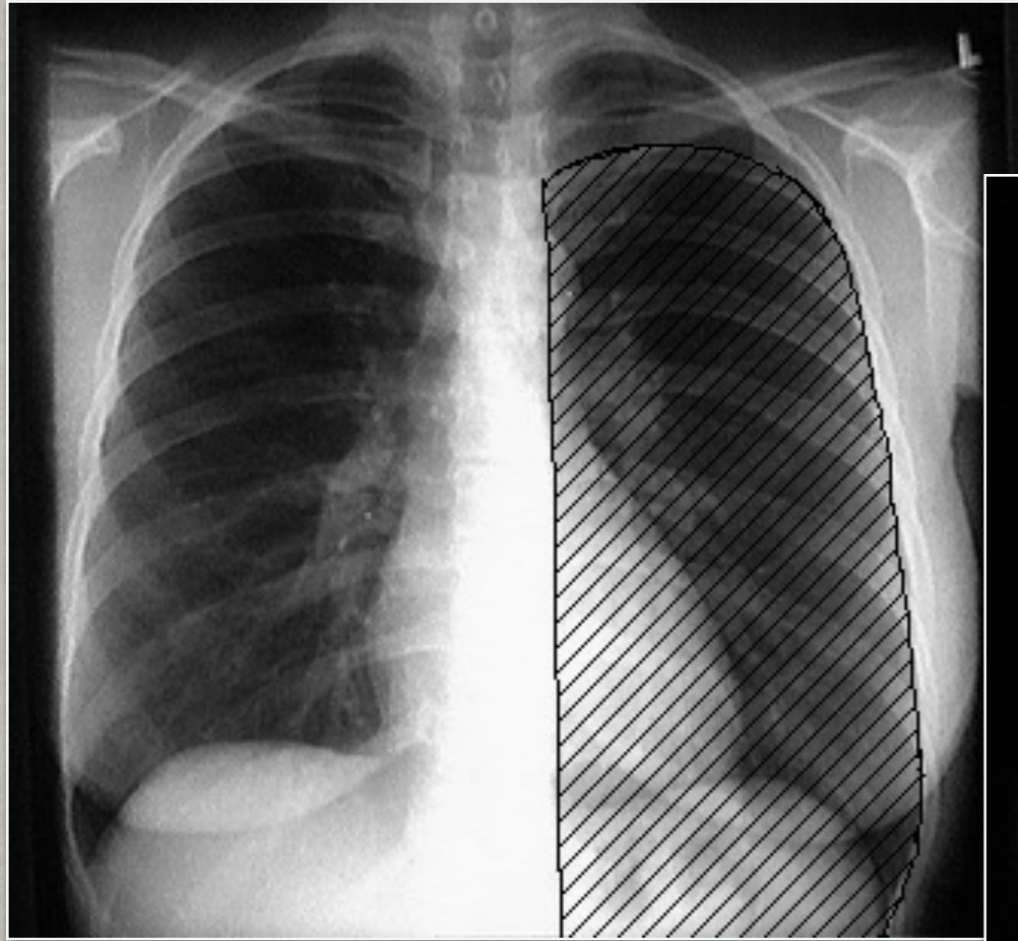
ΛΟΒΟΙ ΑΡΙΣΤΕΡΟΥ ΠΝΕΥΜΟΝΑ

Αριστερός άνω λοβός

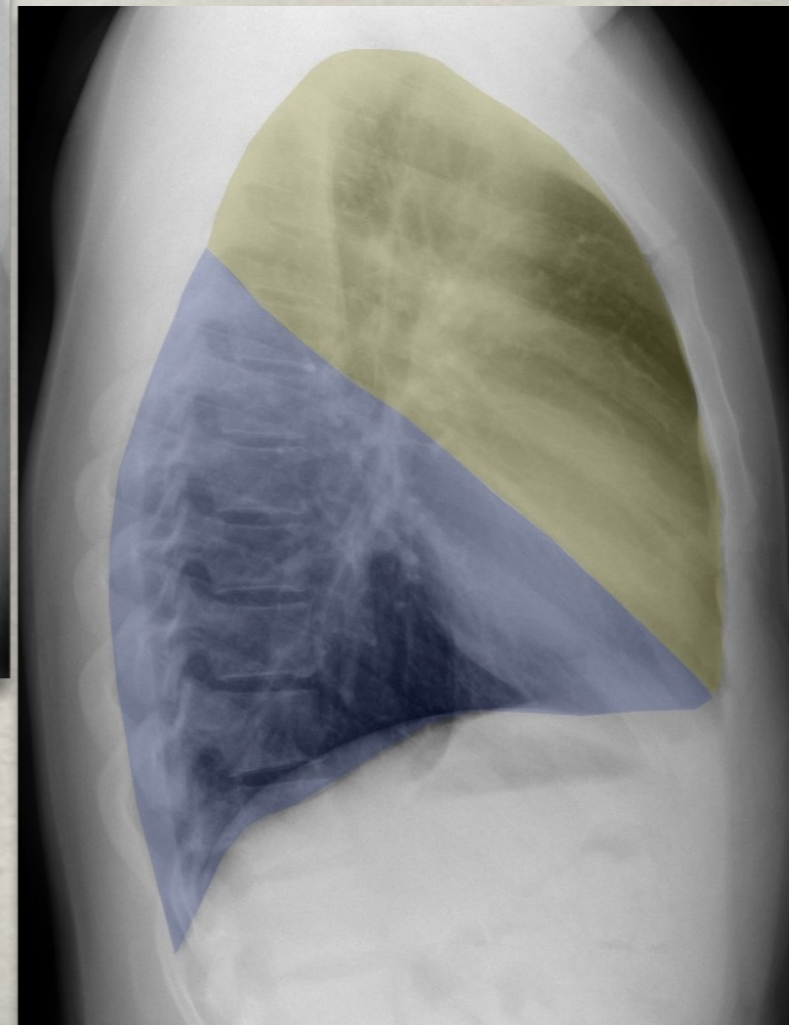
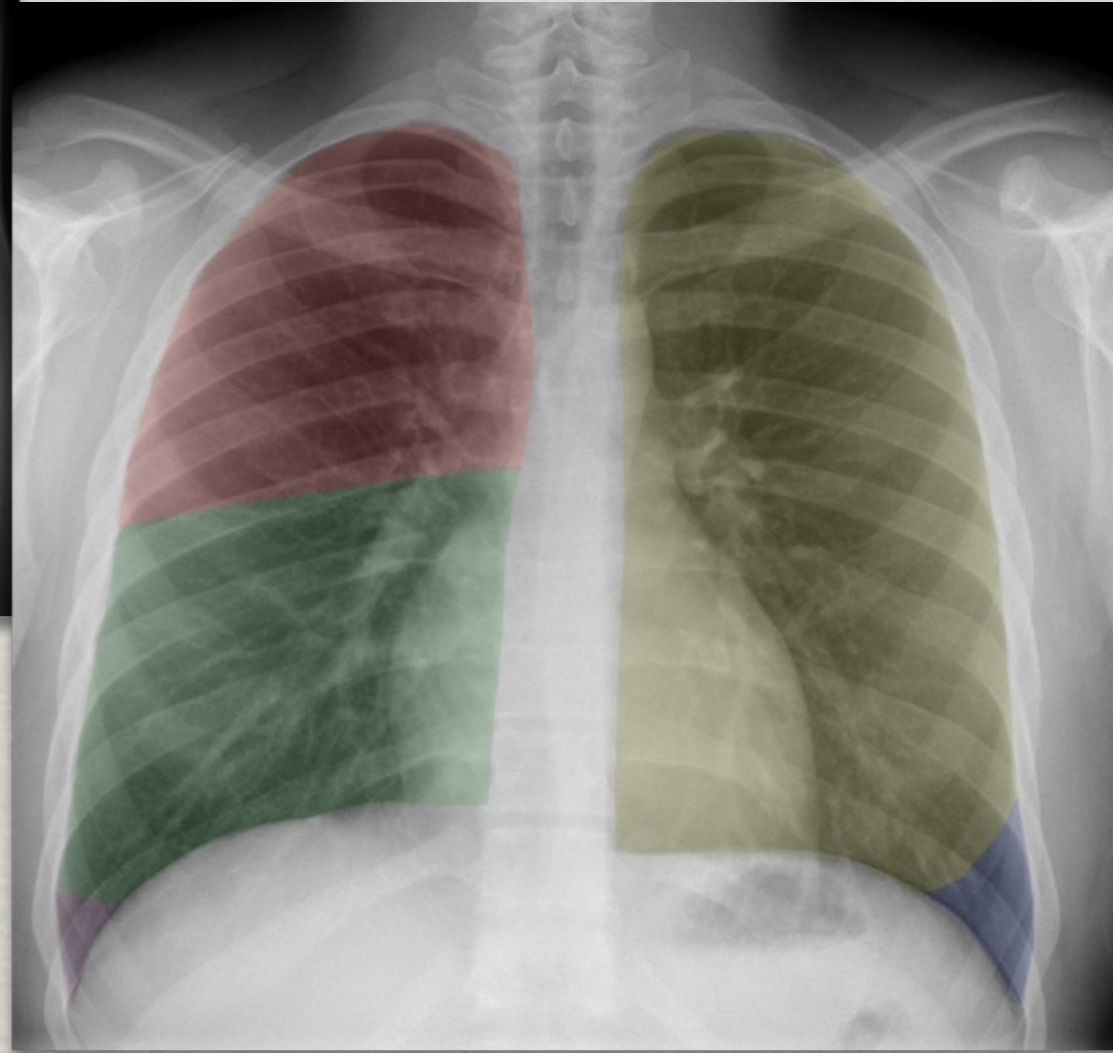
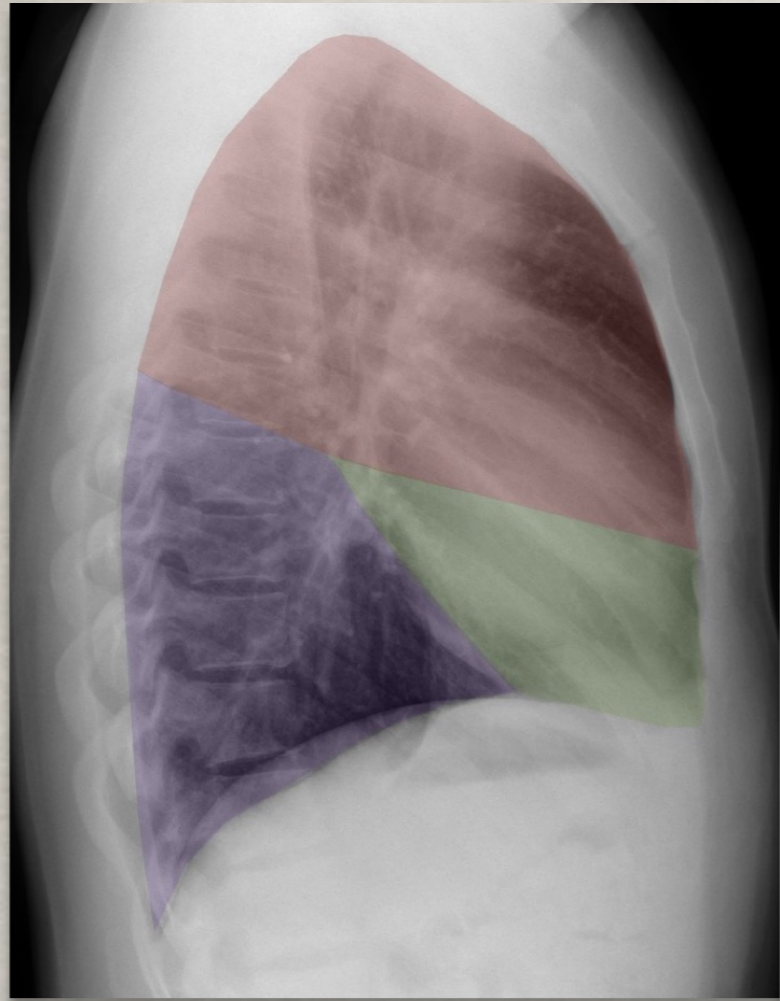


ΛΟΒΟΙ ΑΡΙΣΤΕΡΟΥ ΠΝΕΥΜΟΝΑ

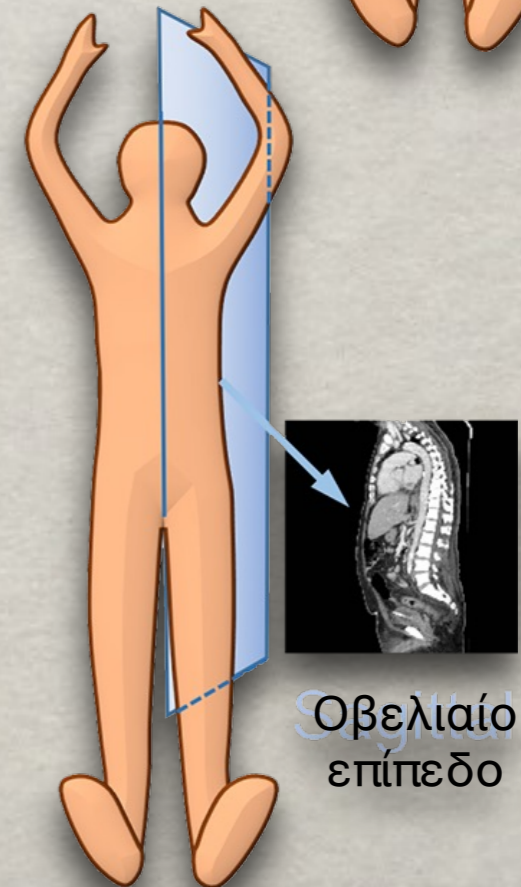
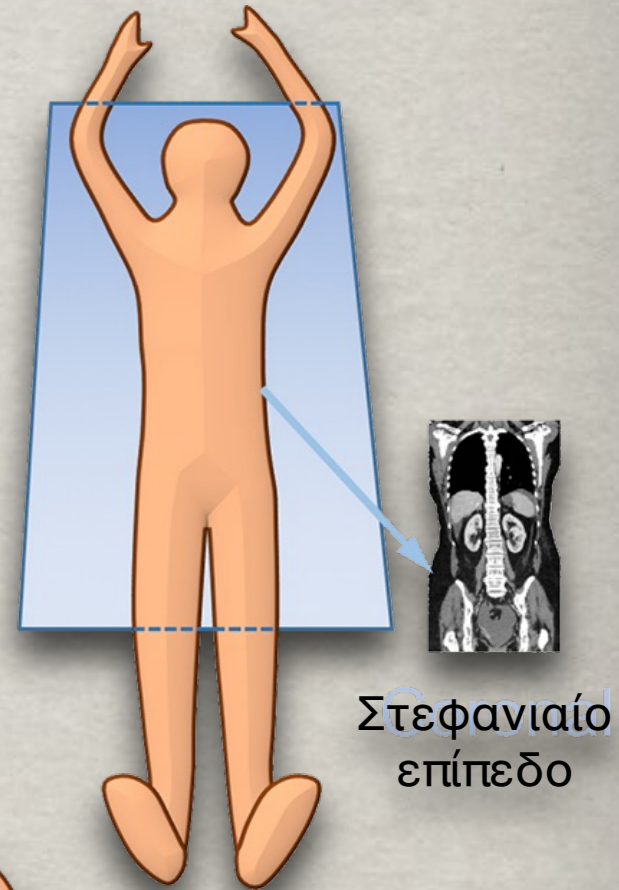
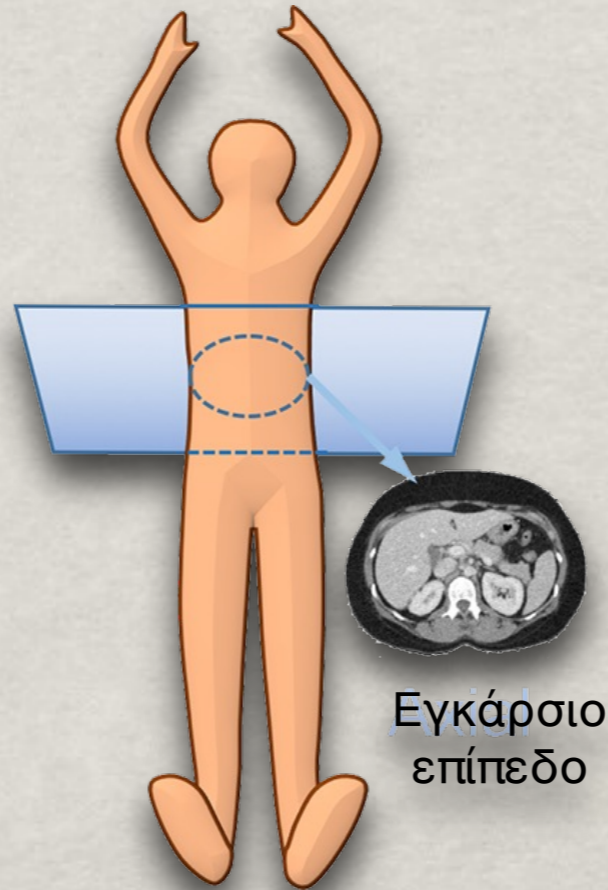
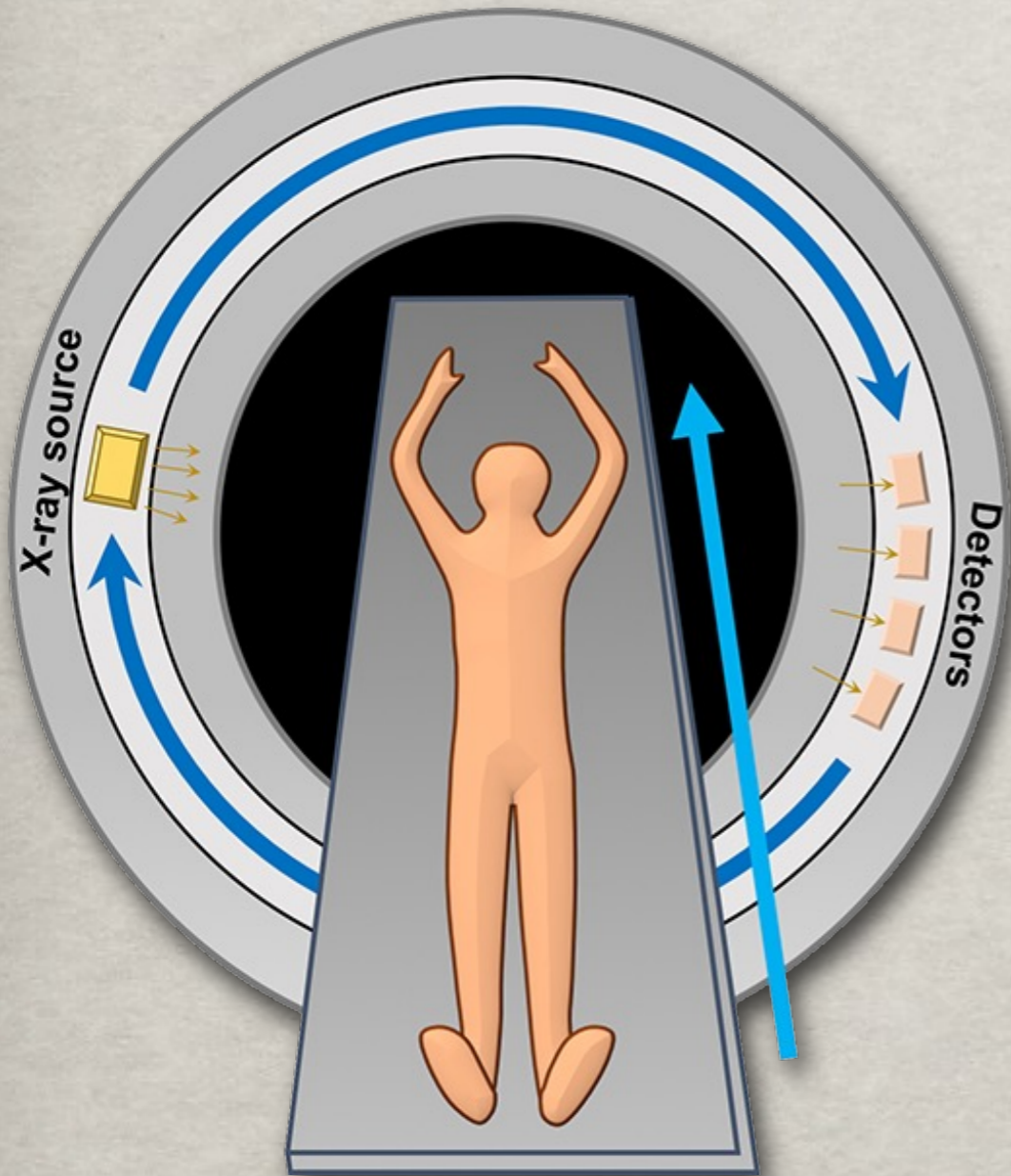
Αριστερός κάτω λοβός



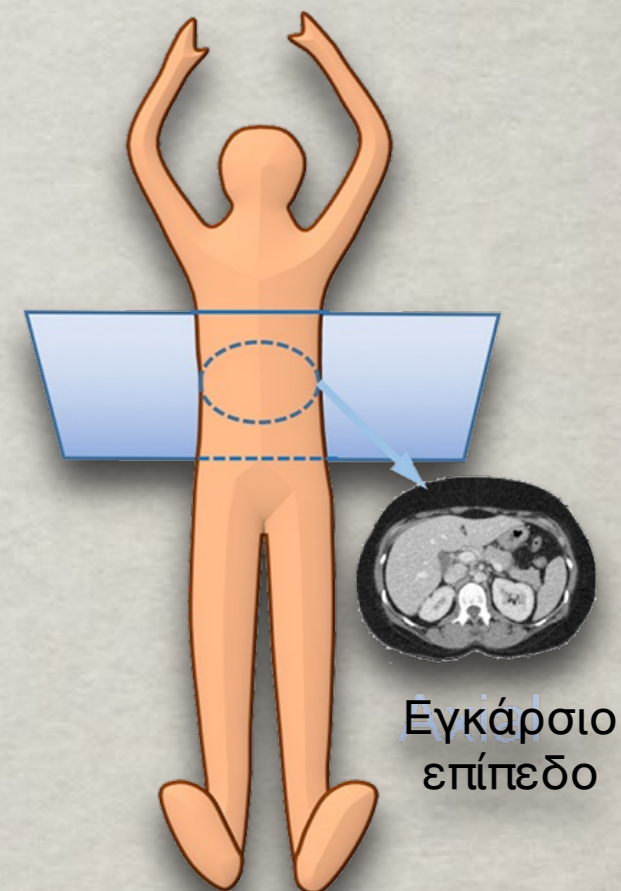
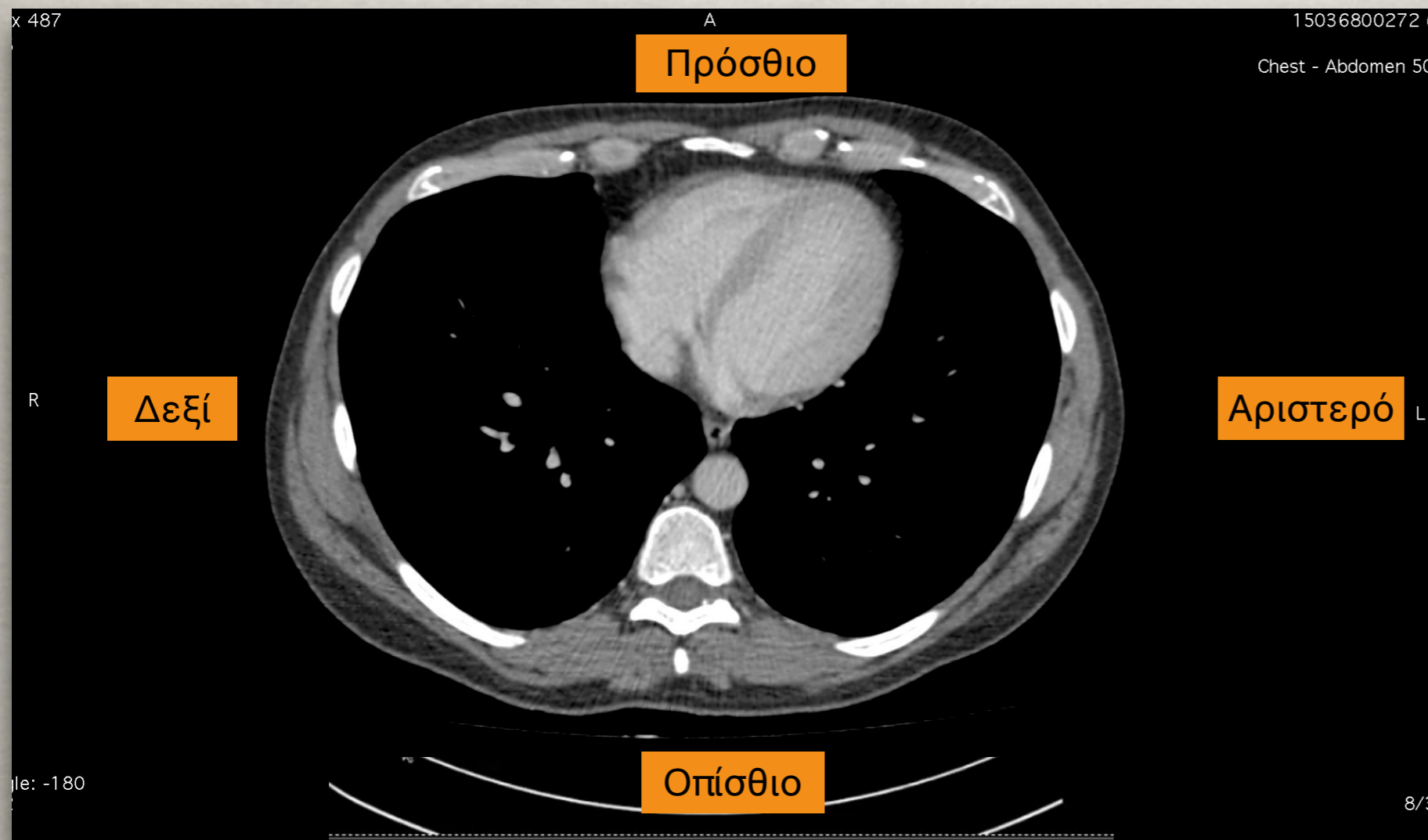
ΘΩΡΑΚΑΣ



Αξονική Τομογραφία

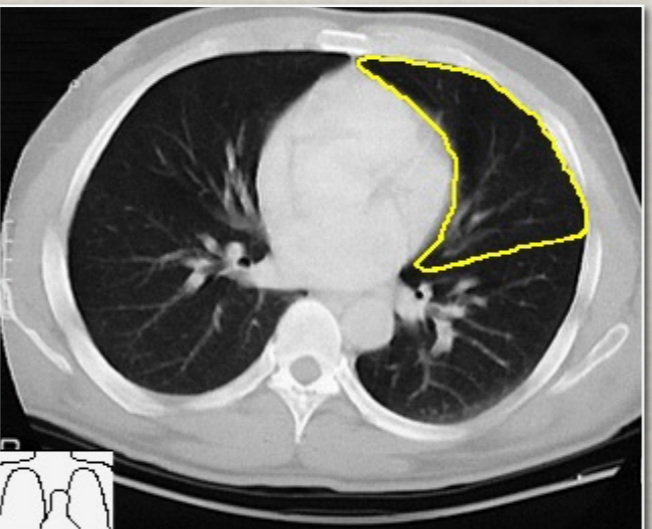
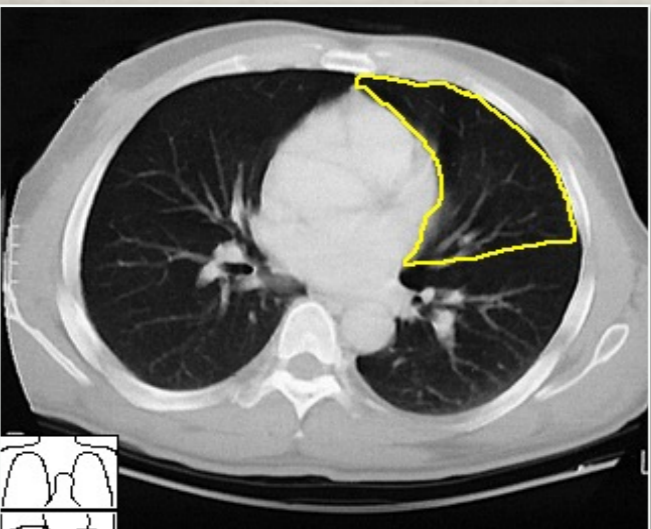
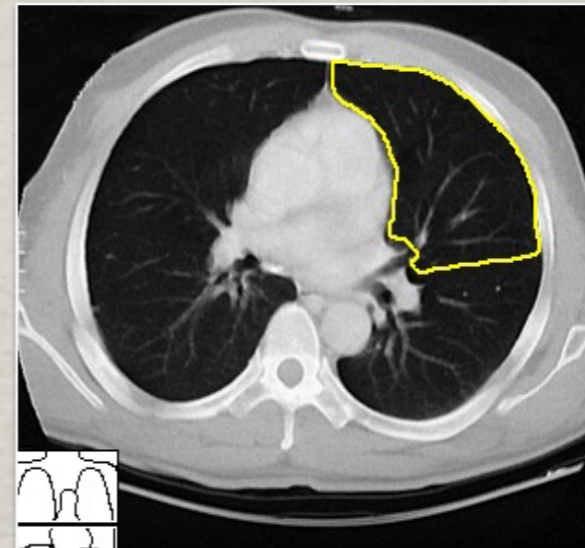
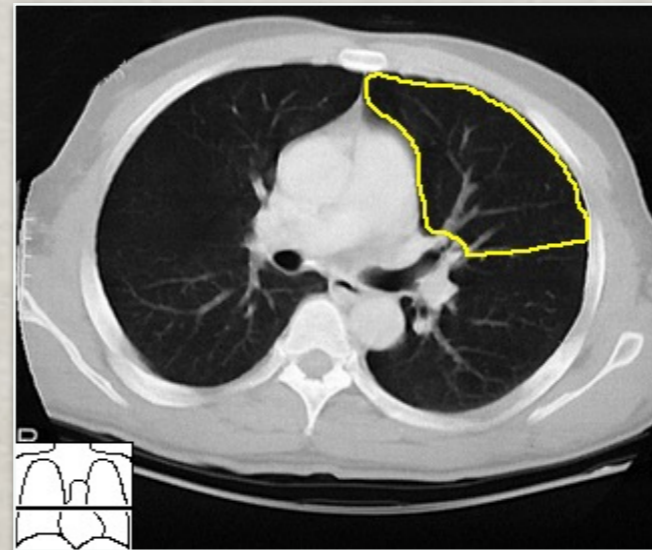
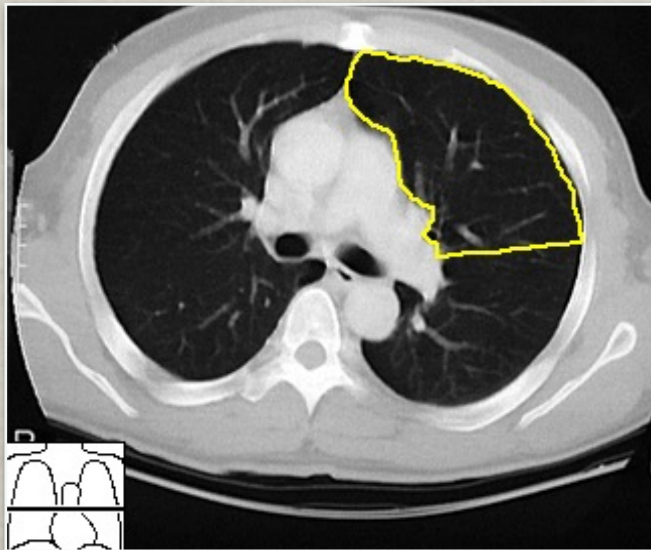
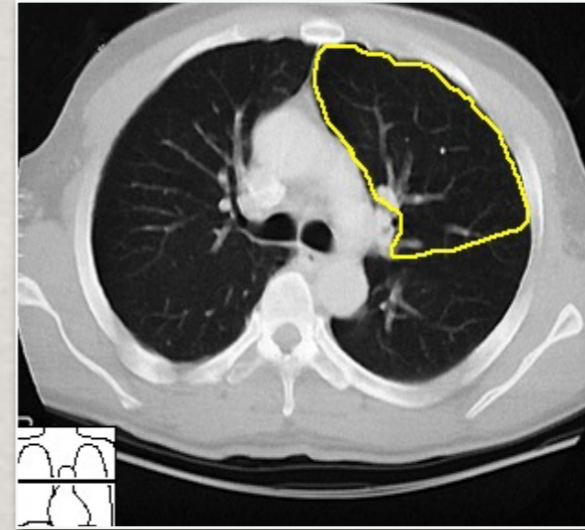
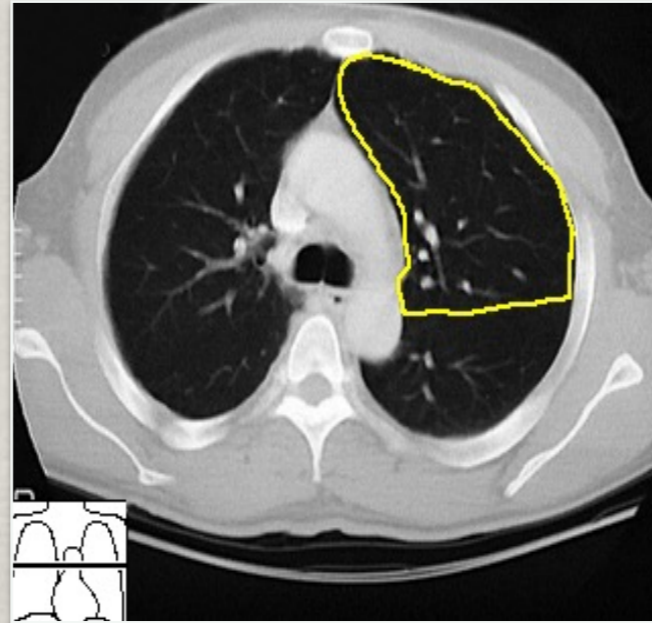
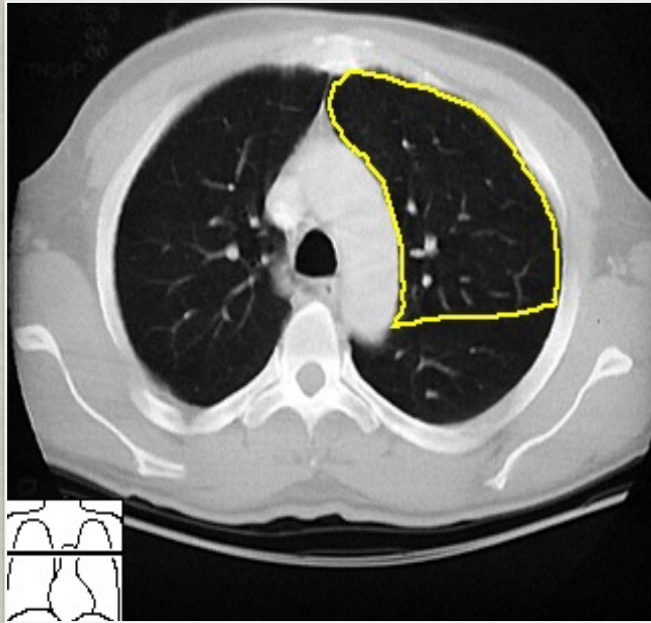


Αξονική Τομογραφία

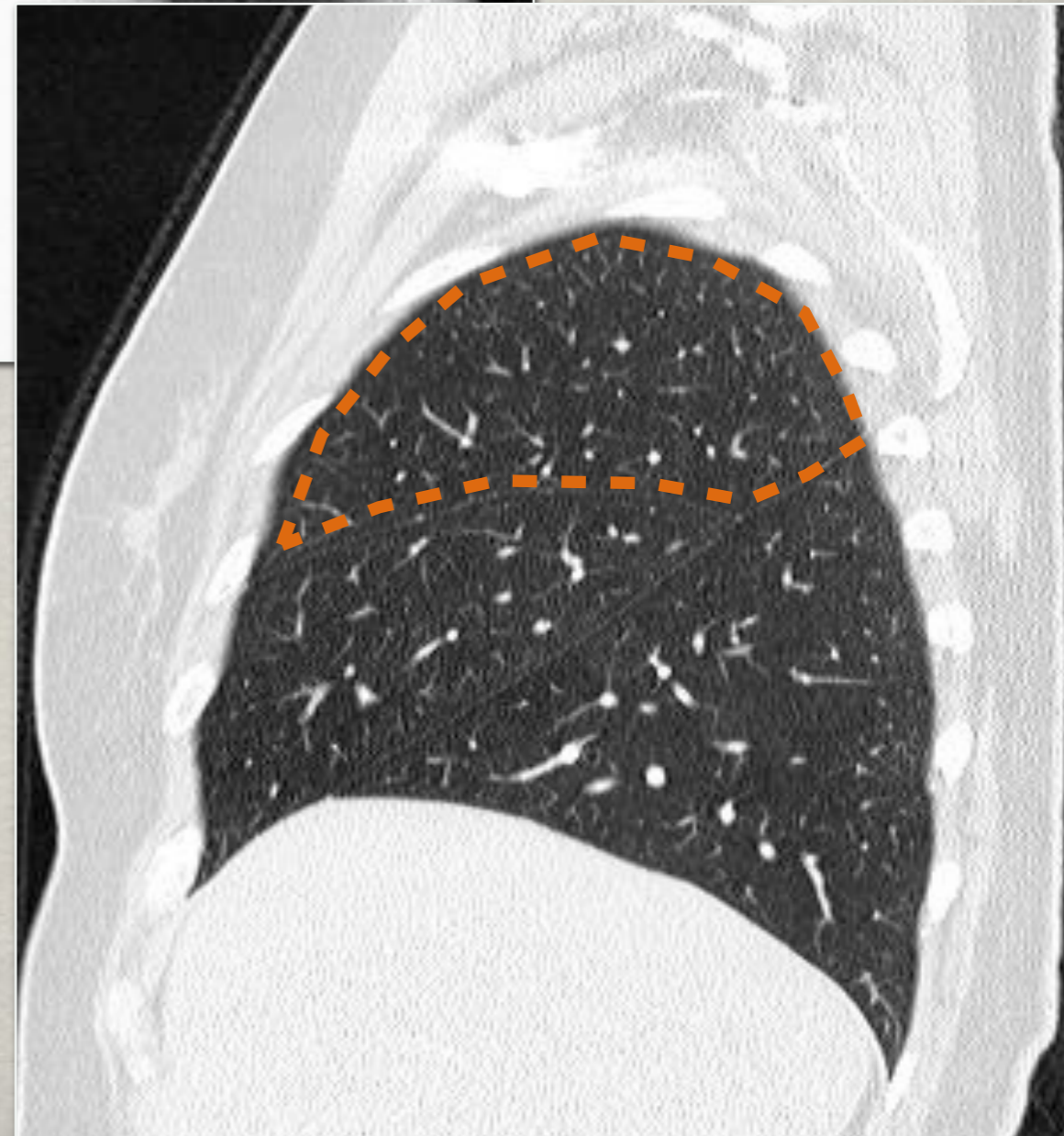
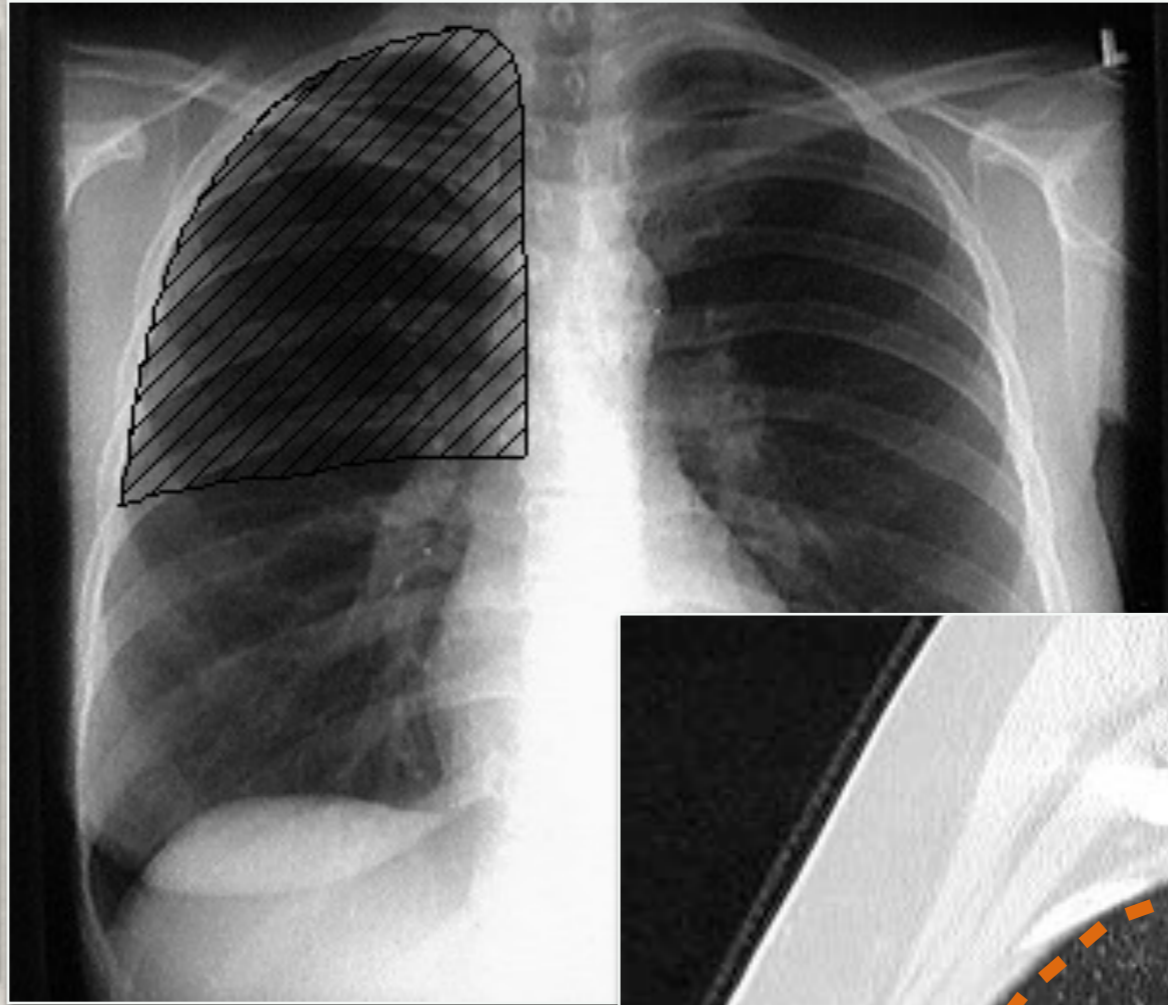
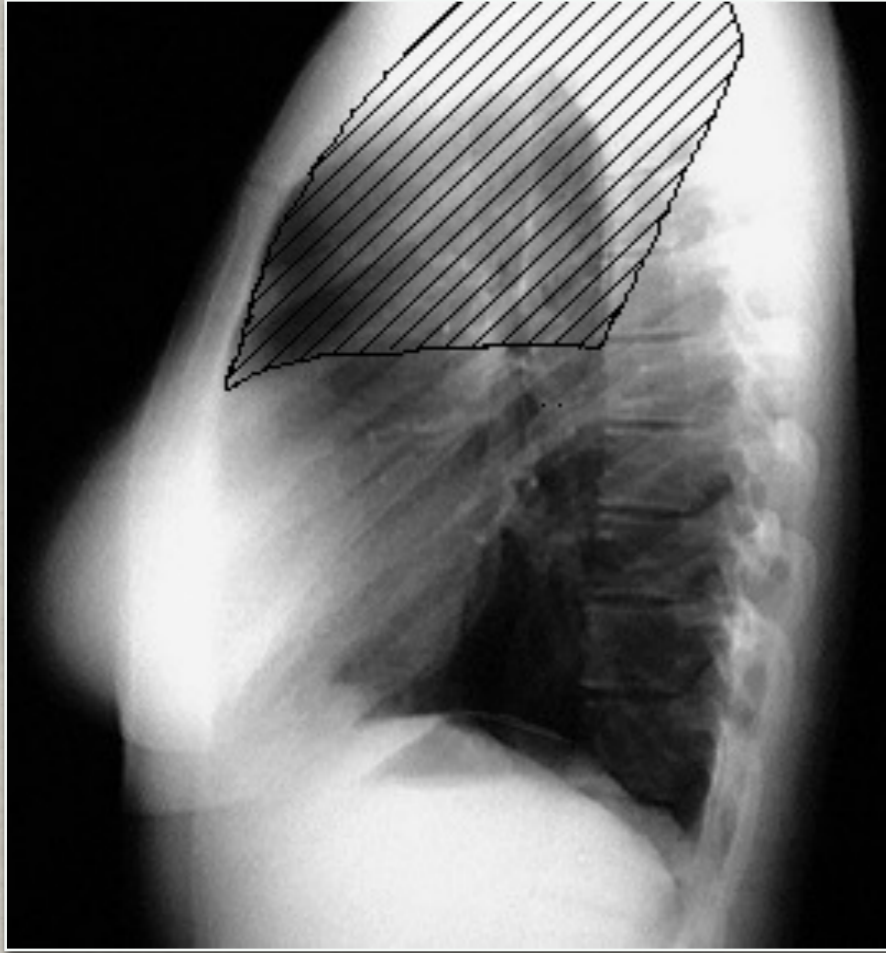


ΛΟΒΟΙ ΑΡΙΣΤΕΡΟΥ ΠΝΕΥΜΟΝΑ

Αριστερός άνω λοβός



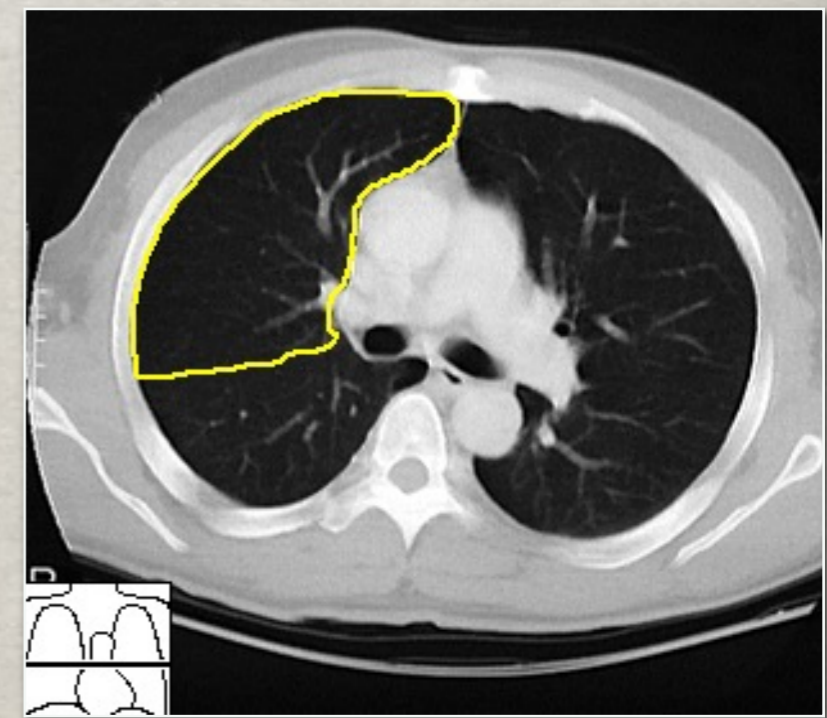
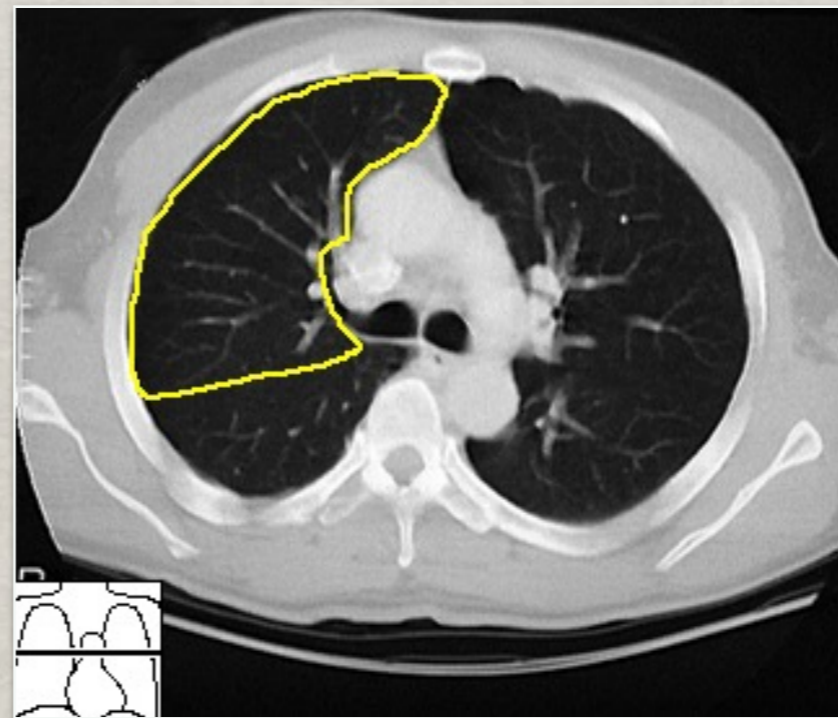
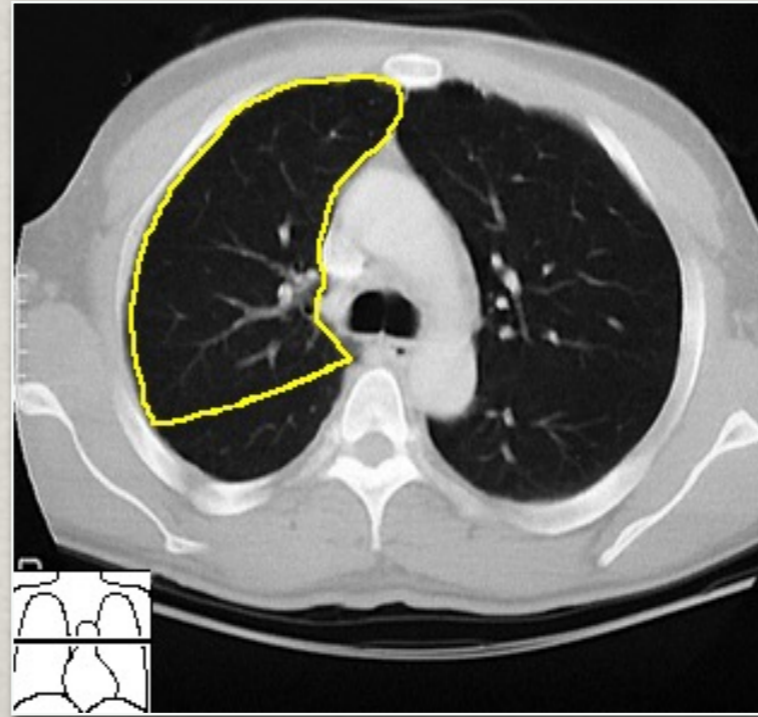
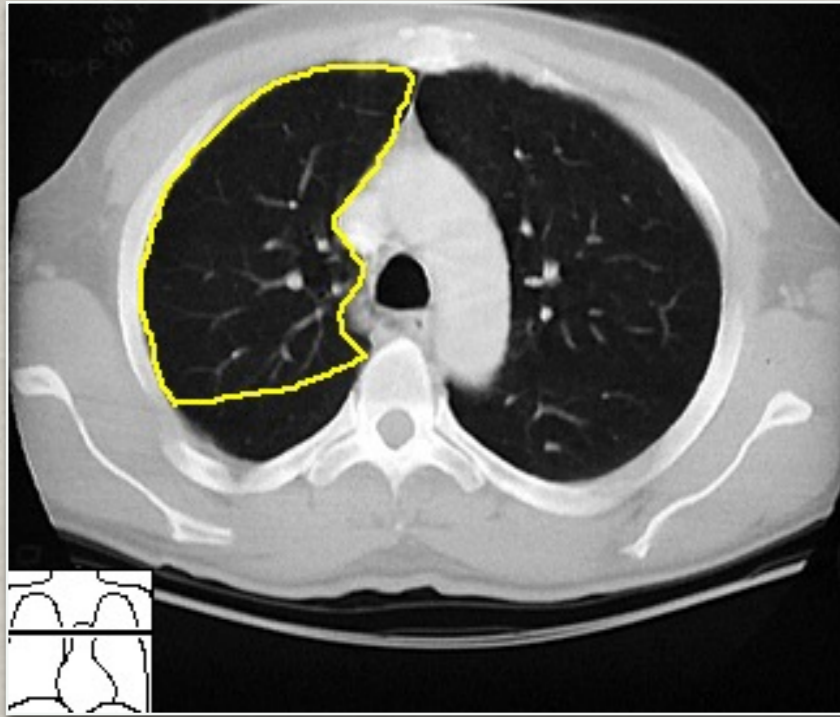
Όρια: πρόσθιο θωρακικό τοίχωμα
– μείζων μεσολόβια σχισμή



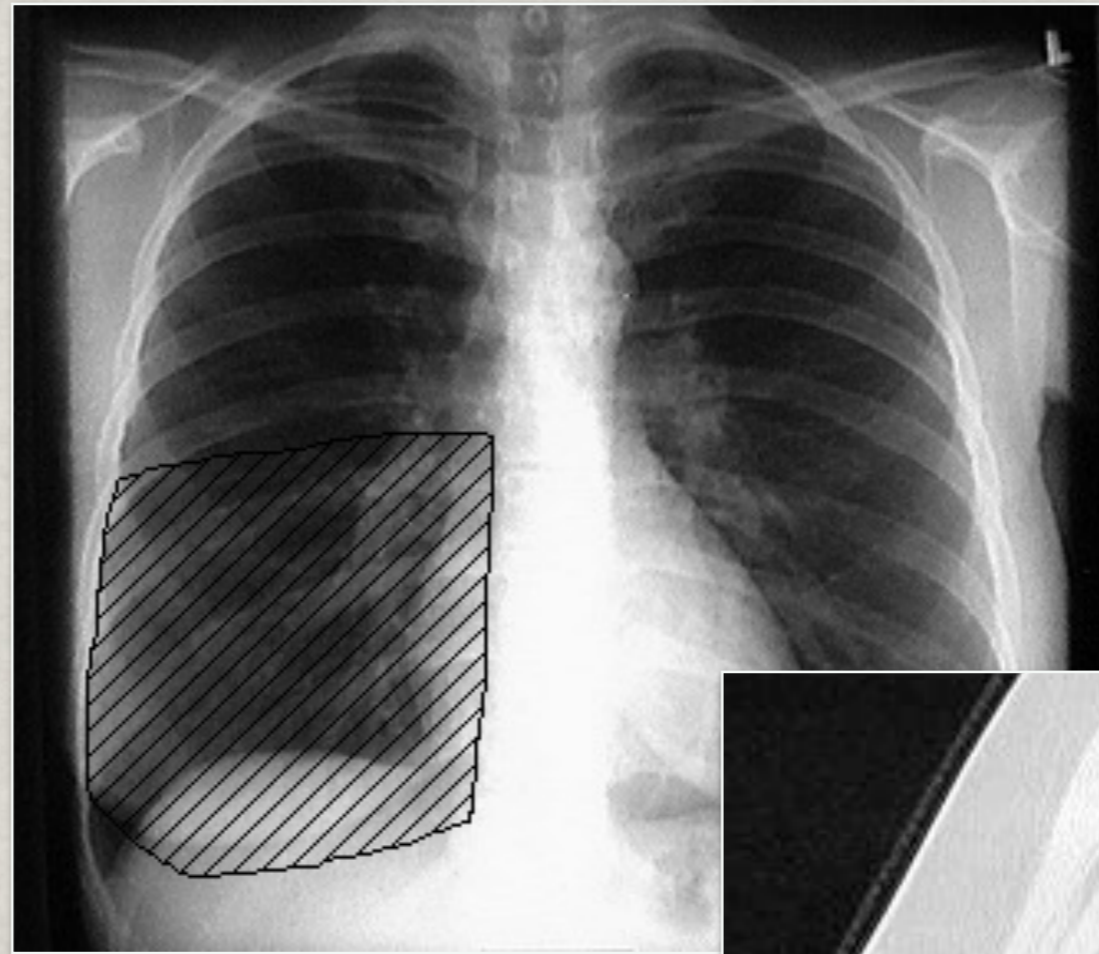
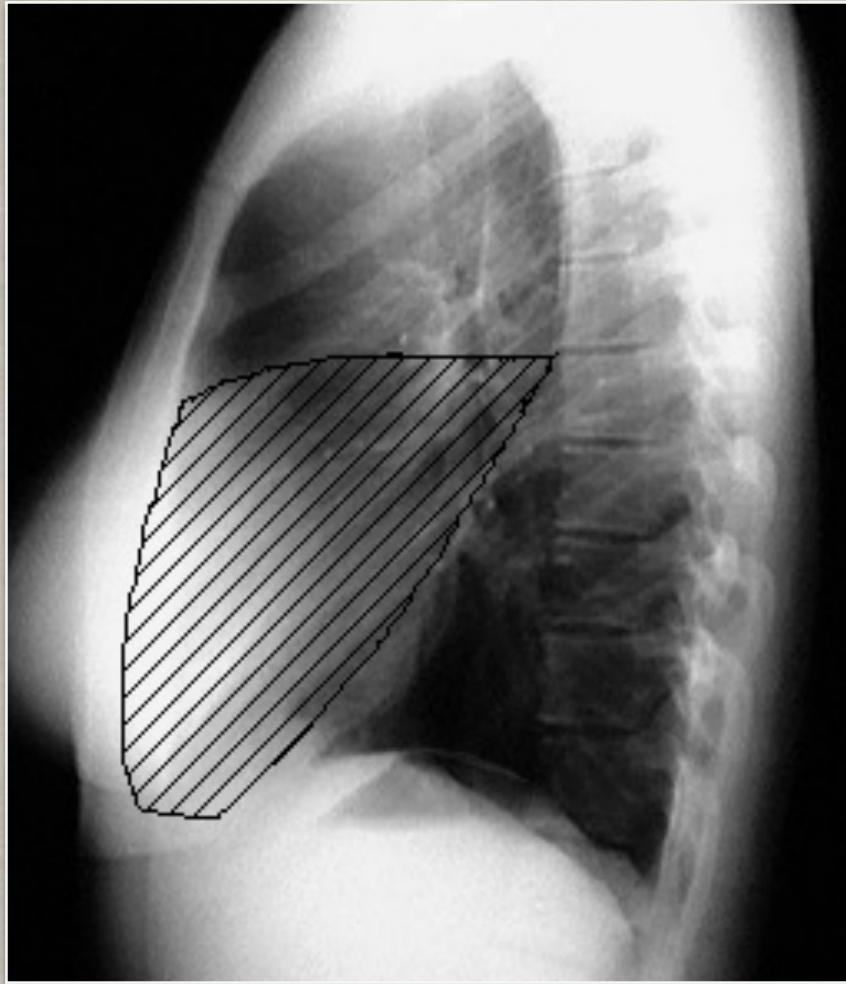
ΛΟΒΟΙ ΔΕΞΙΟΥ ΠΝΕΥΜΟΝΑ
Δεξιός άνω λοβός

ΛΟΒΟΙ ΔΕΞΙΟΥ ΠΝΕΥΜΟΝΑ

Δεξιός άνω λοβός

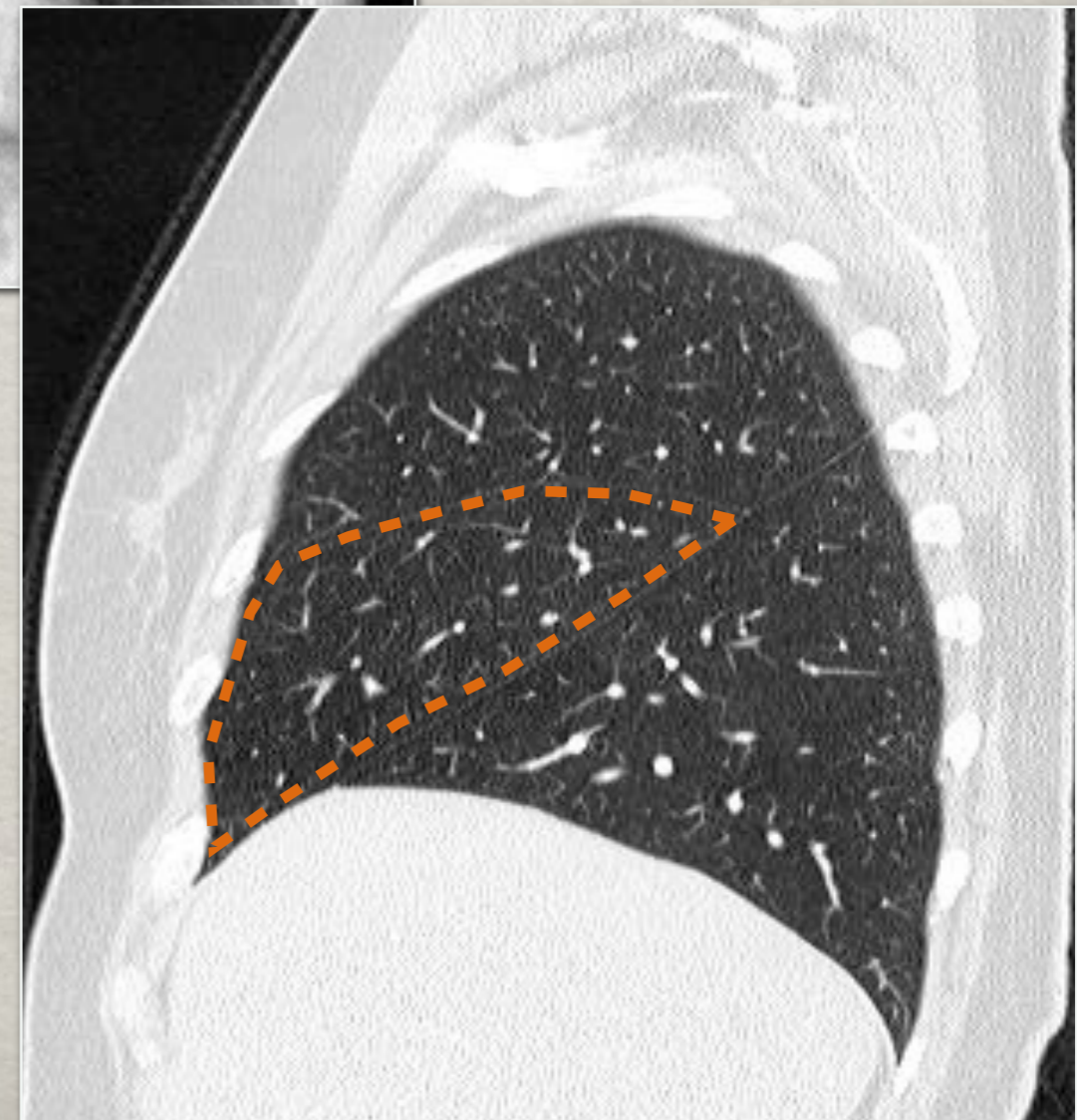

Όρια: πρόσθιο θωρακικό
τοίχωμα – ελάσσων μεσολόβιος
σχισμή – μείζων μεσολόβιος
σχισμή



ΛΟΒΟΙ ΔΕΞΙΟΥ ΠΝΕΥΜΟΝΑ

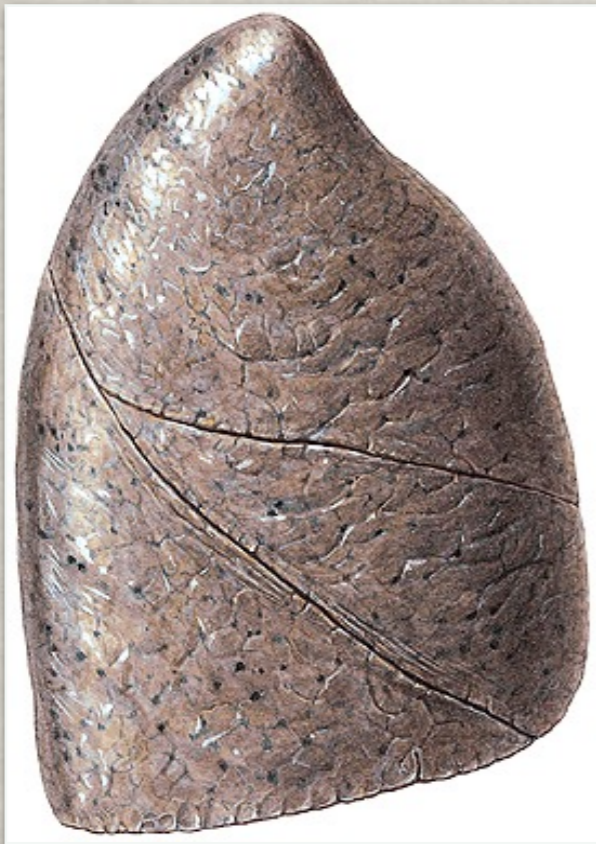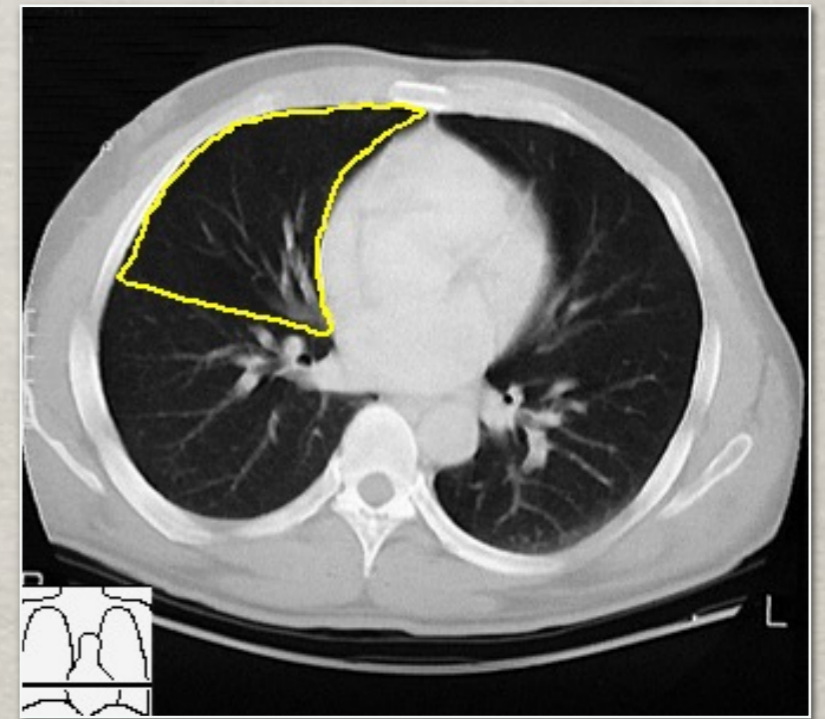
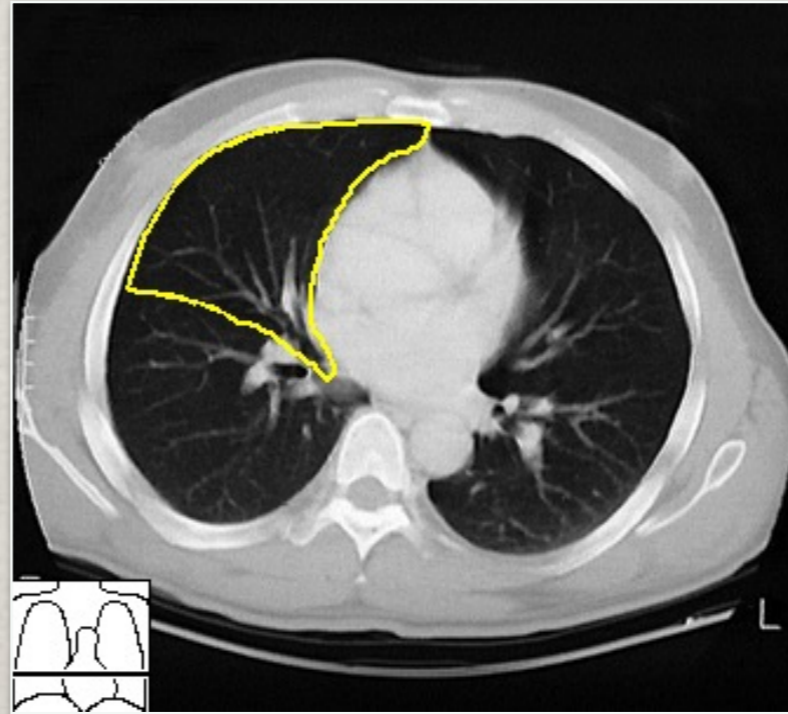
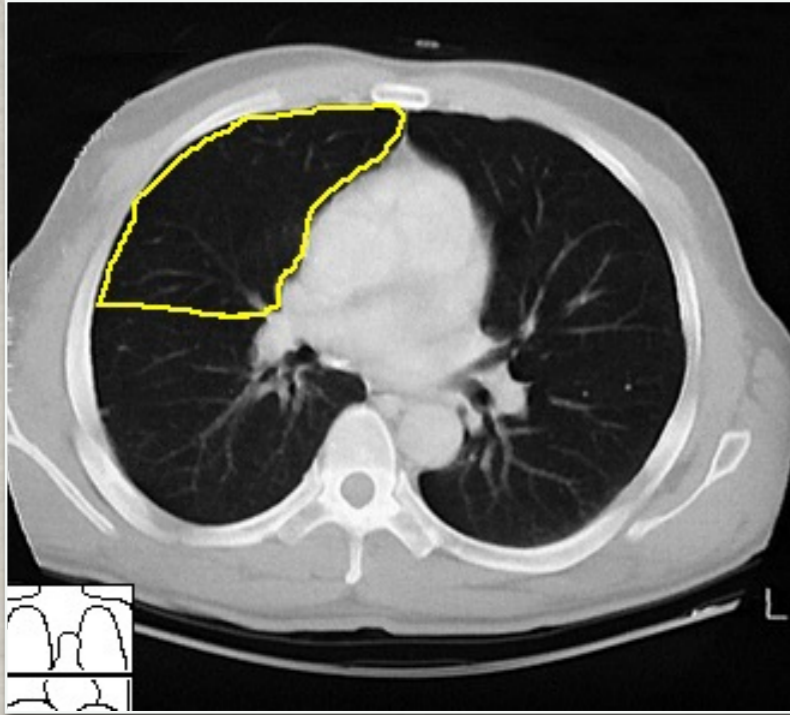
Δεξιός μέσος λοβός



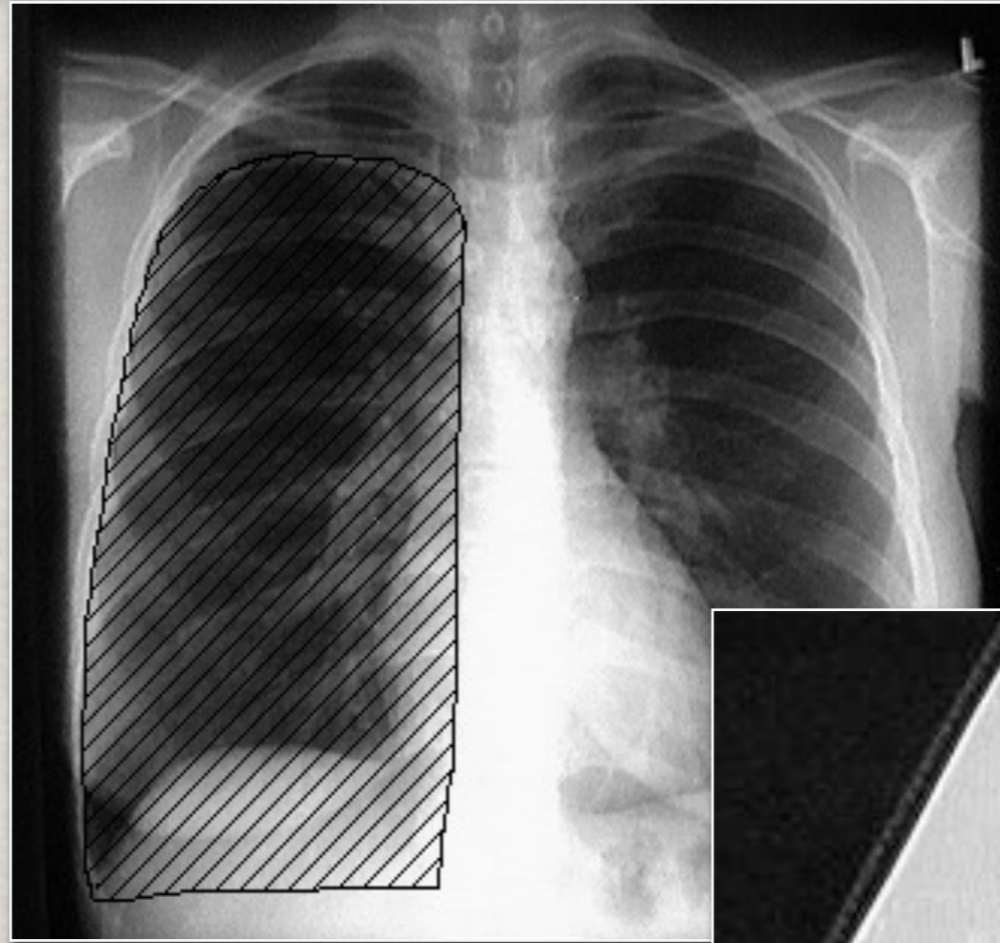
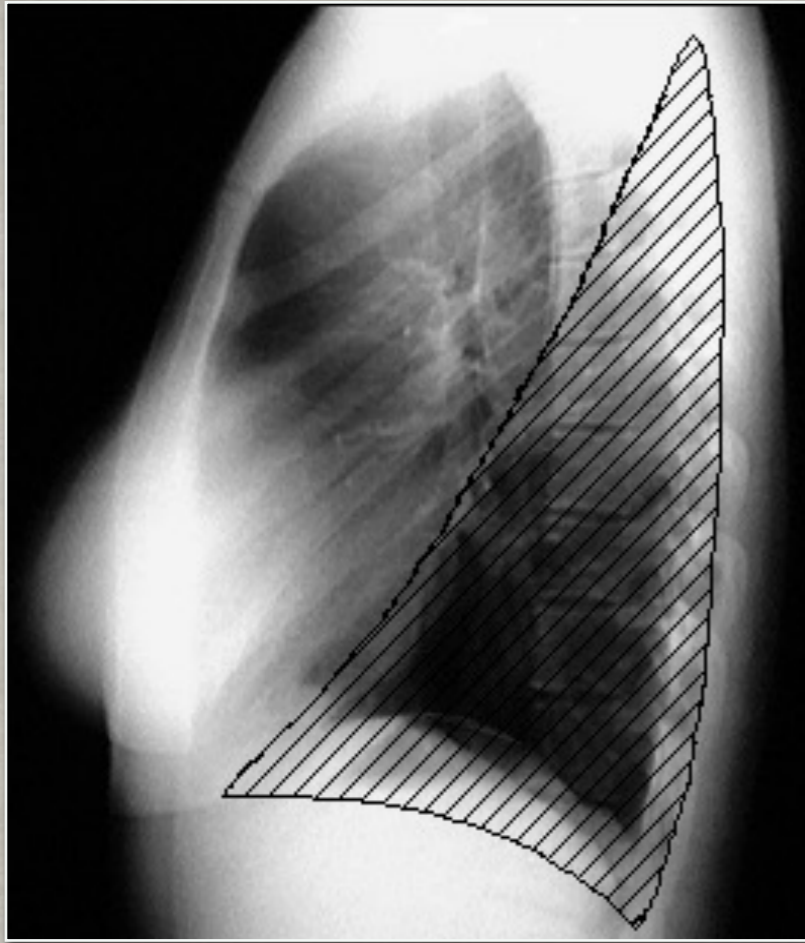
ΛΟΒΟΙ ΔΕΞΙΟΥ ΠΝΕΥΜΟΝΑ

Δεξιός μέσος λοβός

Όρια: πρόσθιο θωρακικό
τοίχωμα – ελάσσονα
μεσολόβιος σχισμή - καρδιά

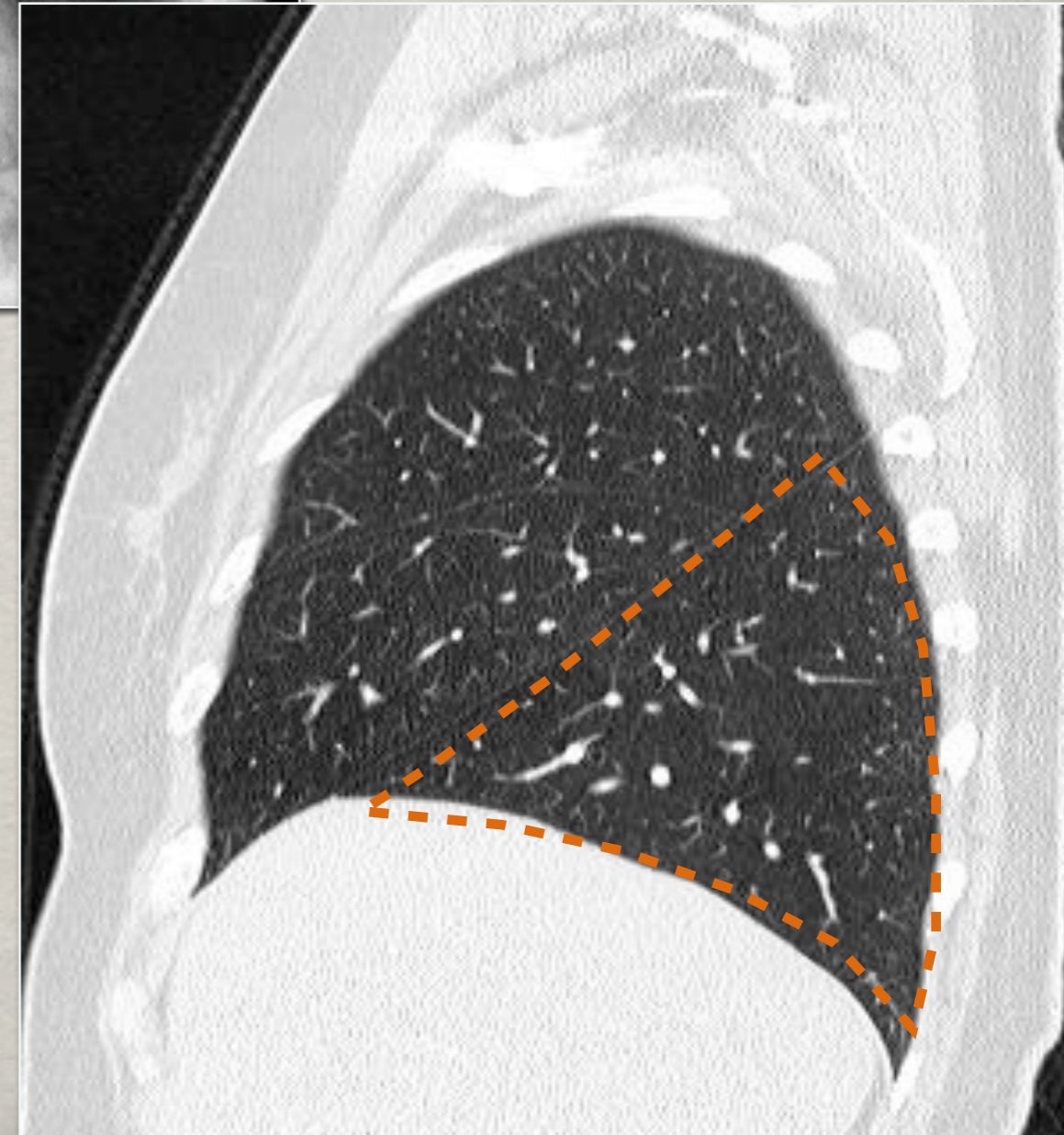


ΘΩΡΑΚΑΣ



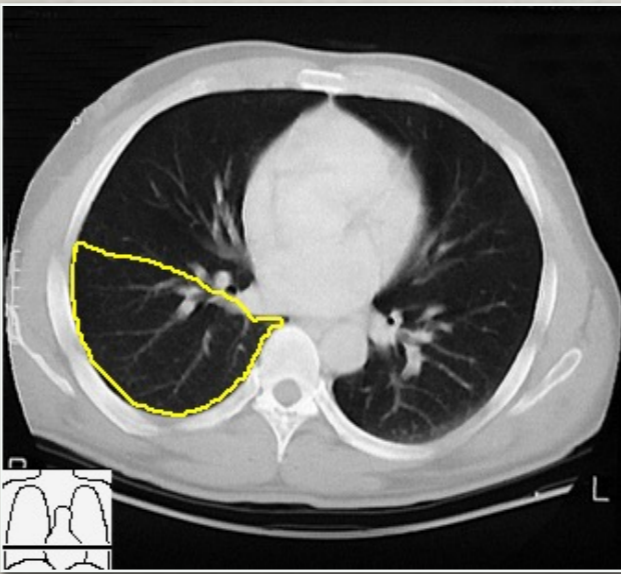
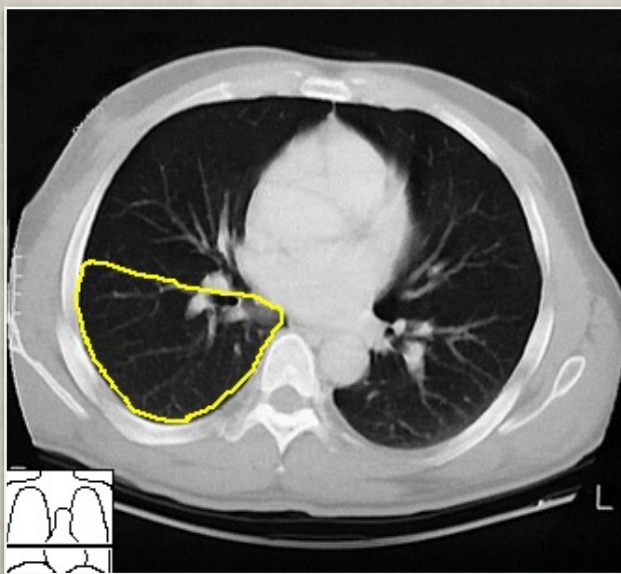
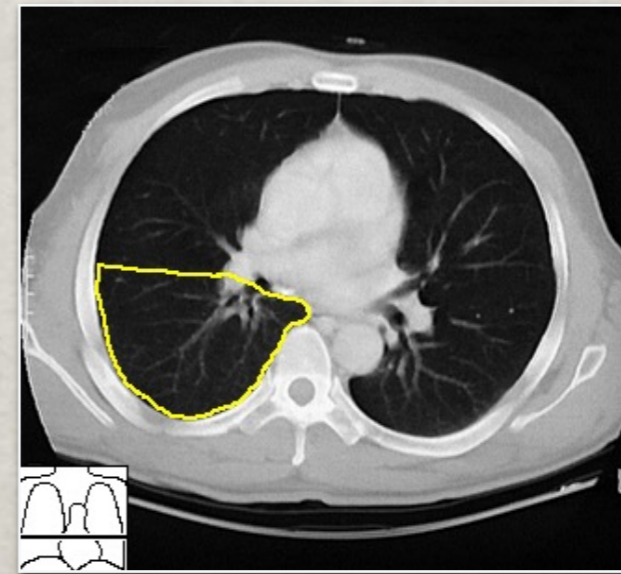
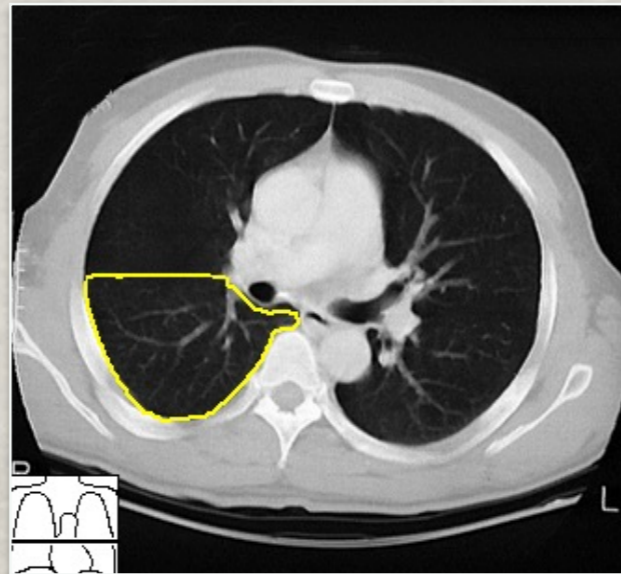
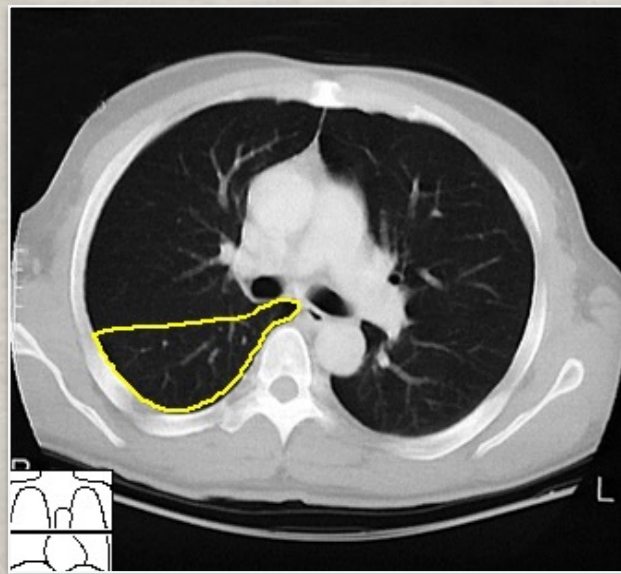
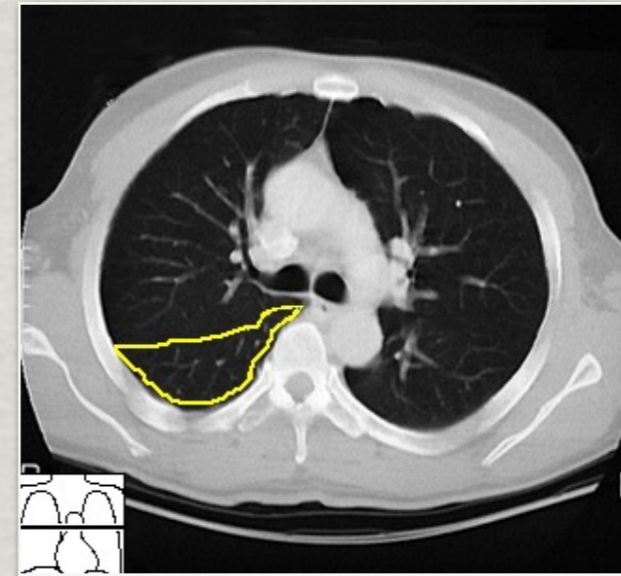
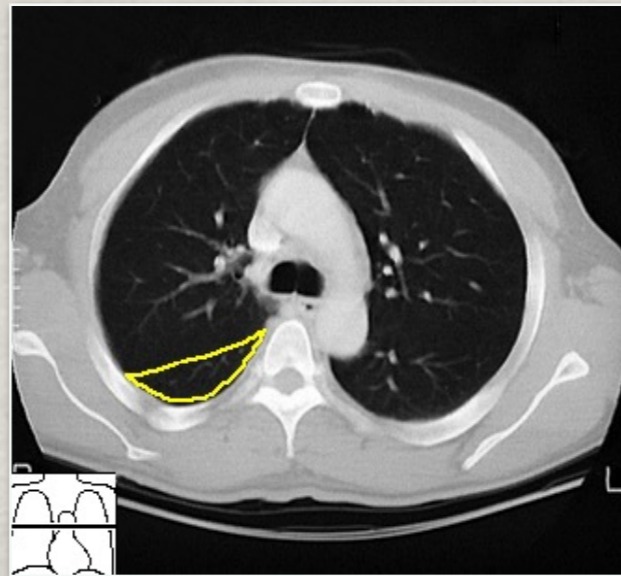
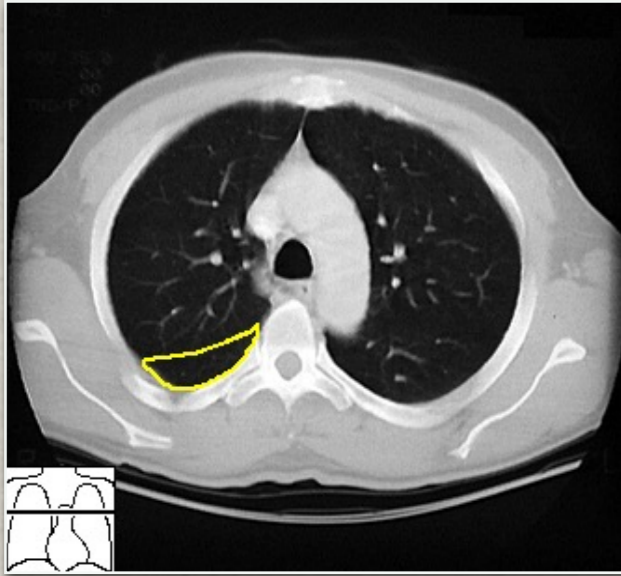
ΛΟΒΟΙ ΔΕΞΙΟΥ ΠΝΕΥΜΟΝΑ

Δεξιός κάτω λοβός

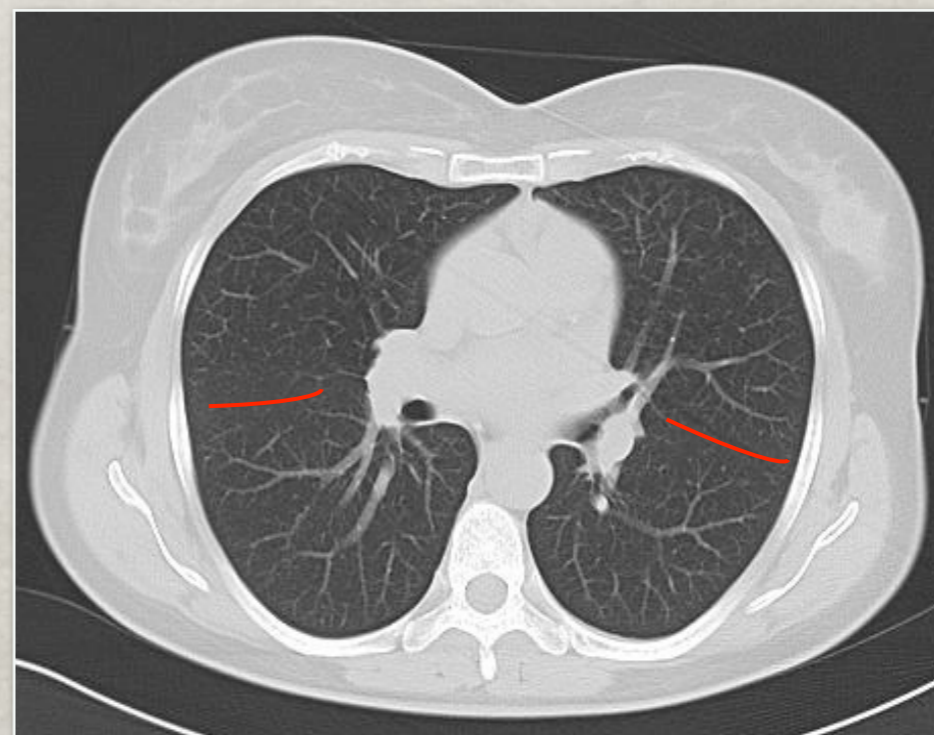
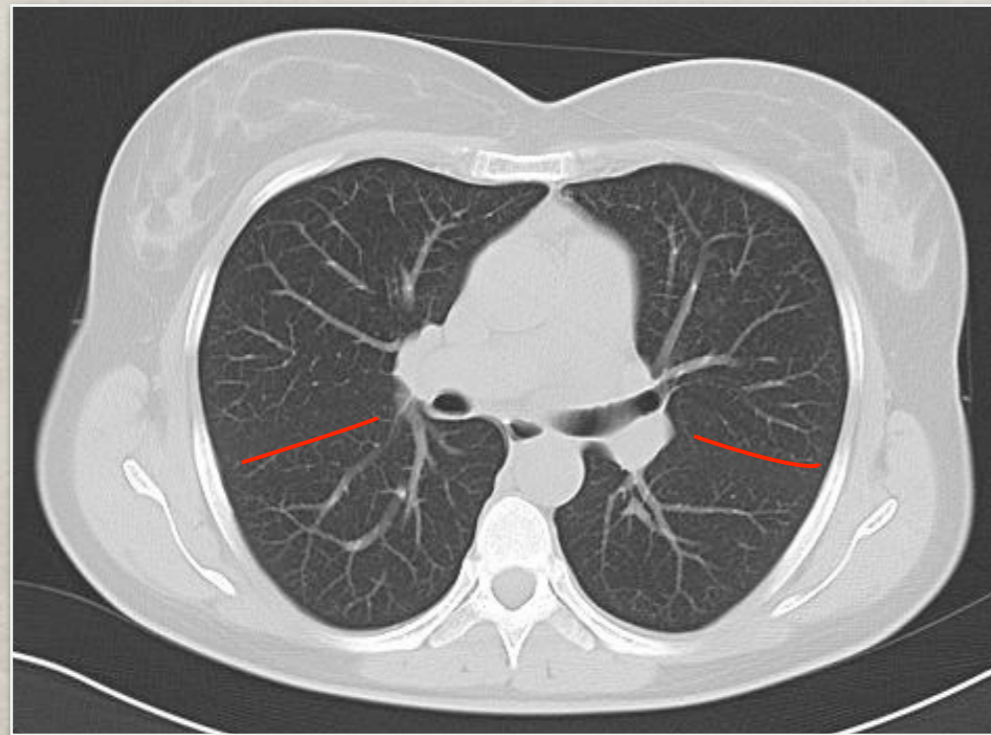
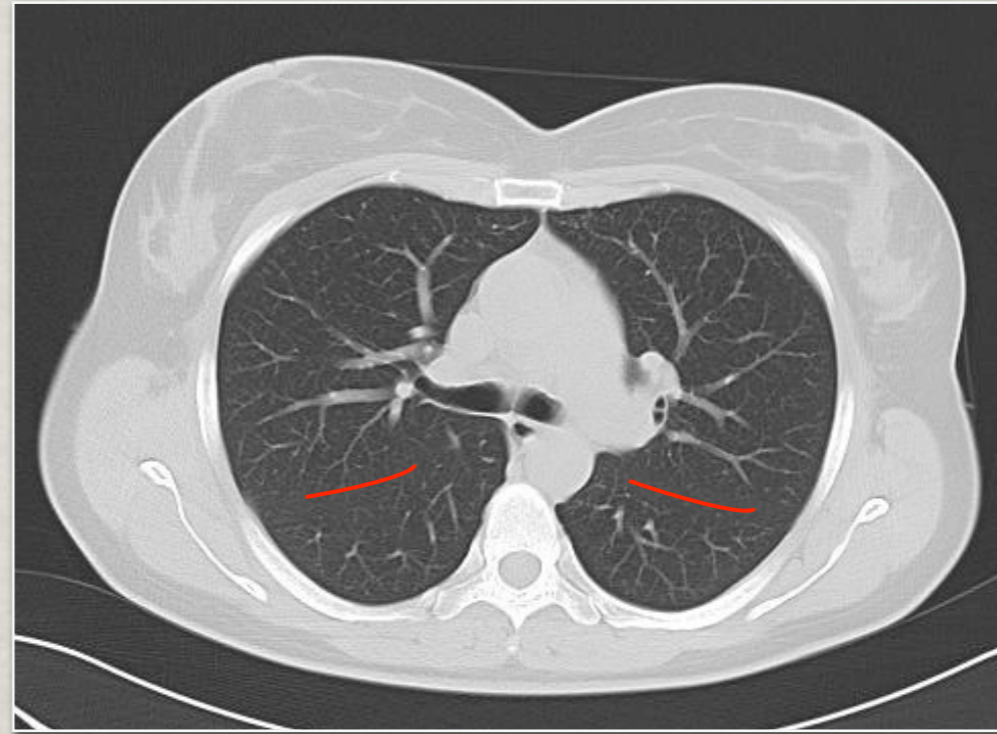
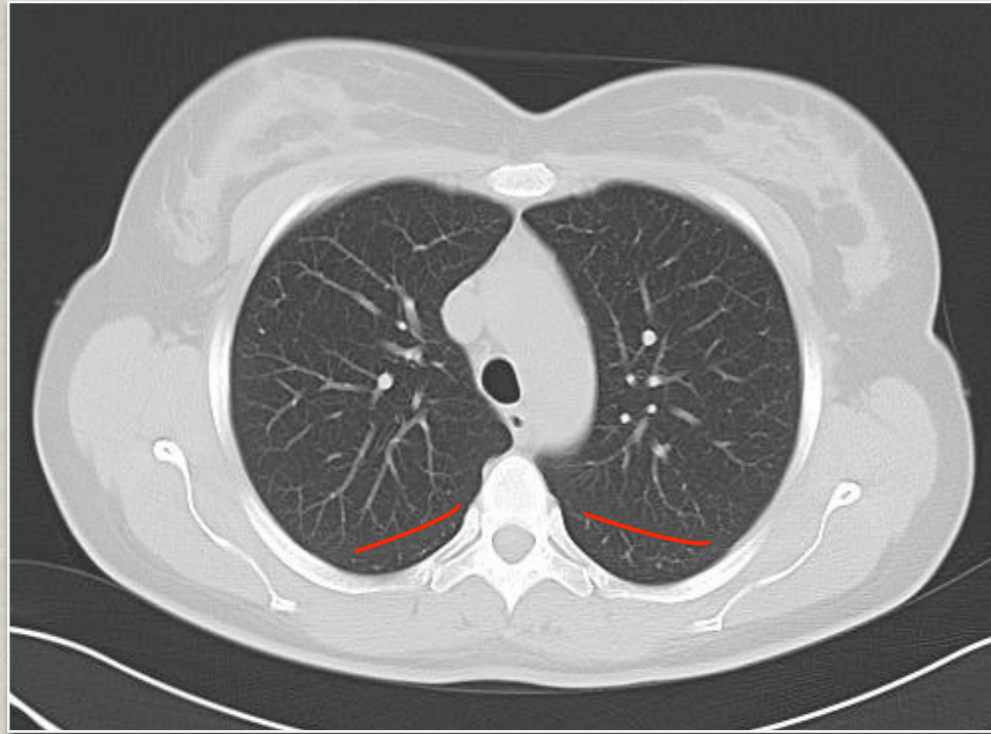


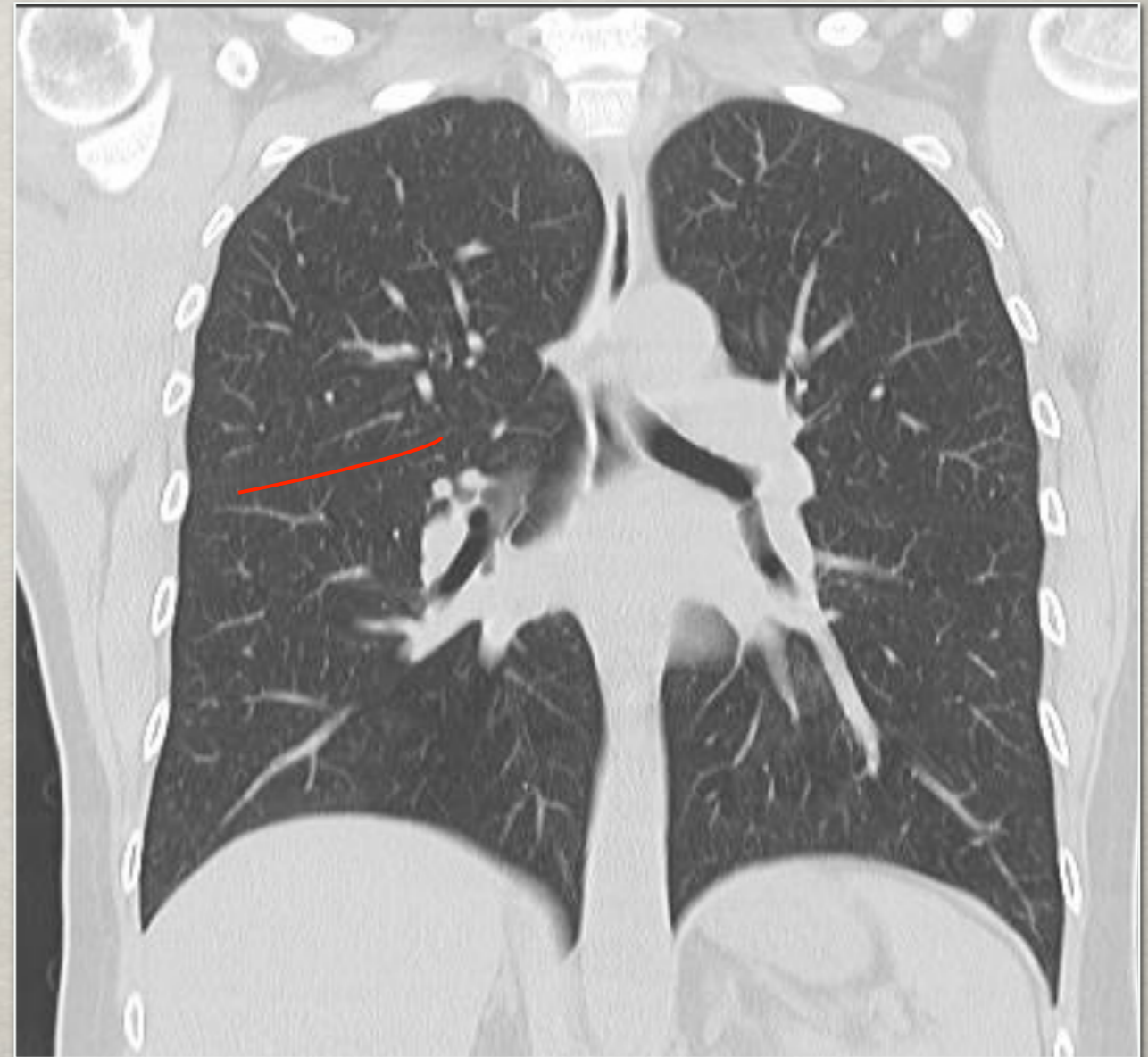
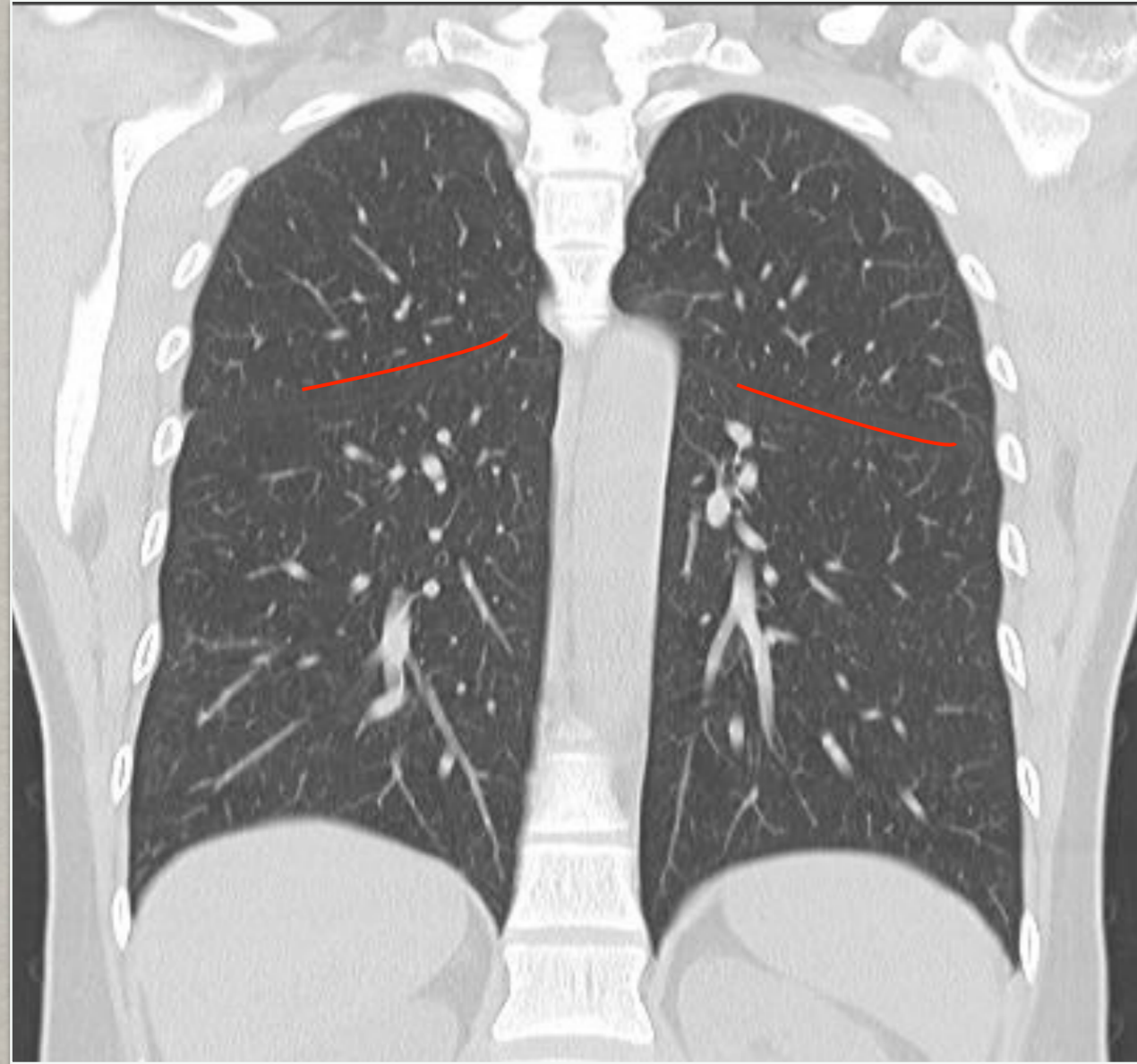
ΛΟΒΟΙ ΔΕΞΙΟΥ ΠΝΕΥΜΟΝΑ

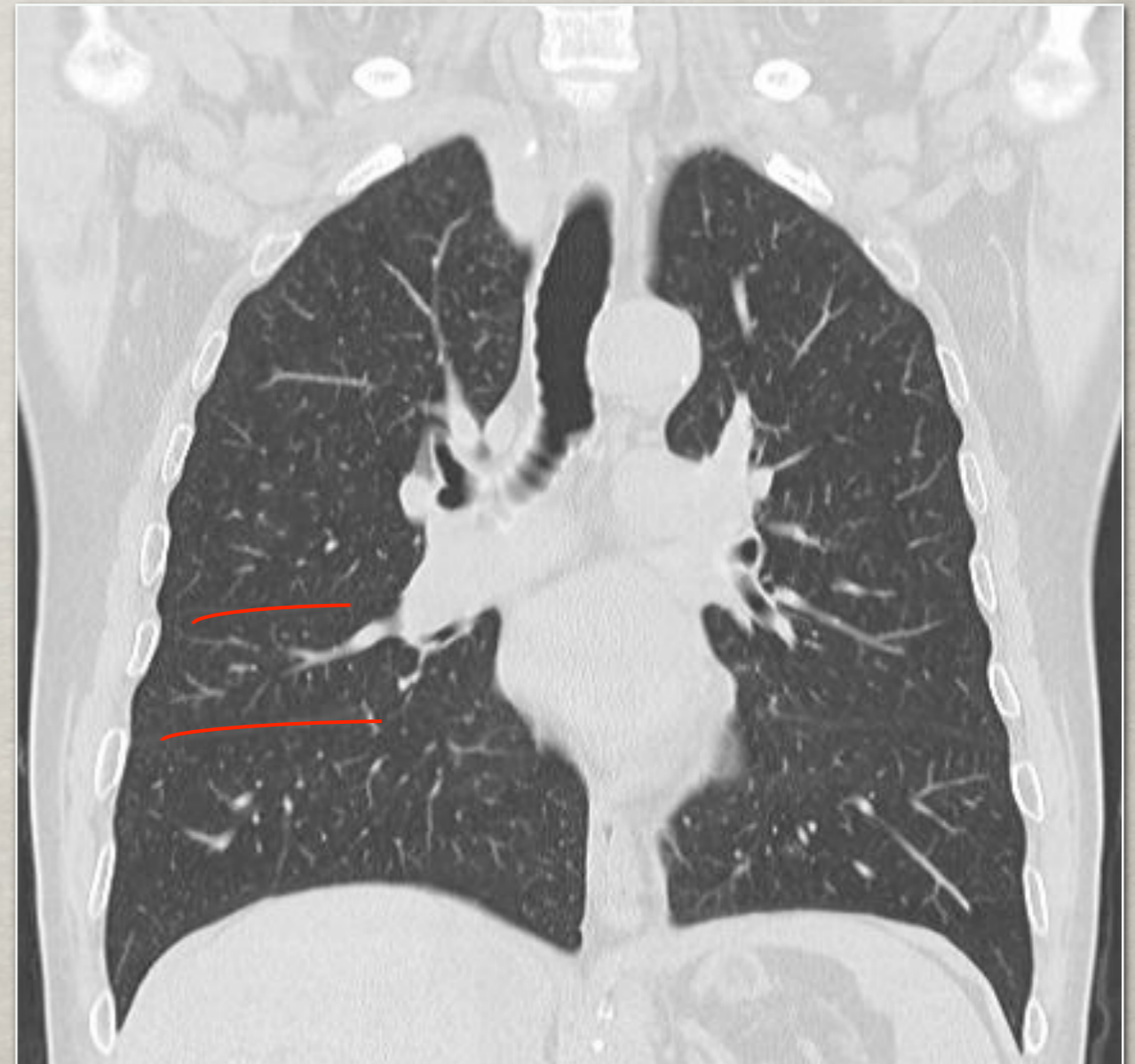
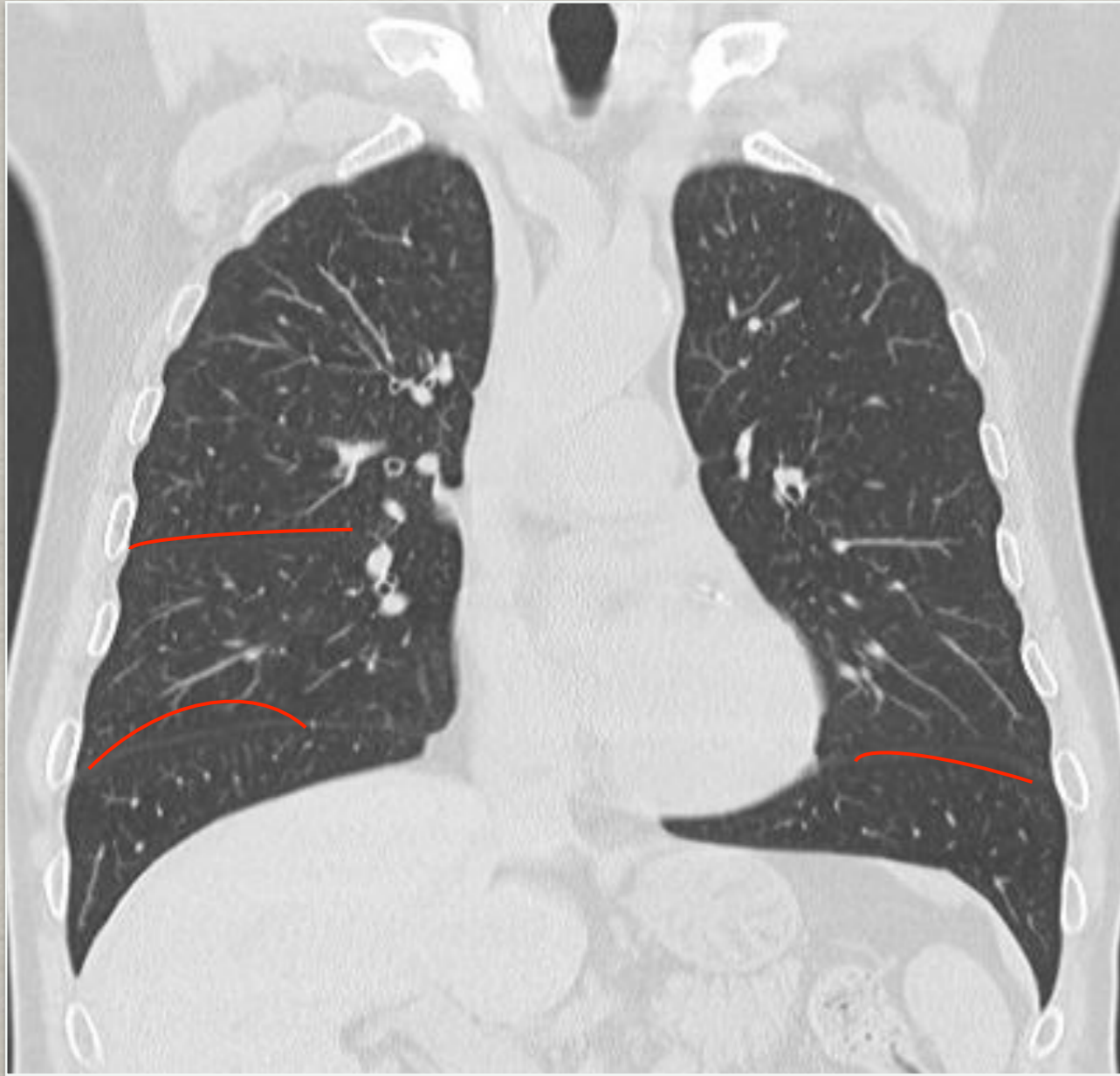
Δεξιός κάτω λοβός



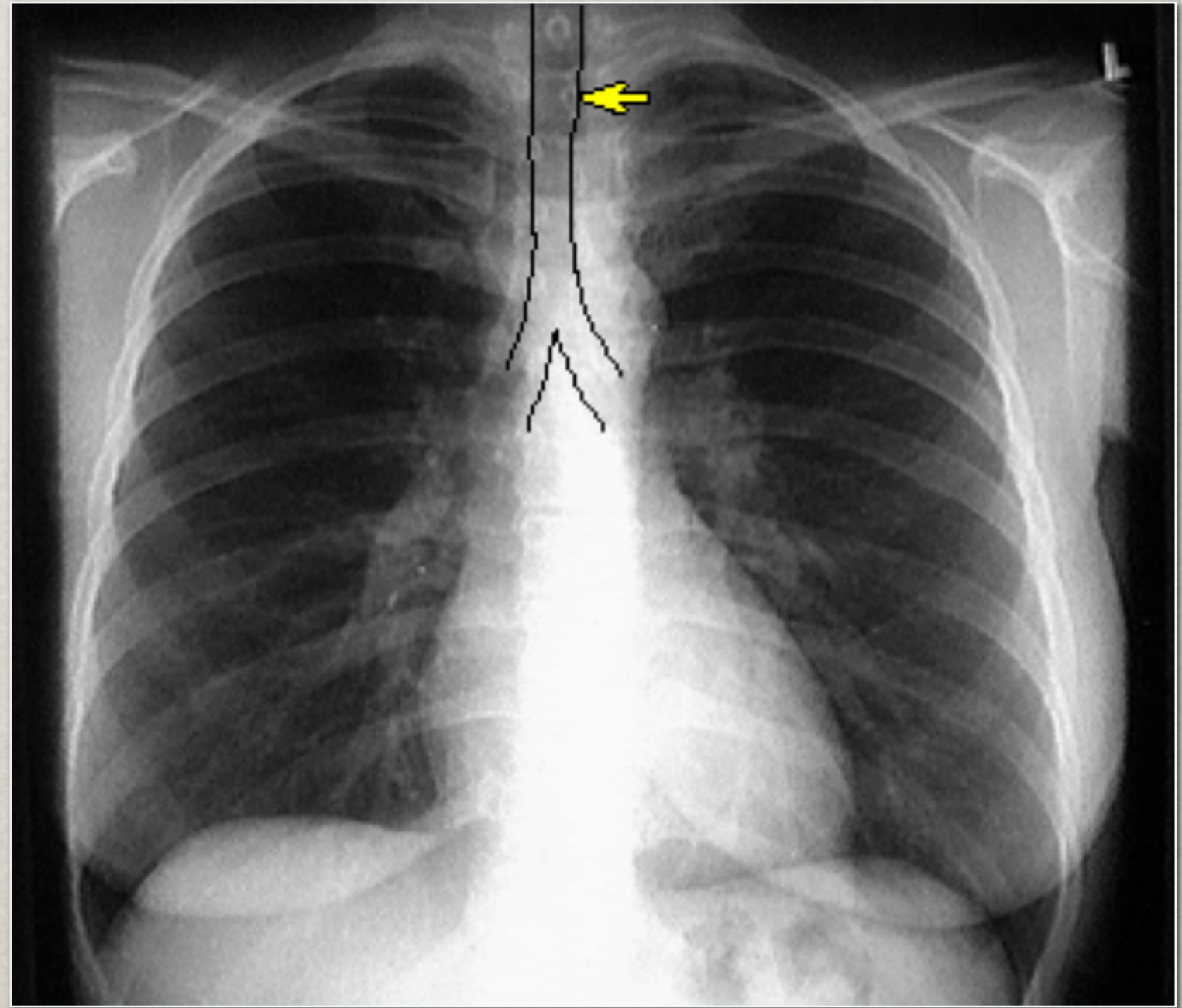
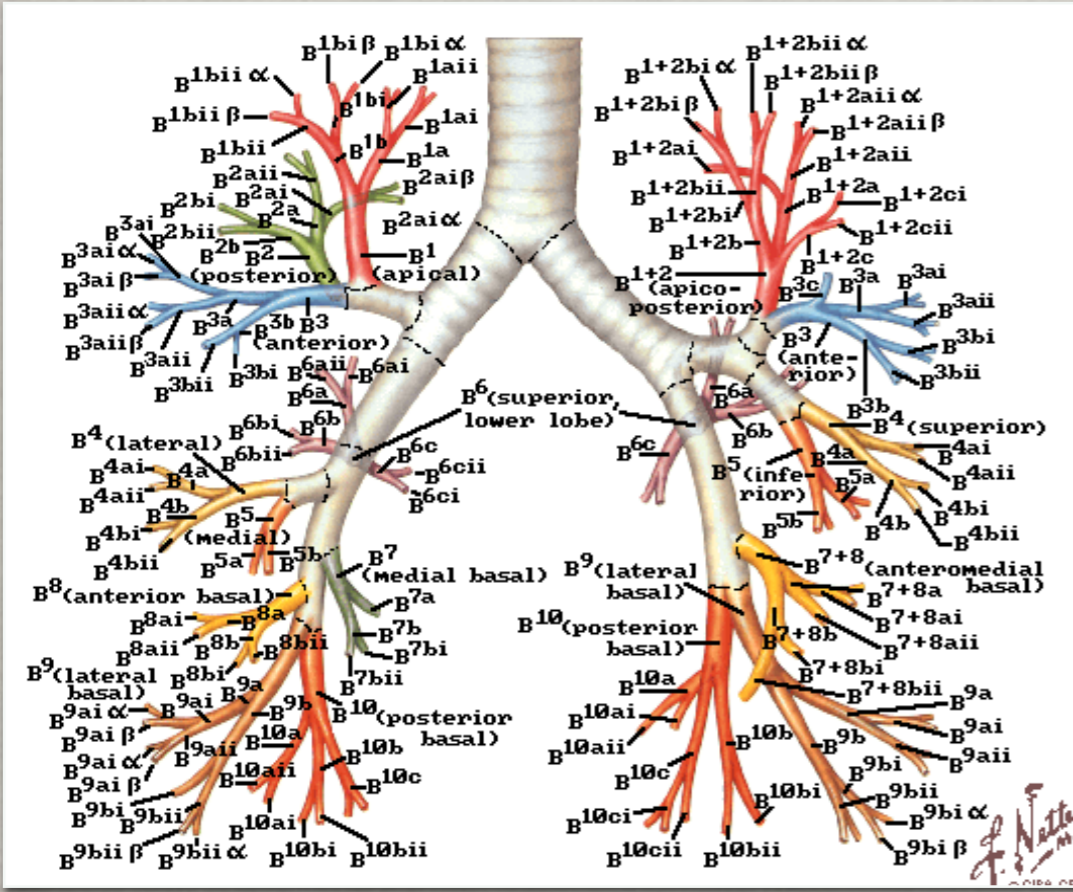
Όρια: μείζων μεσολόβιος σχισμή –
οπίσθιο θωρακικό τοίχωμα



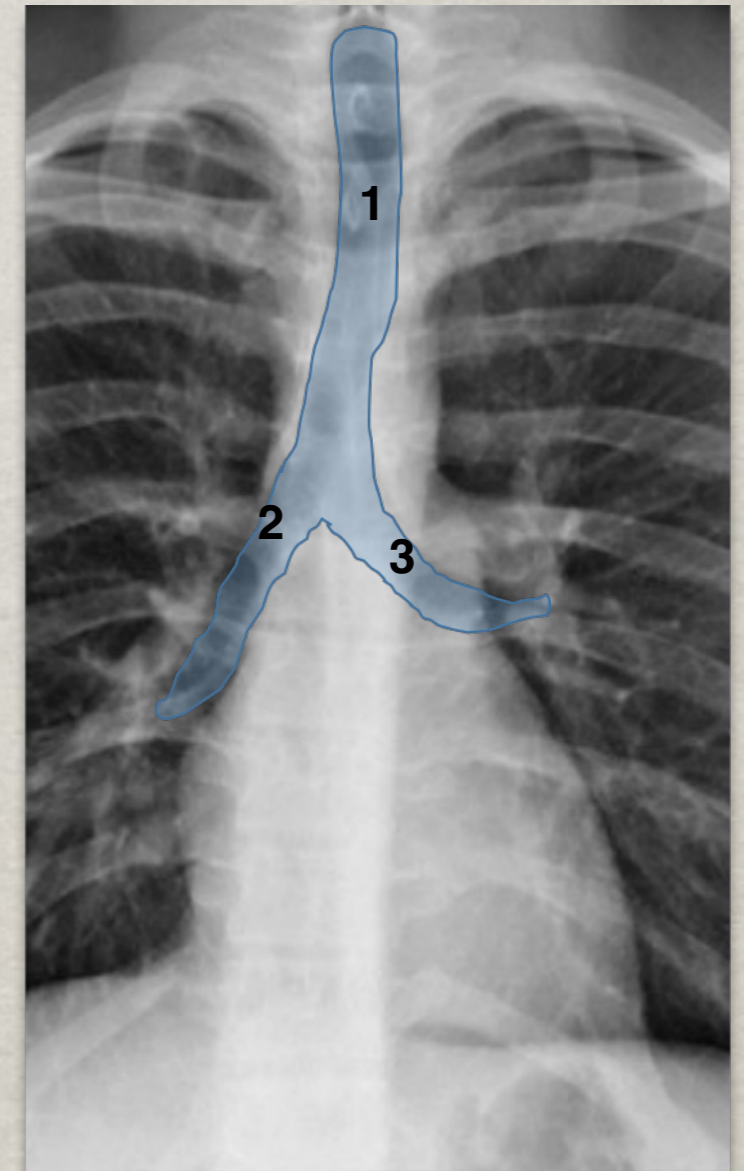
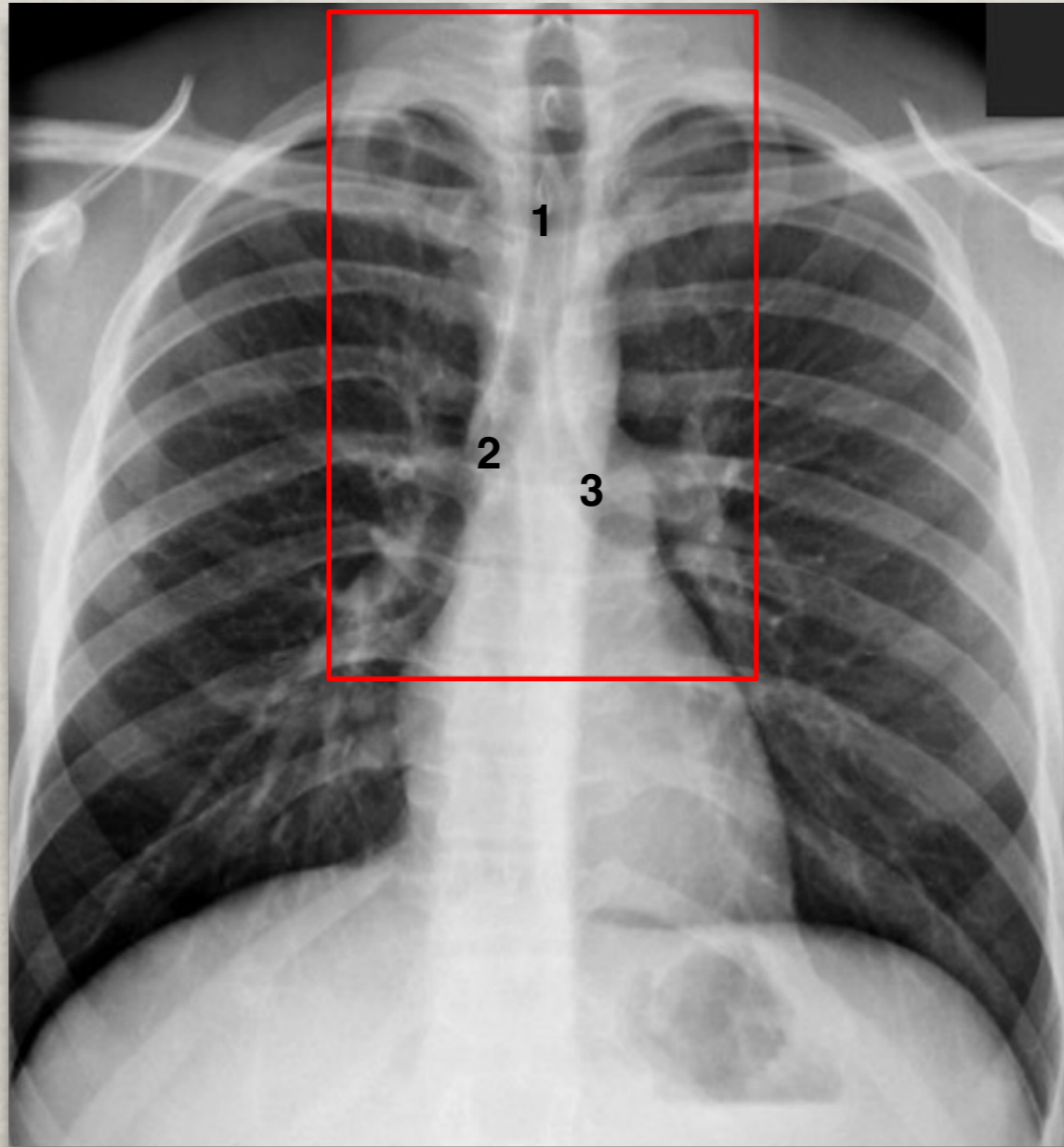
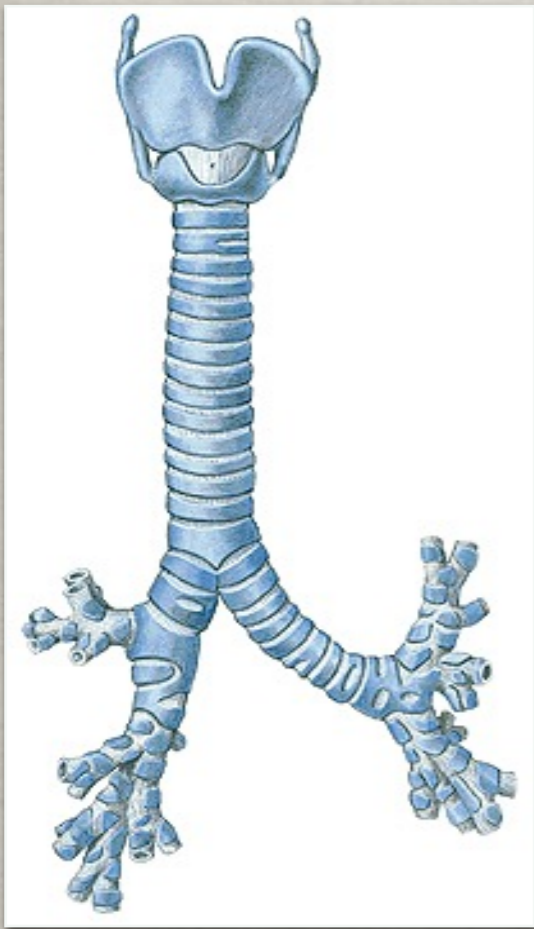




ΤΡΑΧΕΙΑ - ΒΡΟΓΧΟΙ



ΤΡΑΧΕΙΑ - ΚΥΡΙΟΙ ΒΡΟΓΧΟΙ

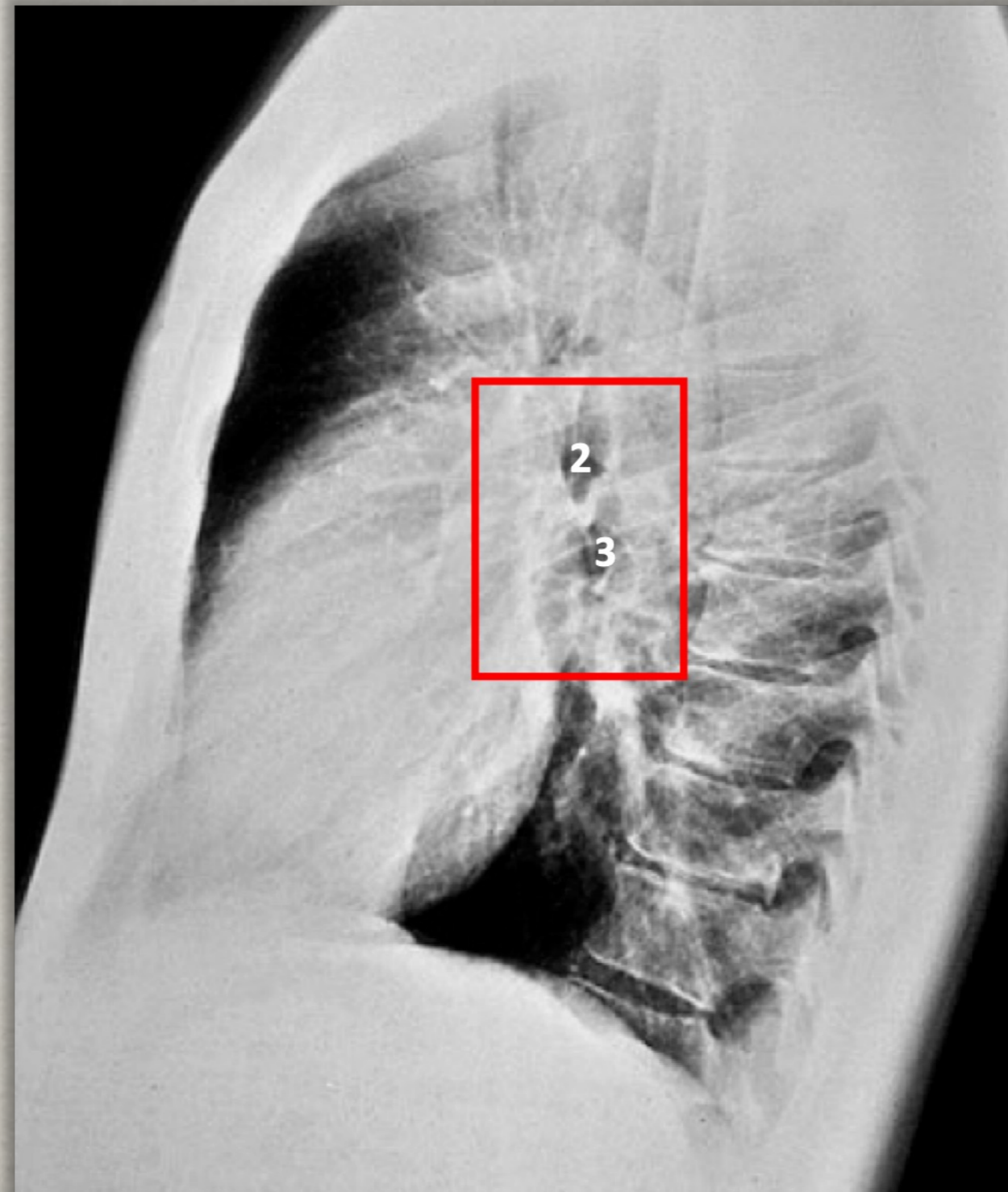


- ① Τραχεία
- ② Δεξιός κύριος βρόγχος
- ③ Αριστερός κύριος βρόγχος

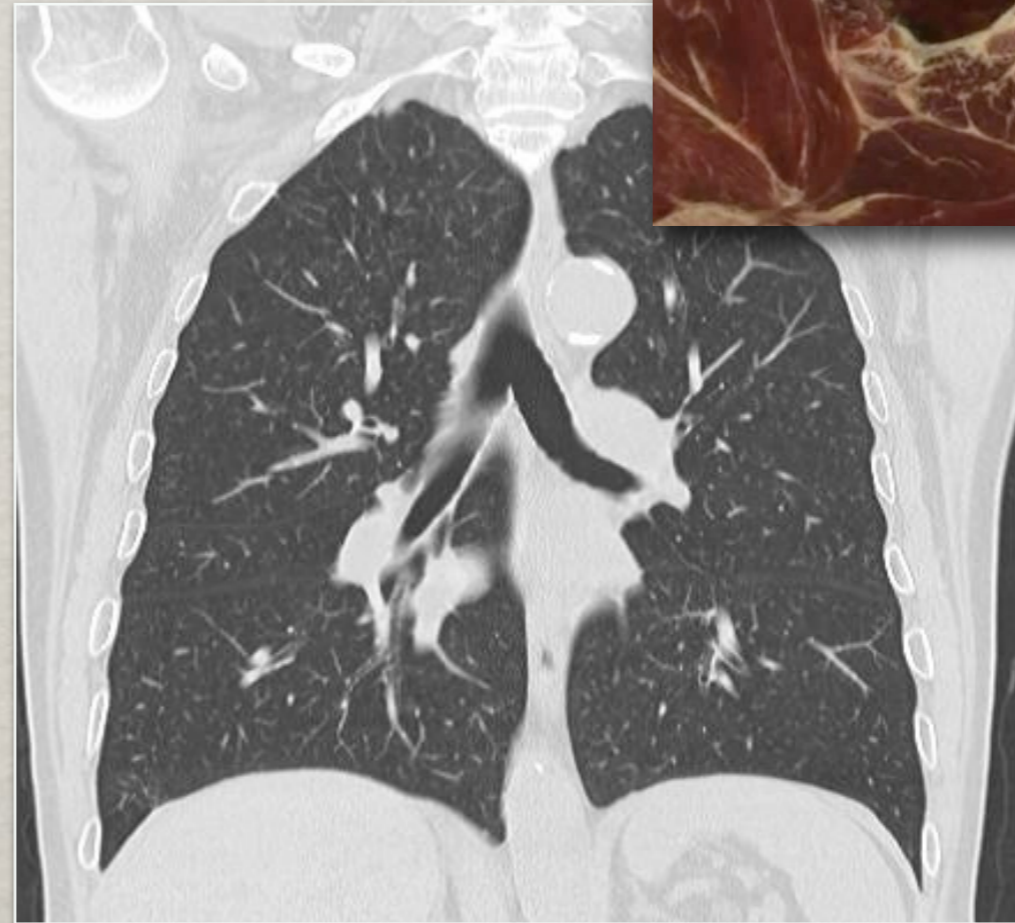
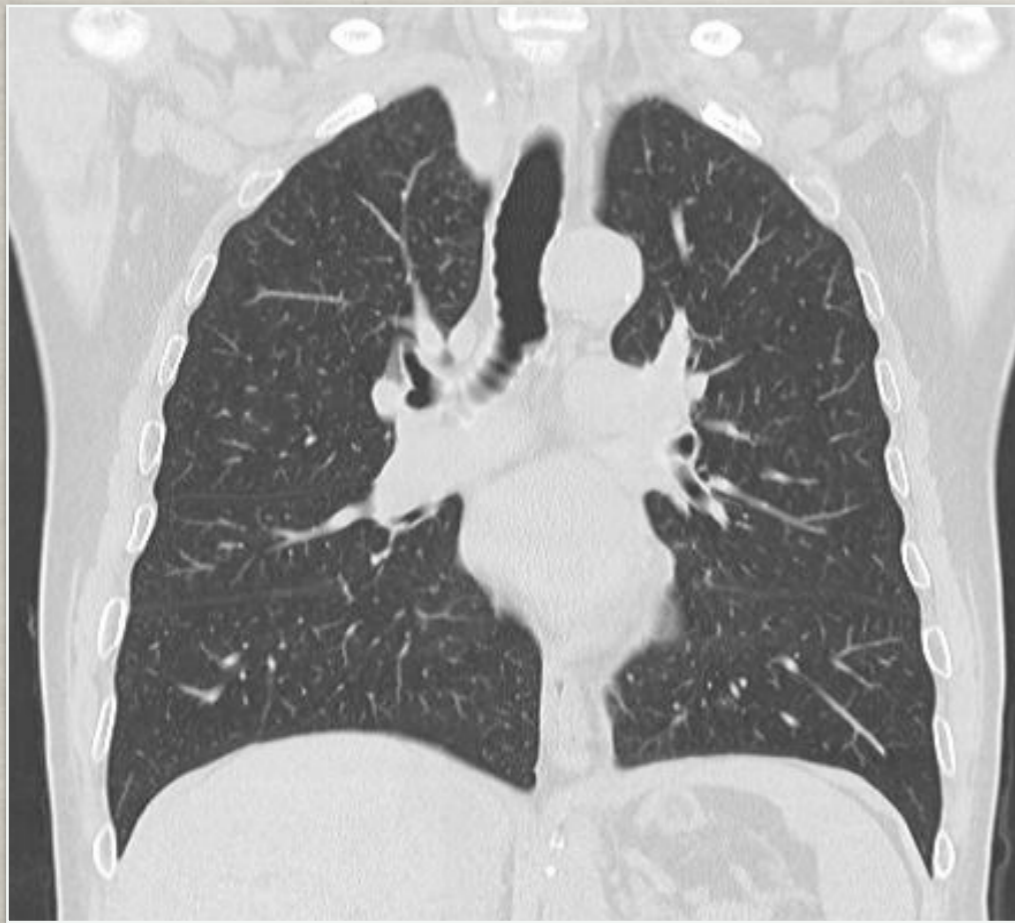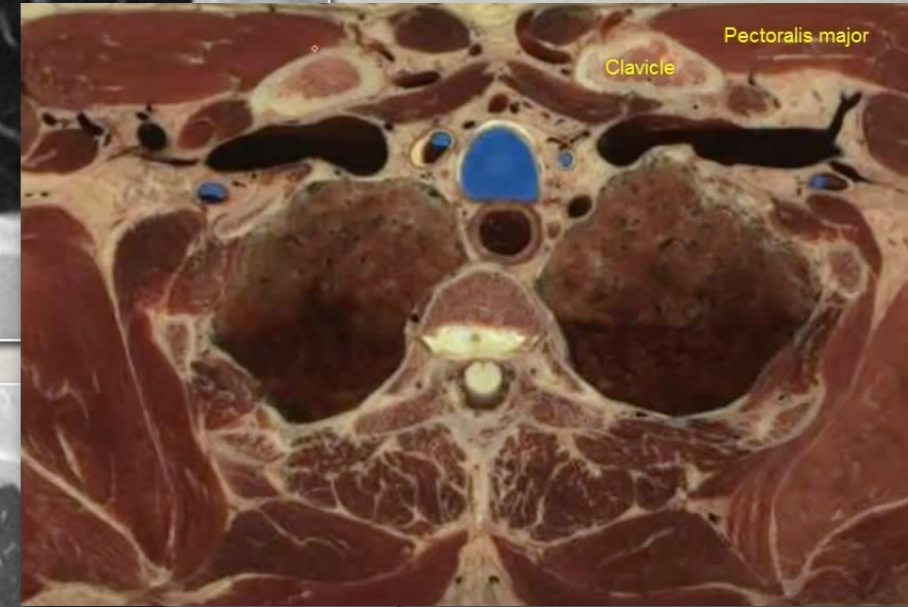
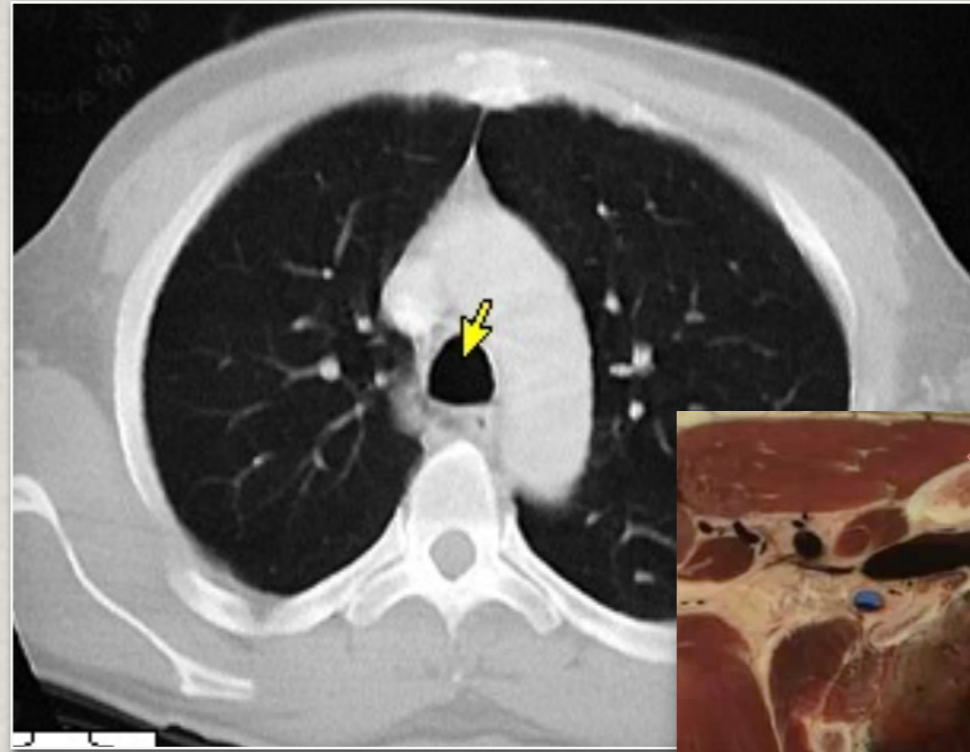
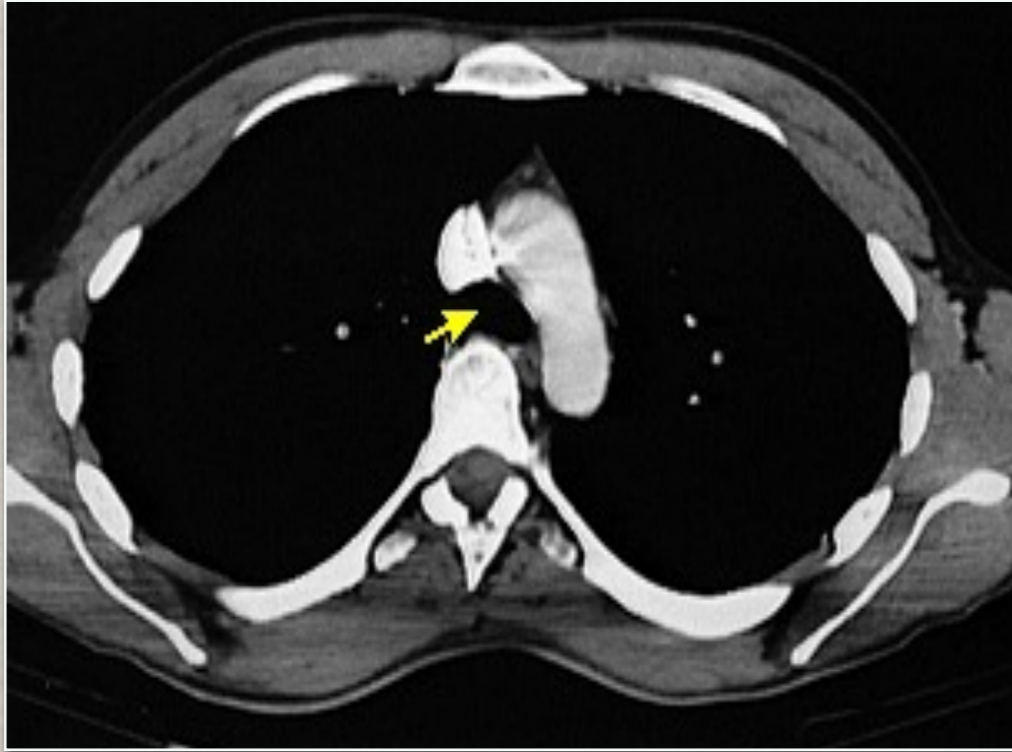
ΤΡΑΧΕΙΑ - ΚΥΡΙΟΙ ΒΡΟΓΧΟΙ

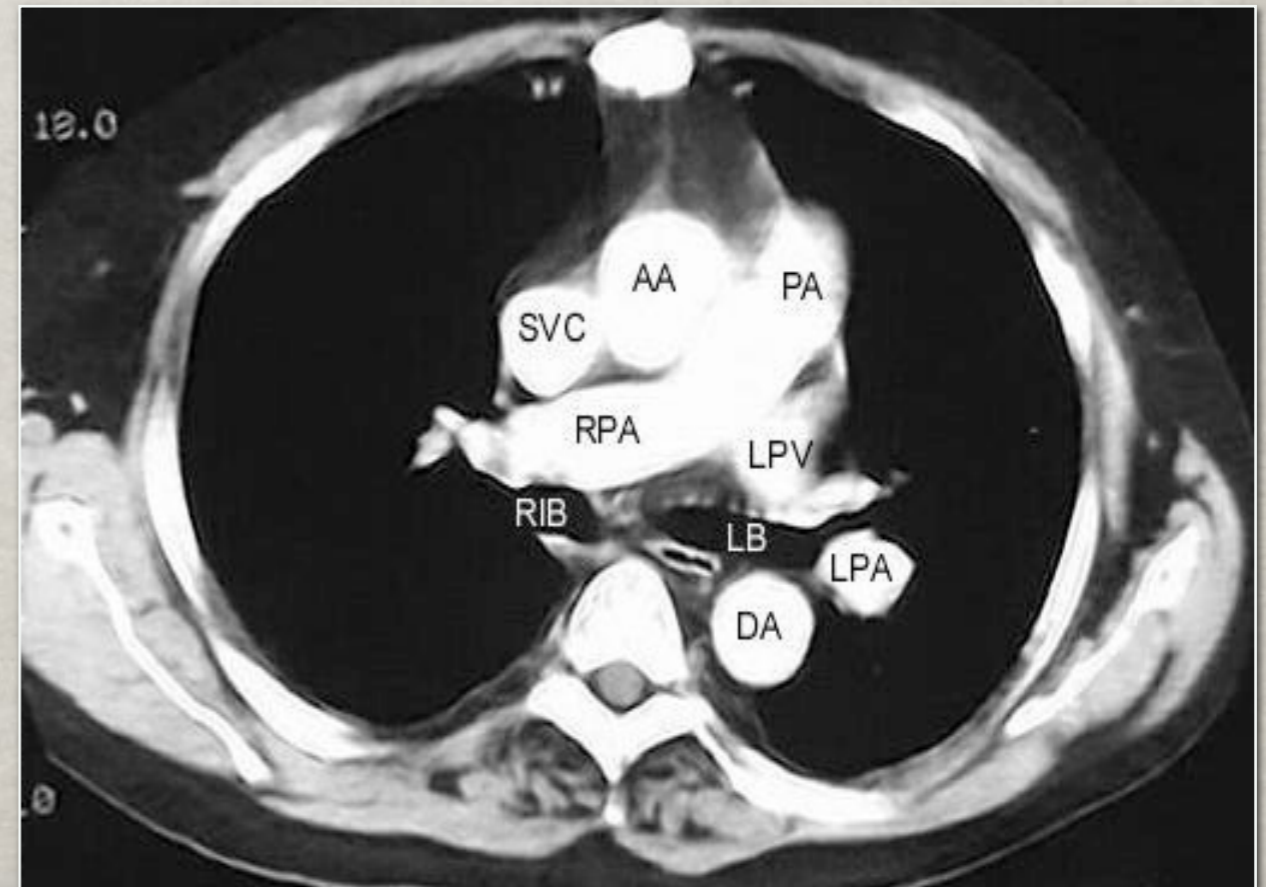
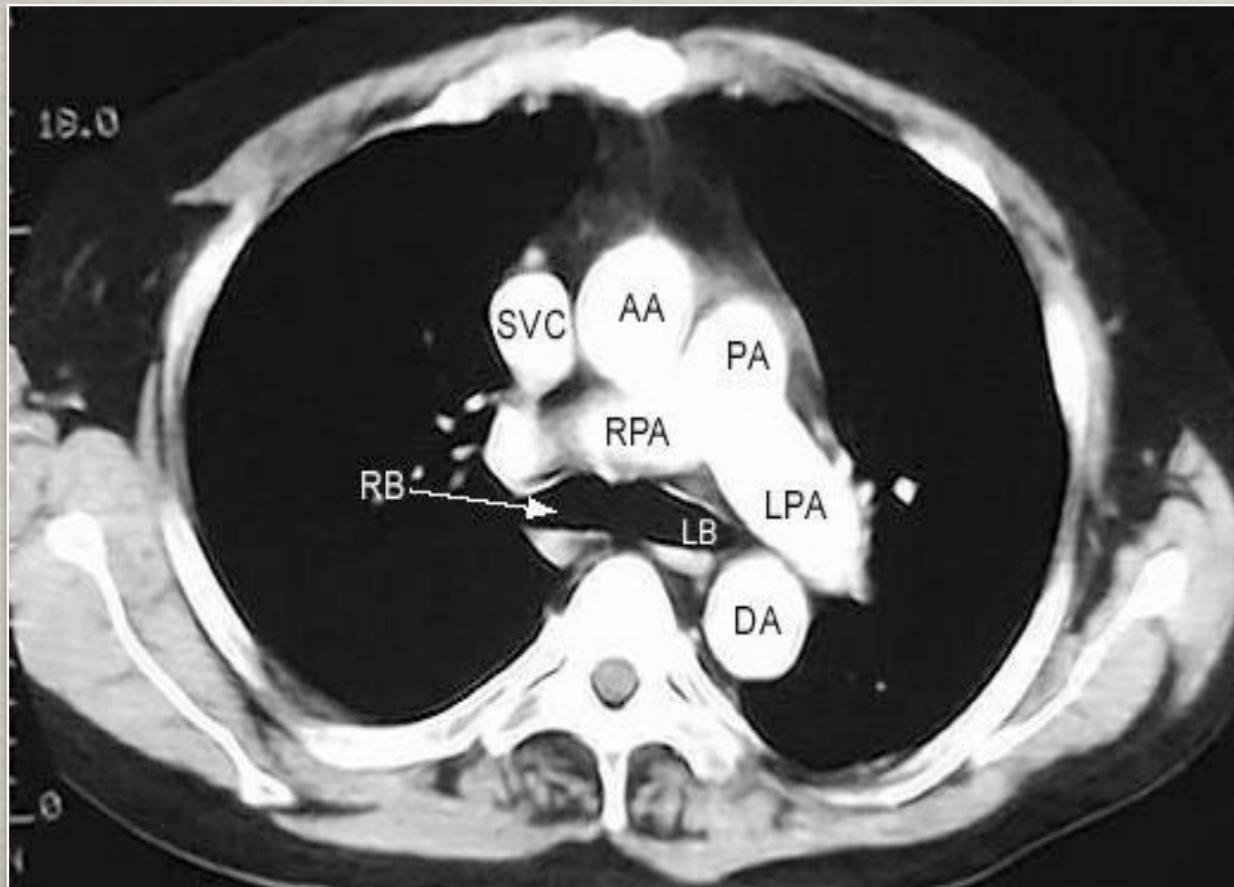
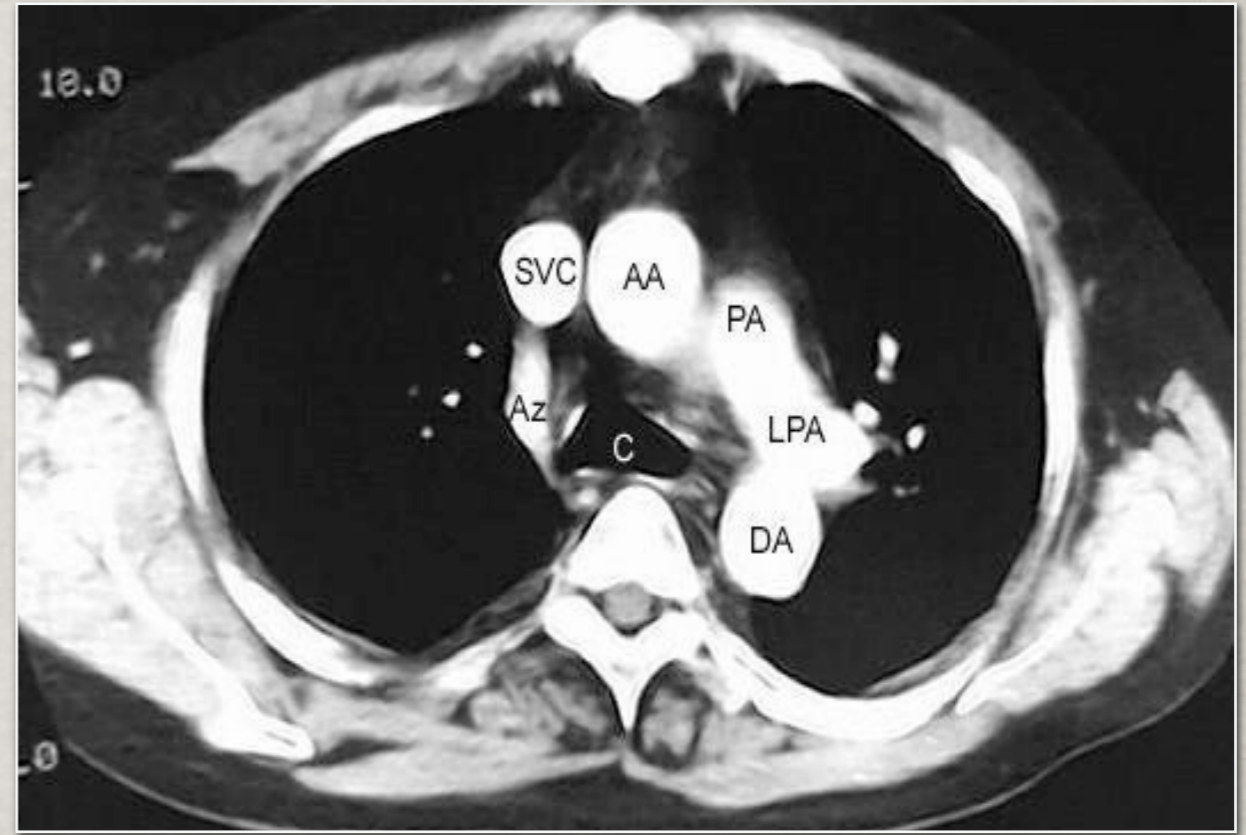
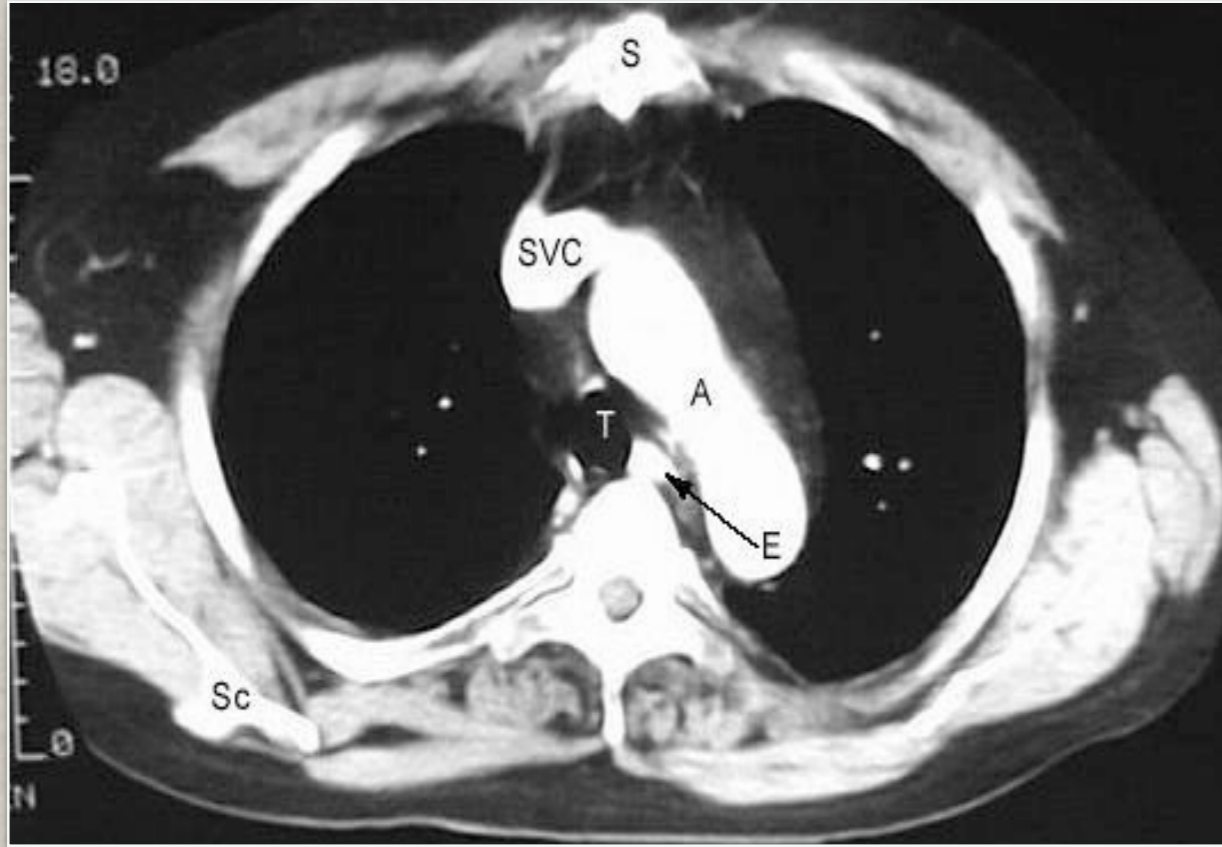
2: δεξιός βρόγχος

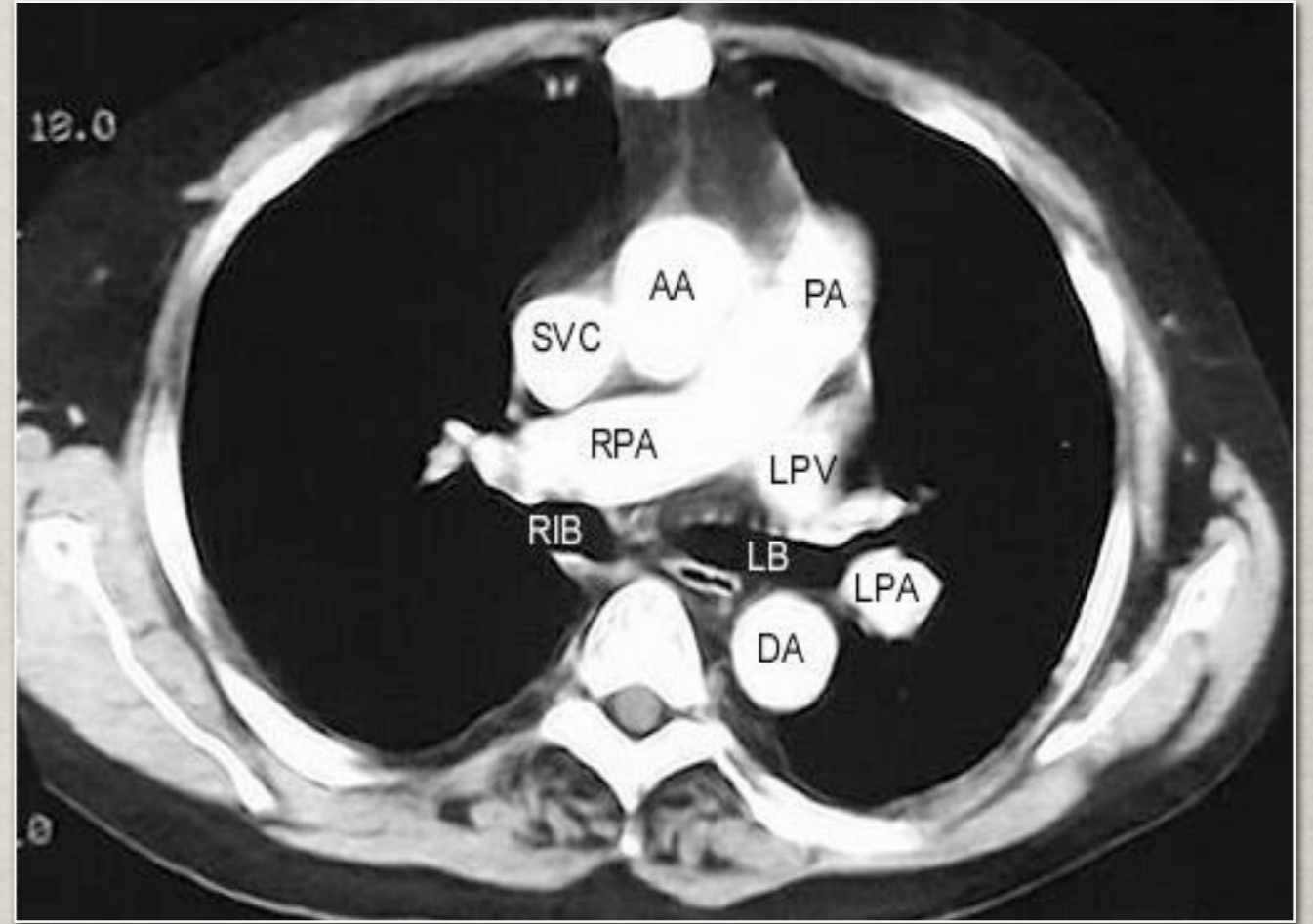
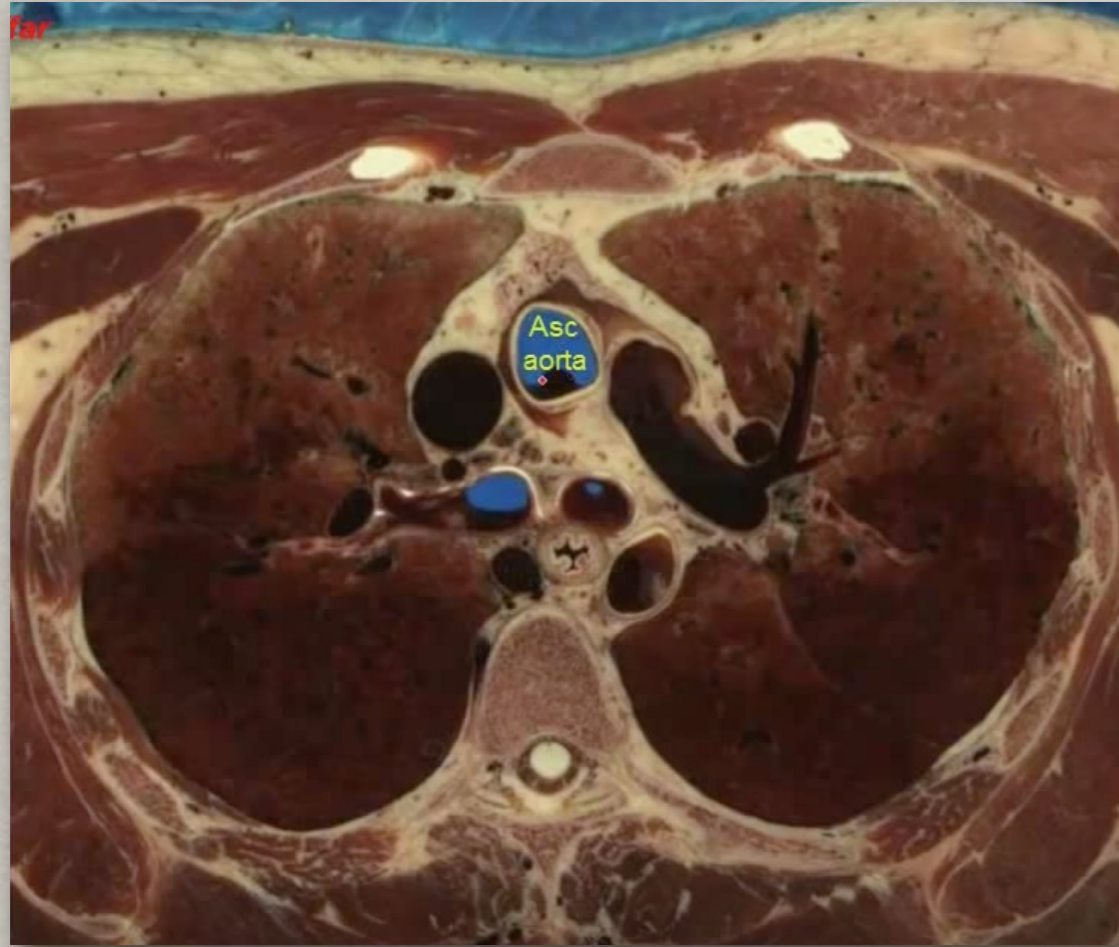3: αριστερός βρόγχος



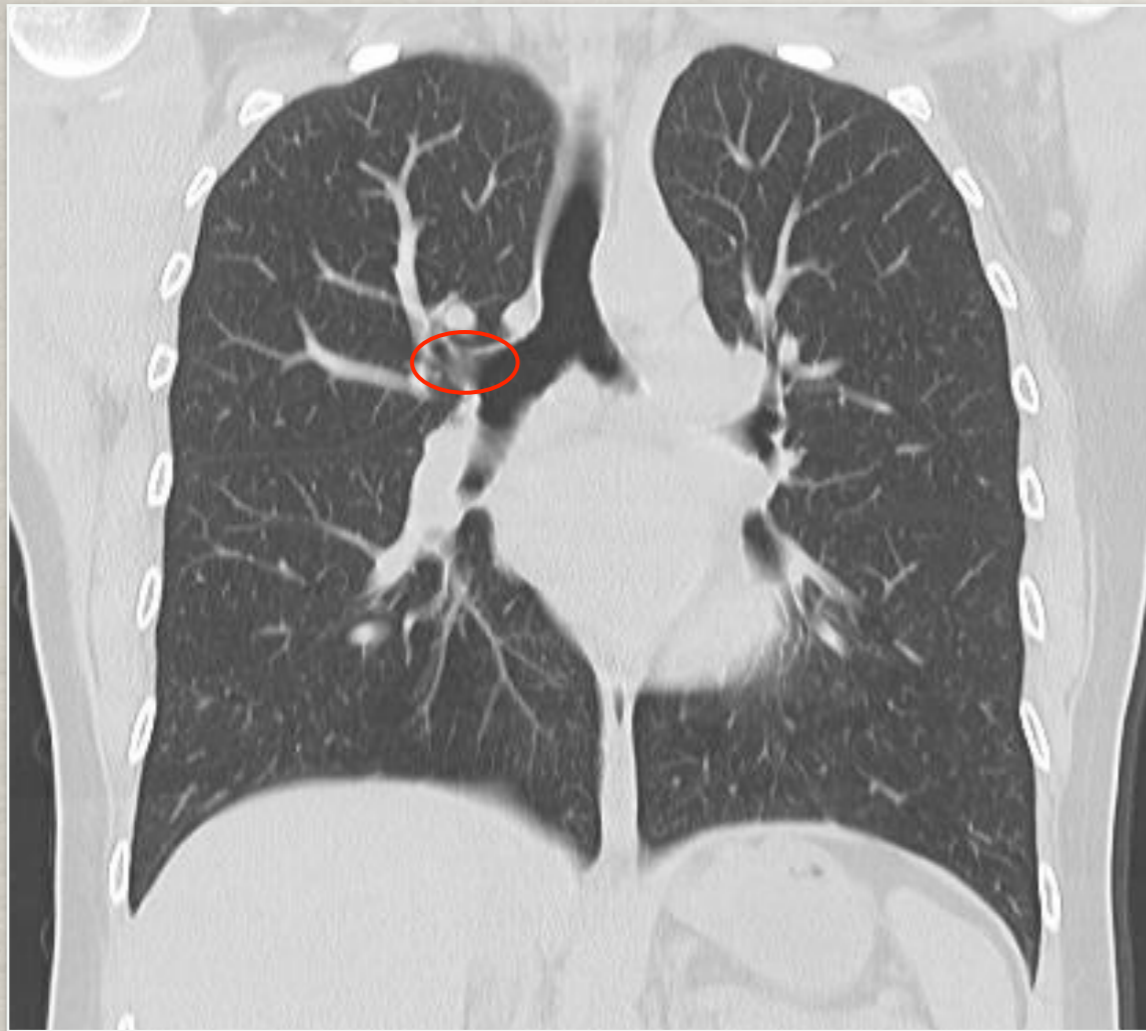ΘΩΡΑΚΑΣ



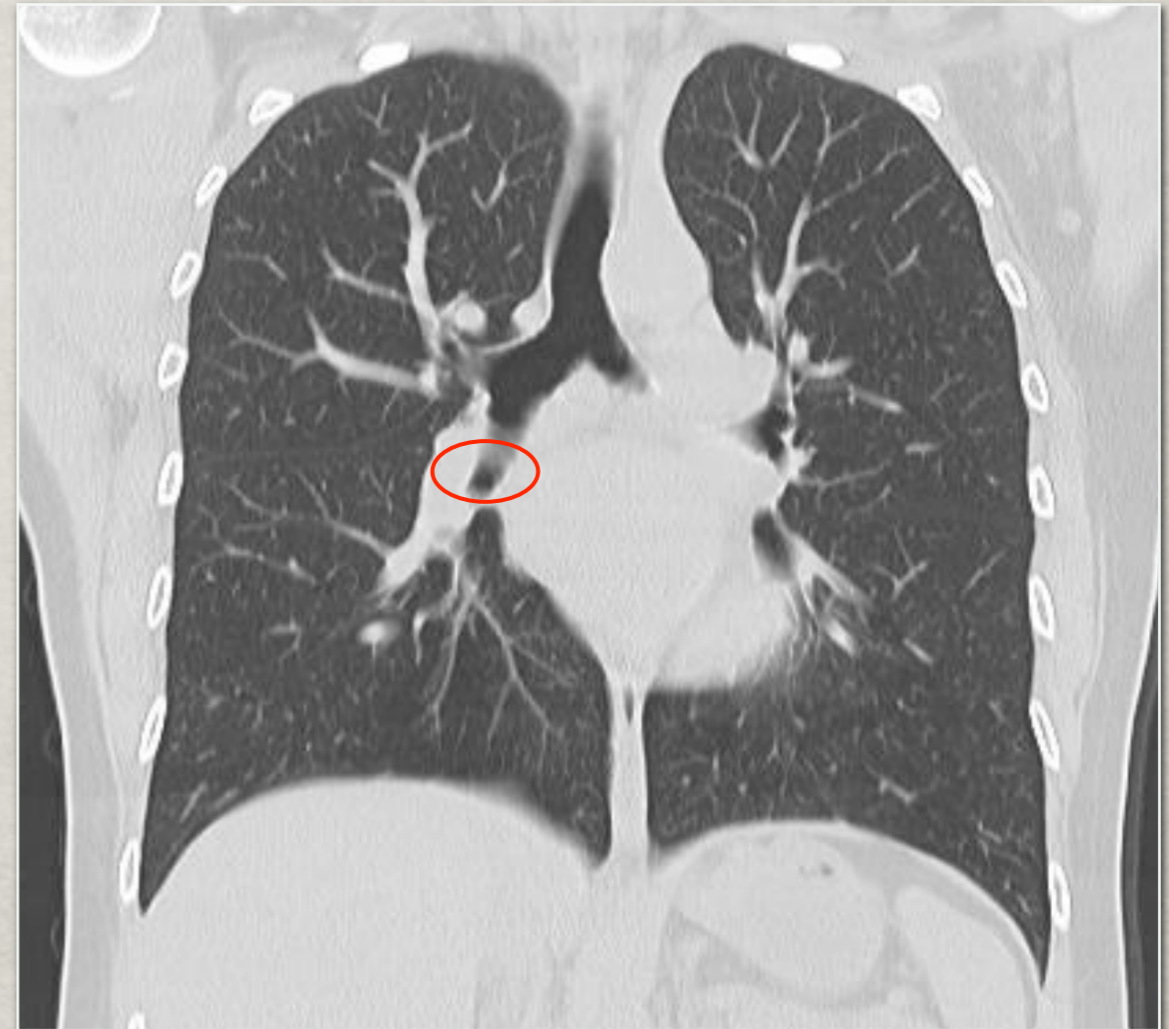




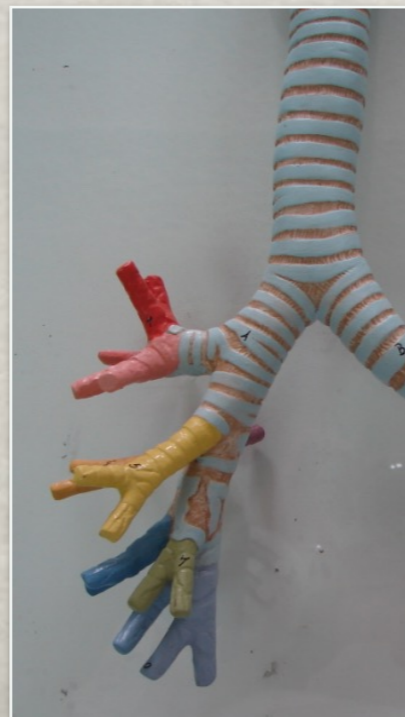ΒΡΟΓΧΟΙ ΔΕΞΙΟΥ ΠΝΕΥΜΟΝΑ



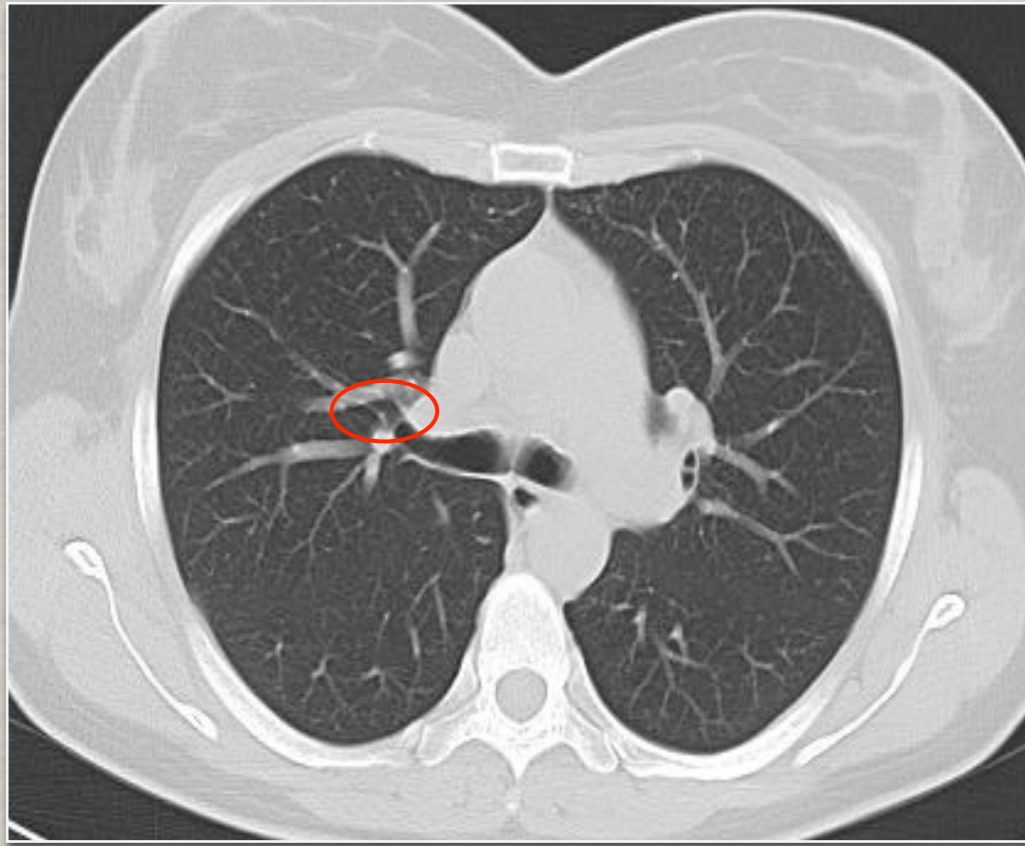
Βρόγχος άνω λοβού



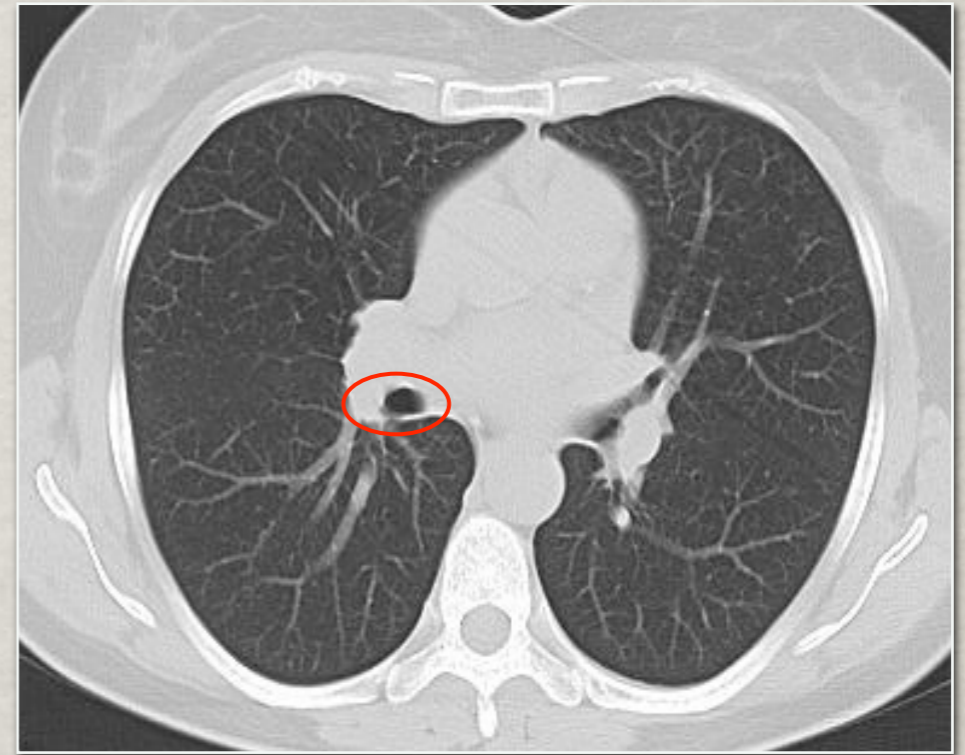
Βρόγχος κάτω λοβού



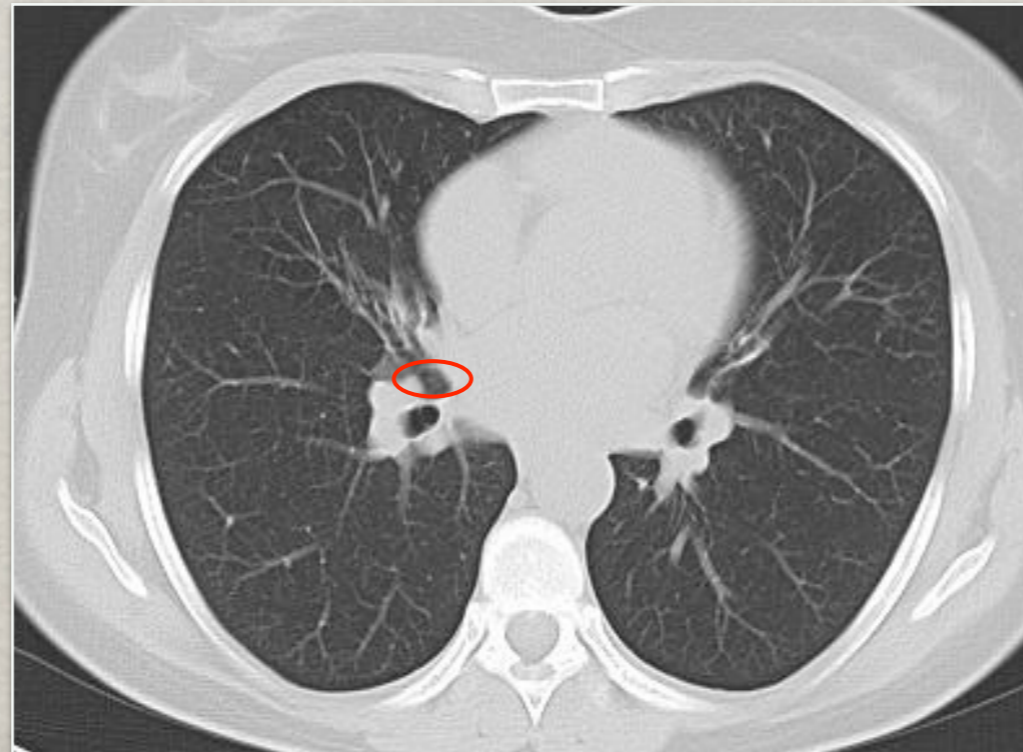
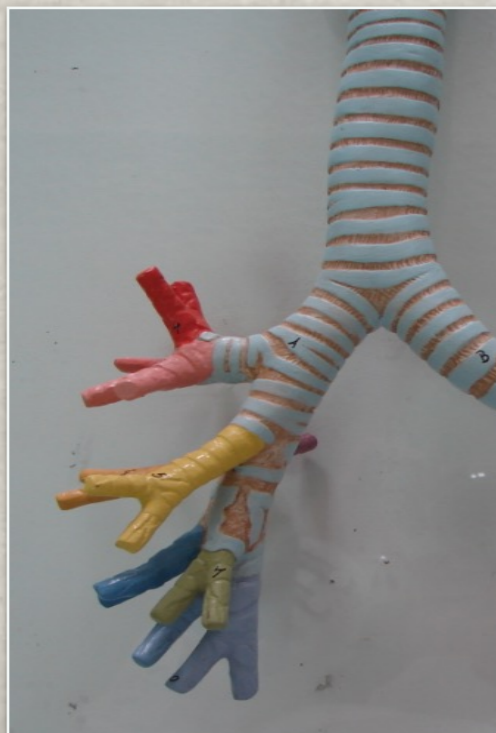
ΒΡΟΓΧΟΙ ΔΕΞΙΟΥ ΠΝΕΥΜΟΝΑ



Βρόγχος άνω λοβού

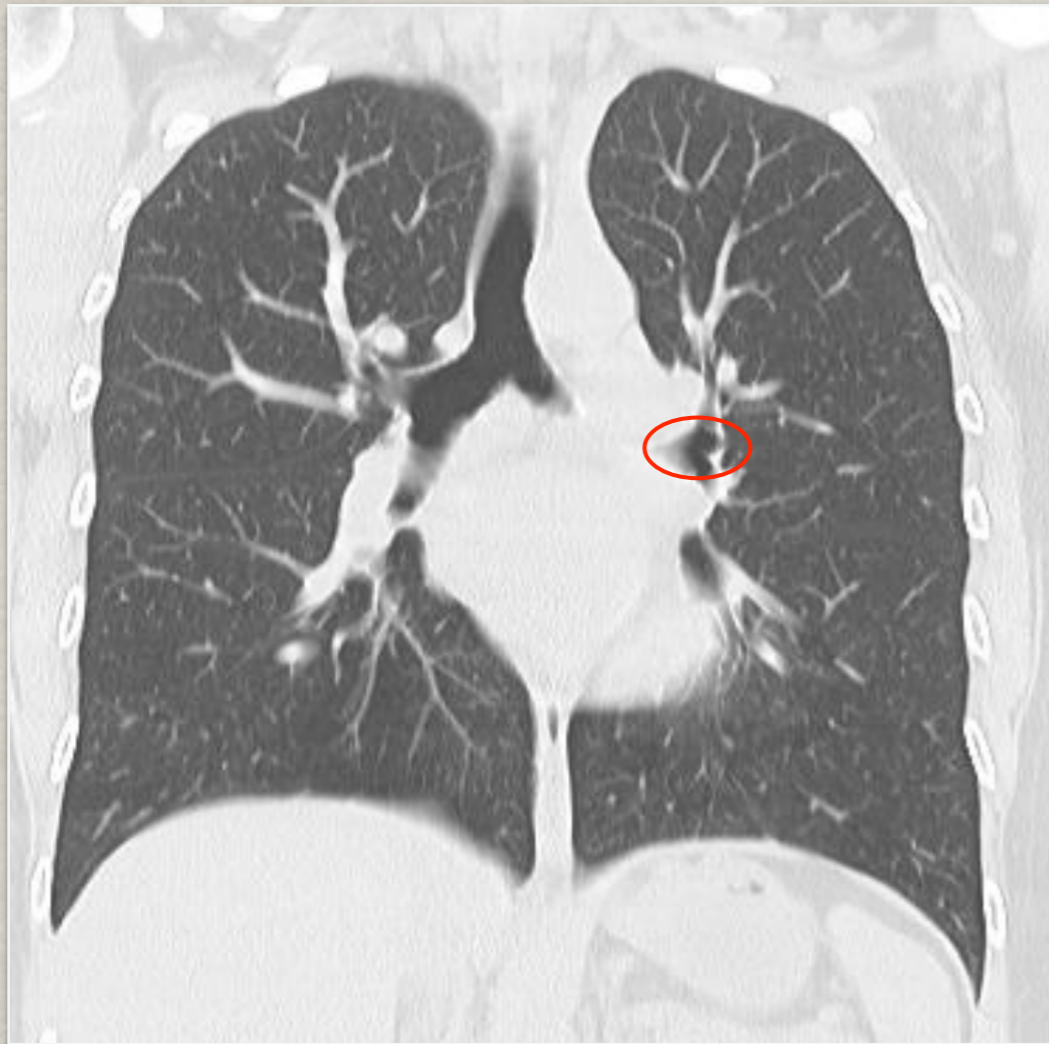


Βρόγχος κάτω λοβού

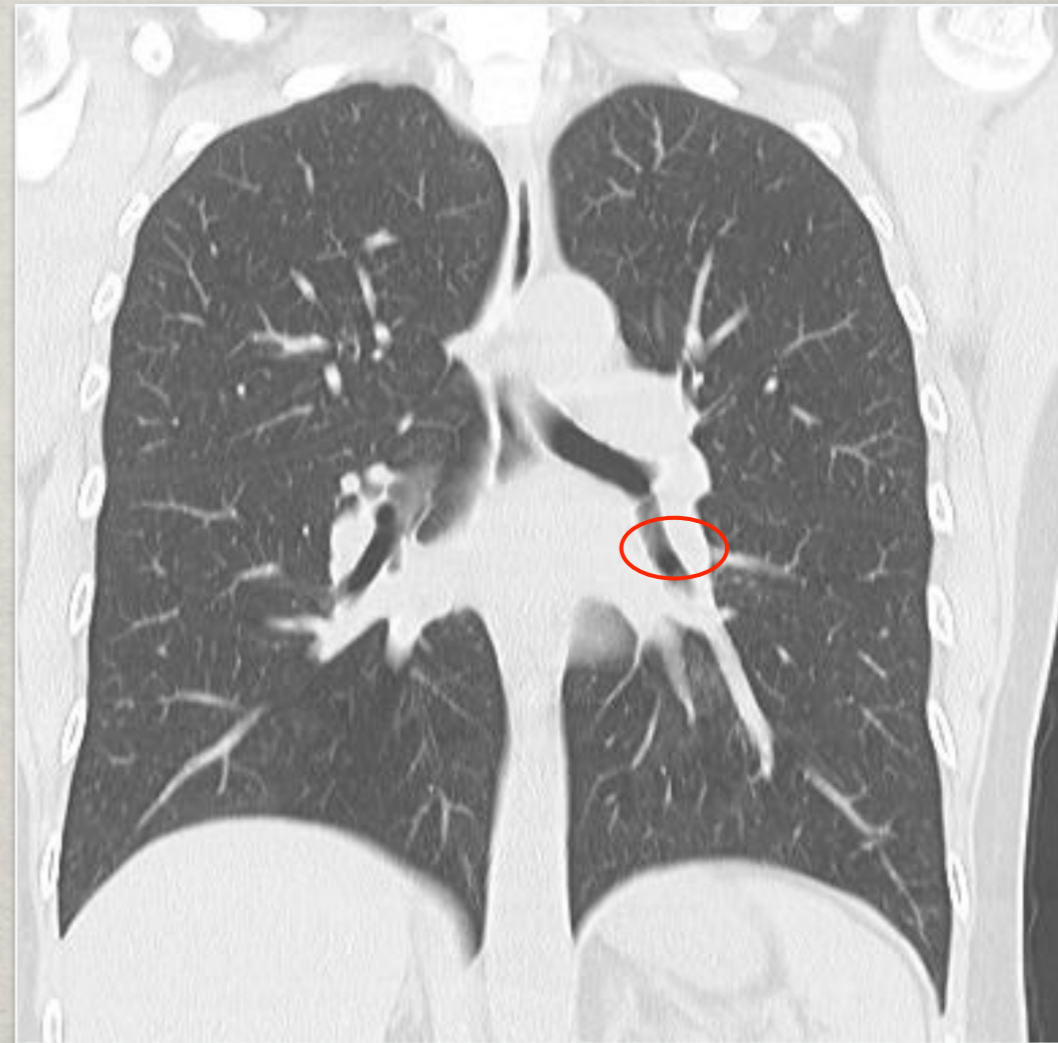


Βρόγχος μέσου λοβού

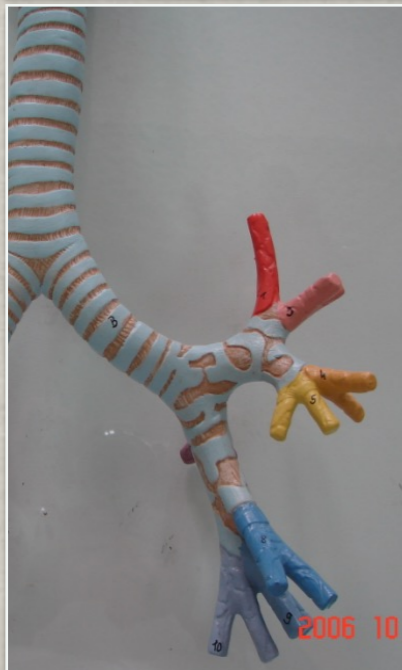
ΒΡΟΓΧΟΙ ΑΡΙΣΤΕΡΟΥ ΠΝΕΥΜΟΝΑ



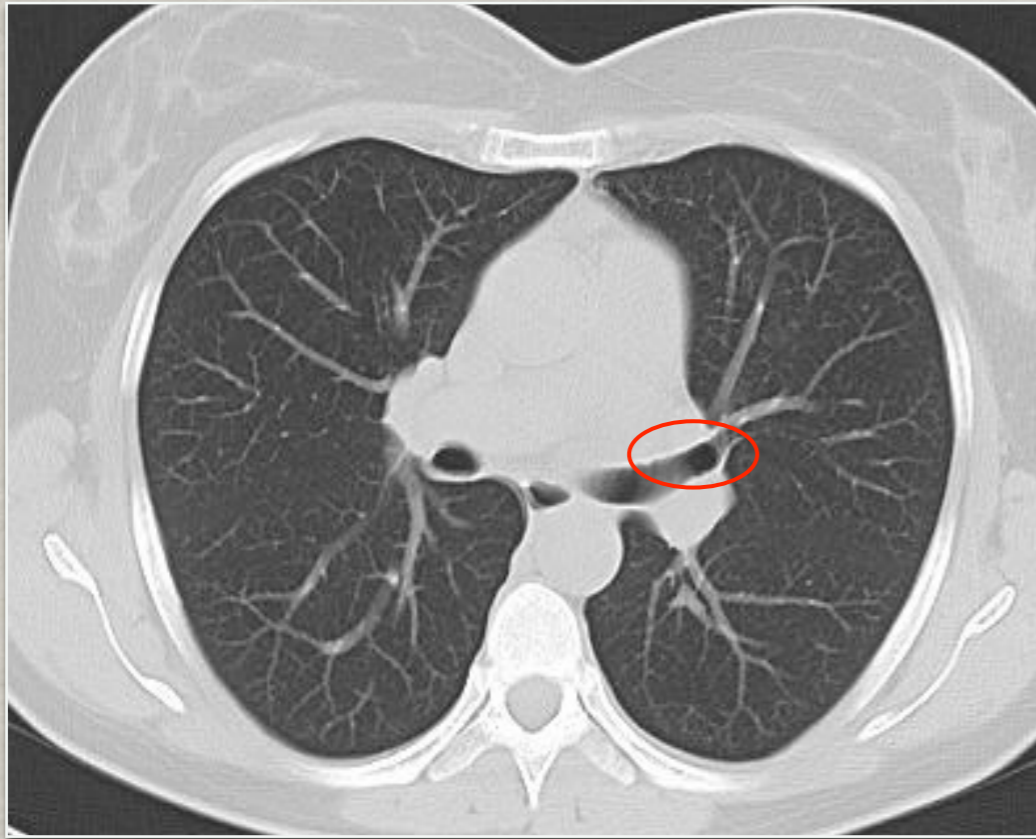
Βρόγχος άνω λοβού



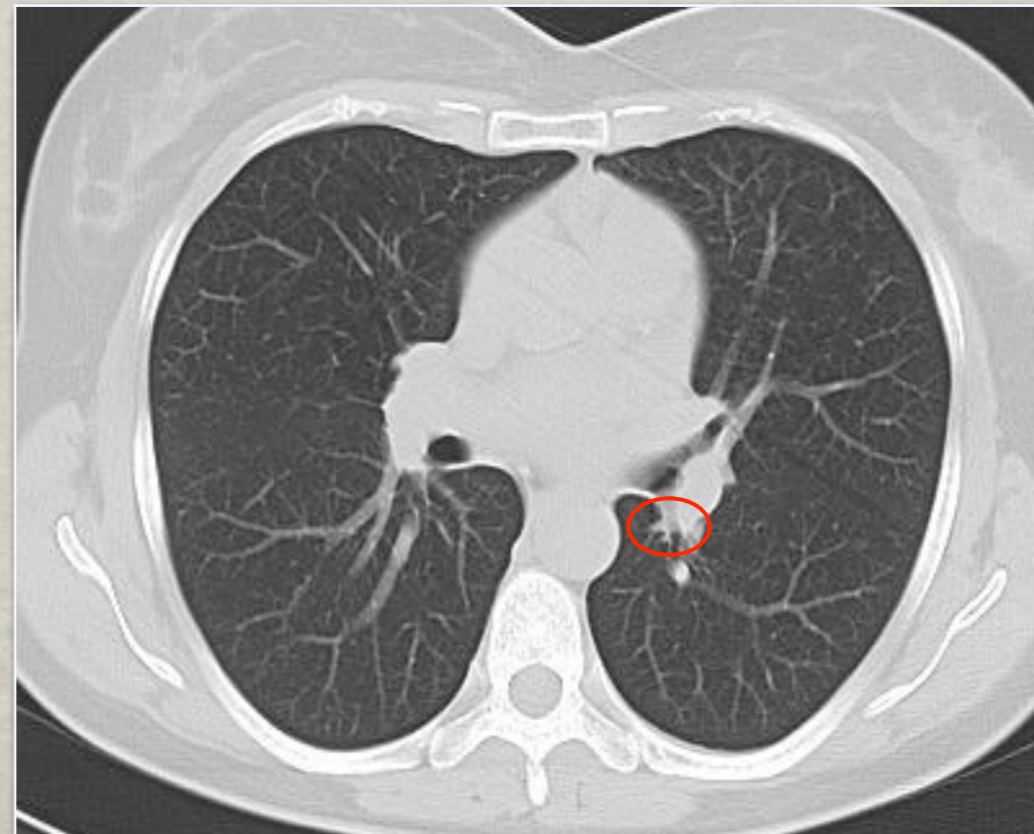
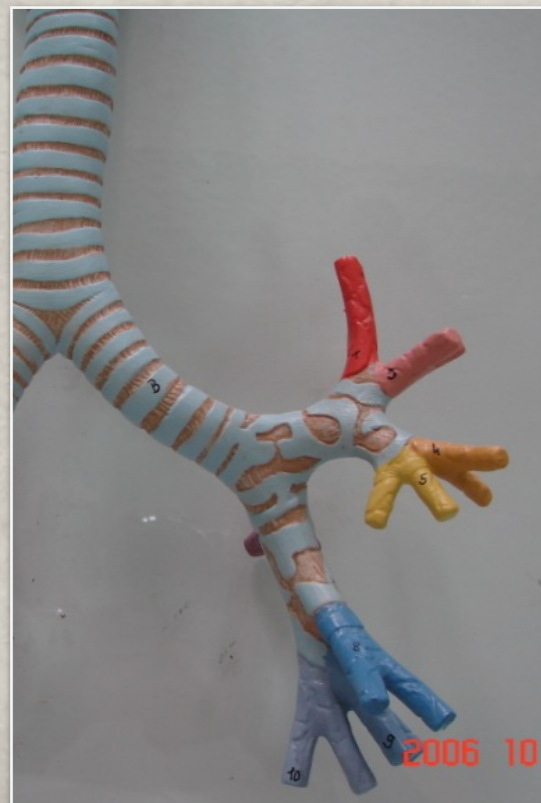
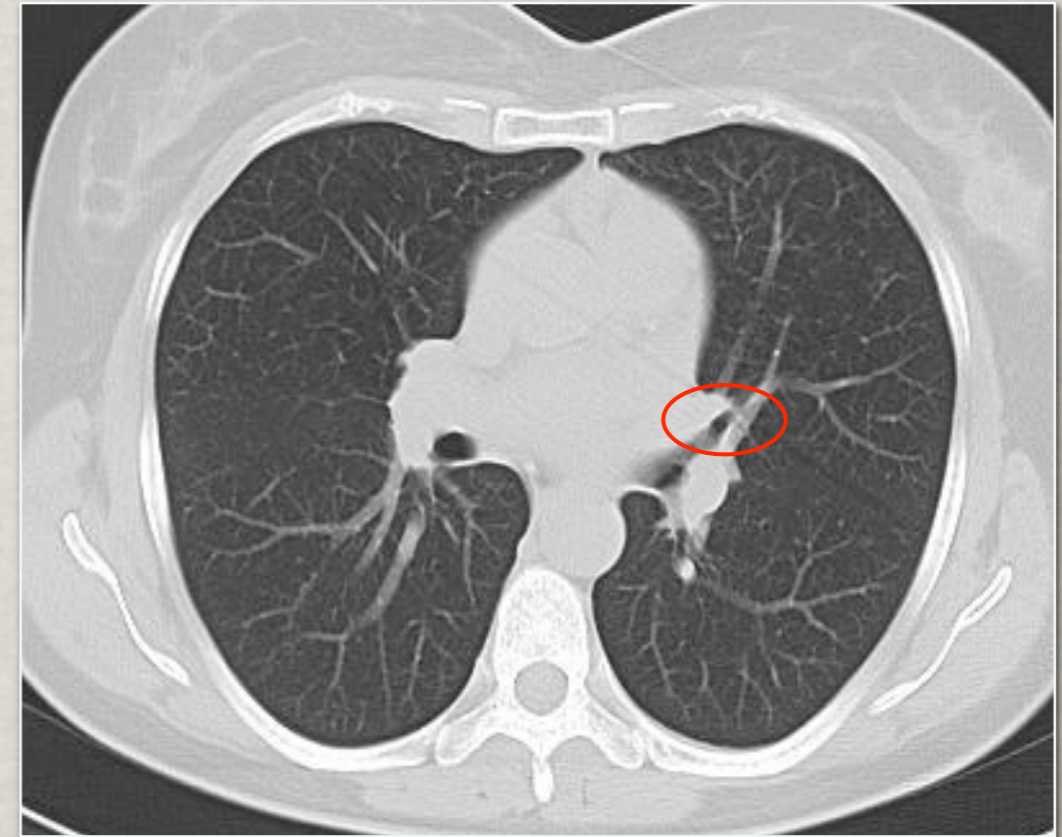
Βρόγχος κάτω λοβού



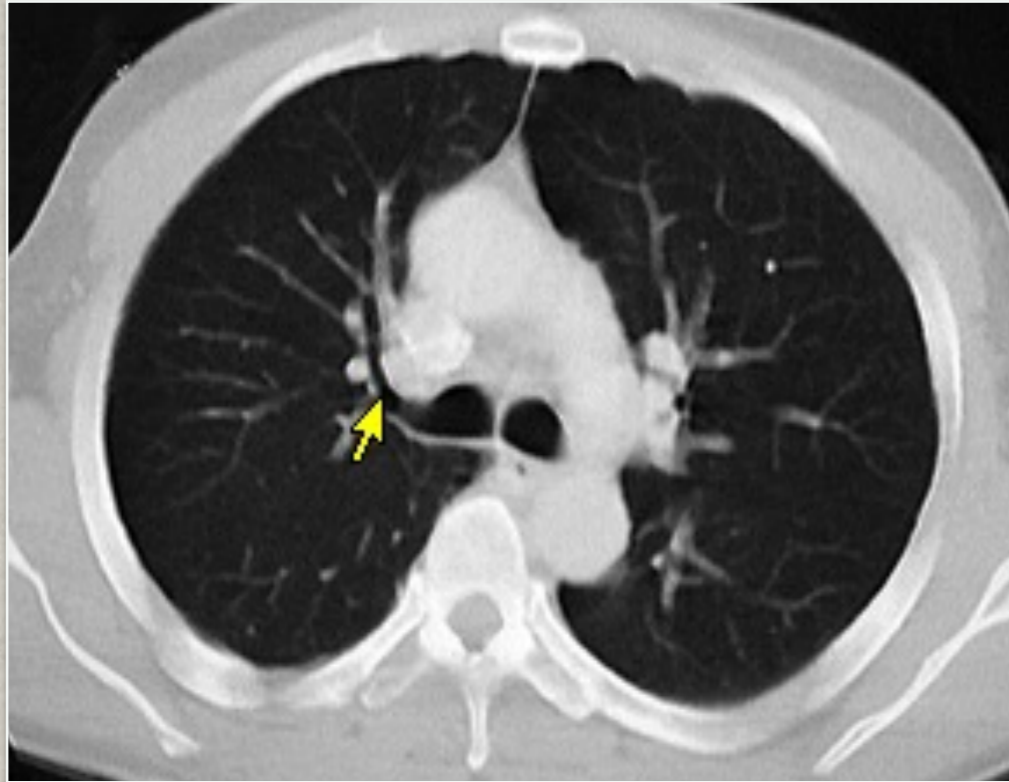
ΒΡΟΓΧΟΙ ΑΡΙΣΤΕΡΟΥ ΠΝΕΥΜΟΝΑ



Βρόγχος άνω λοβού

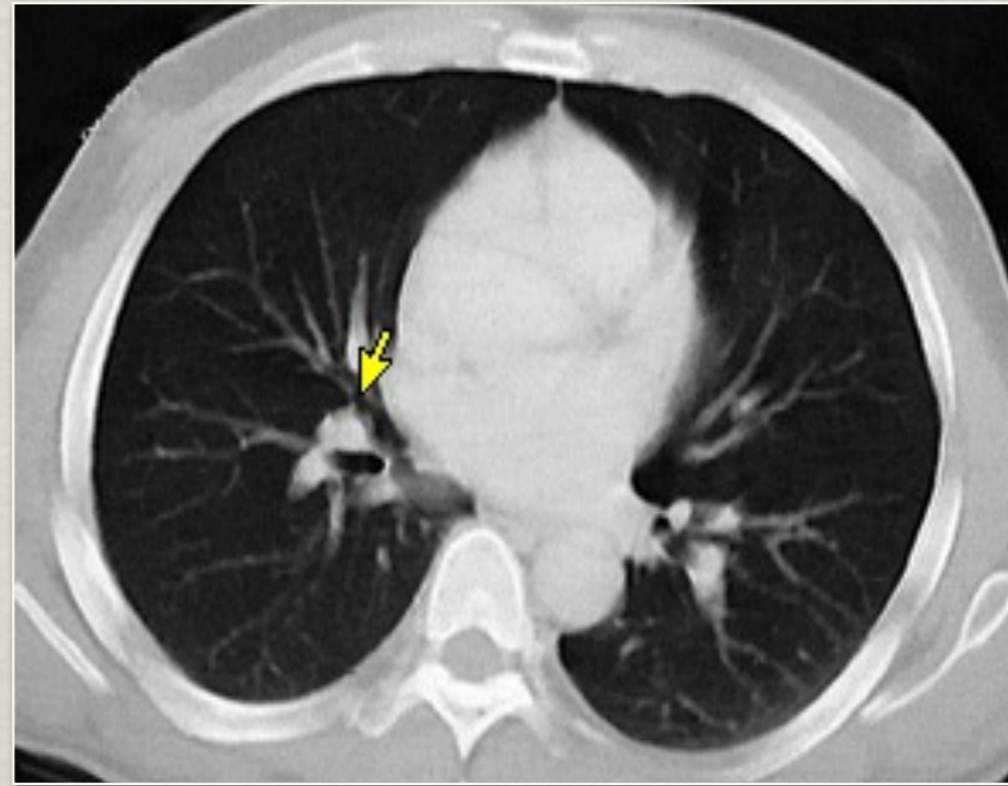


Βρόγχος κάτω λοβού



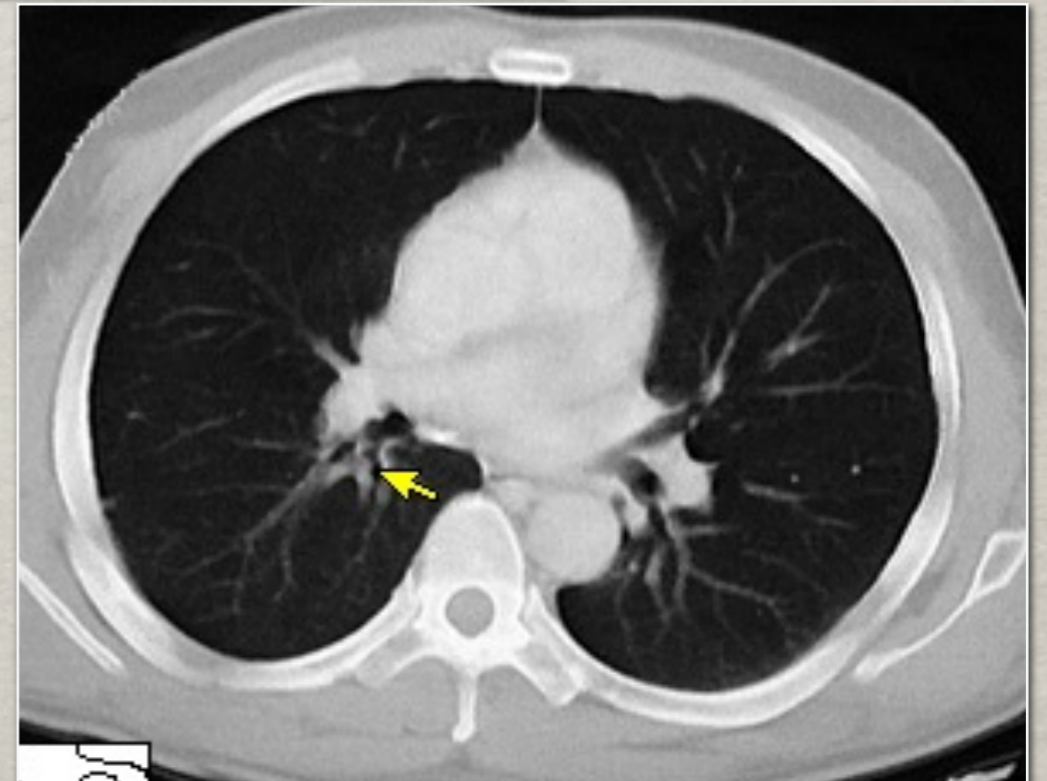
Βρόγχος άνω λοβού

Βρόγχος μέσου λοβού

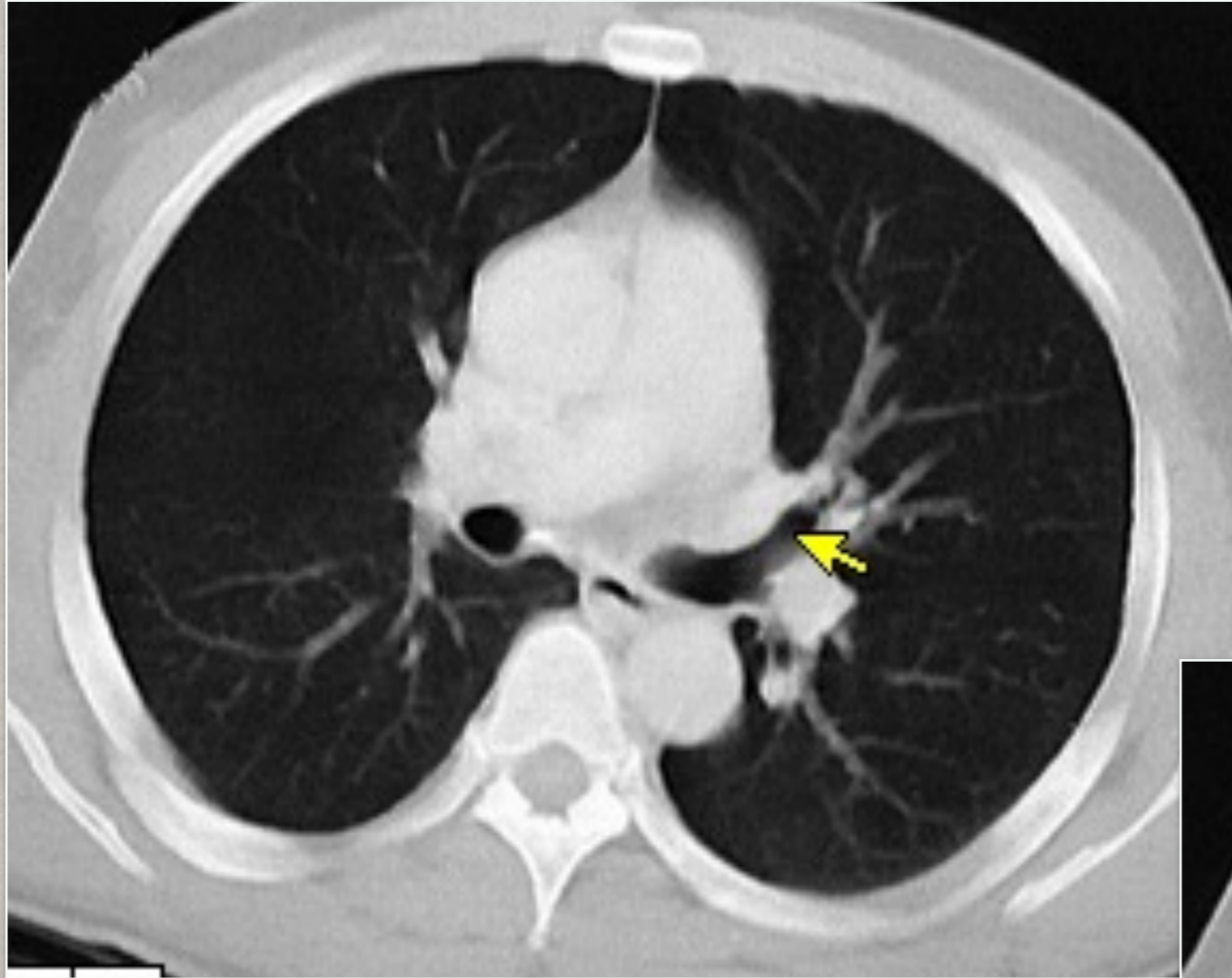


ΒΡΟΓΧΟΙ ΔΕΞΙΟΥ ΠΝΕΥΜΟΝΑ

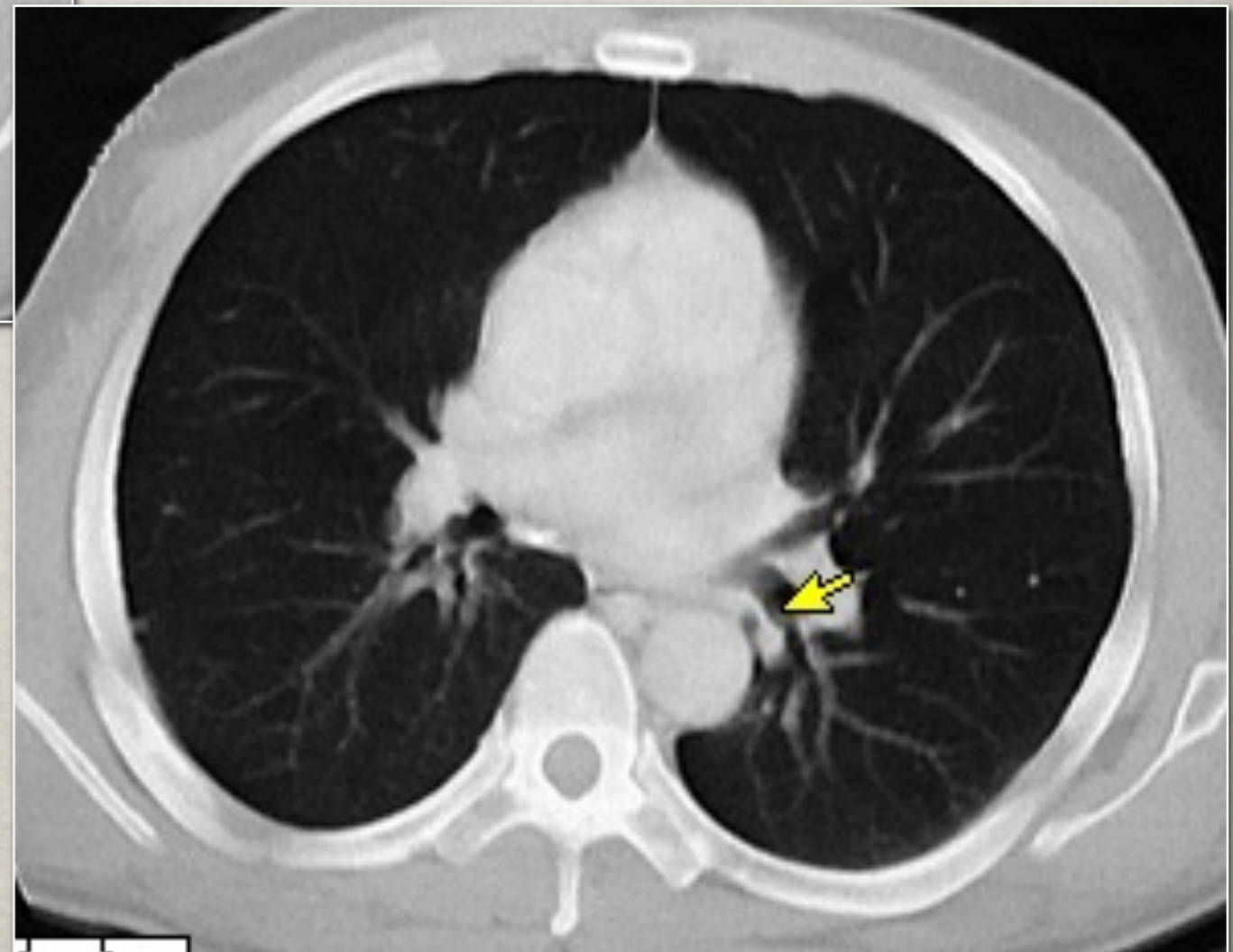
Βρόγχος κάτω λοβού



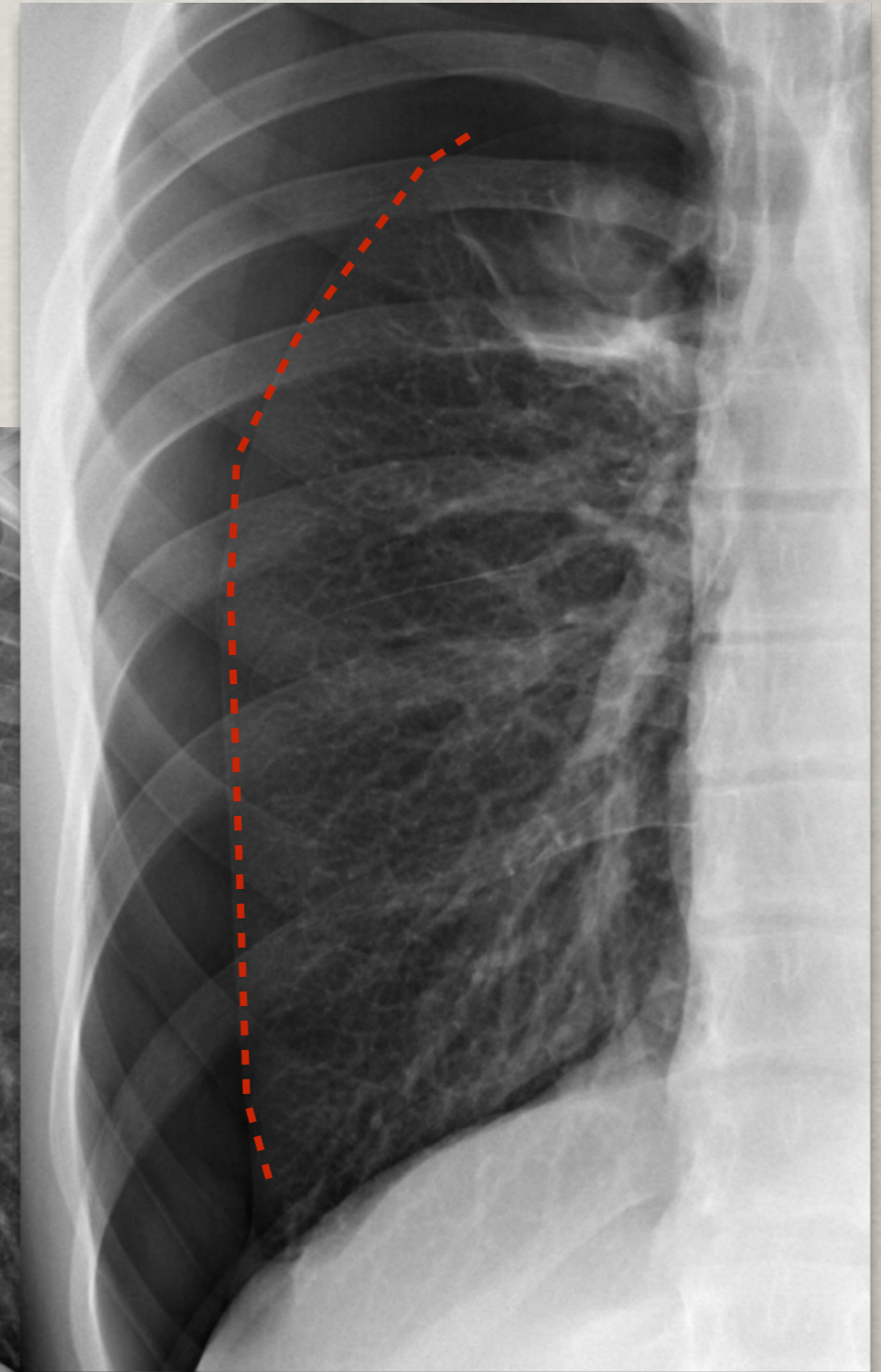
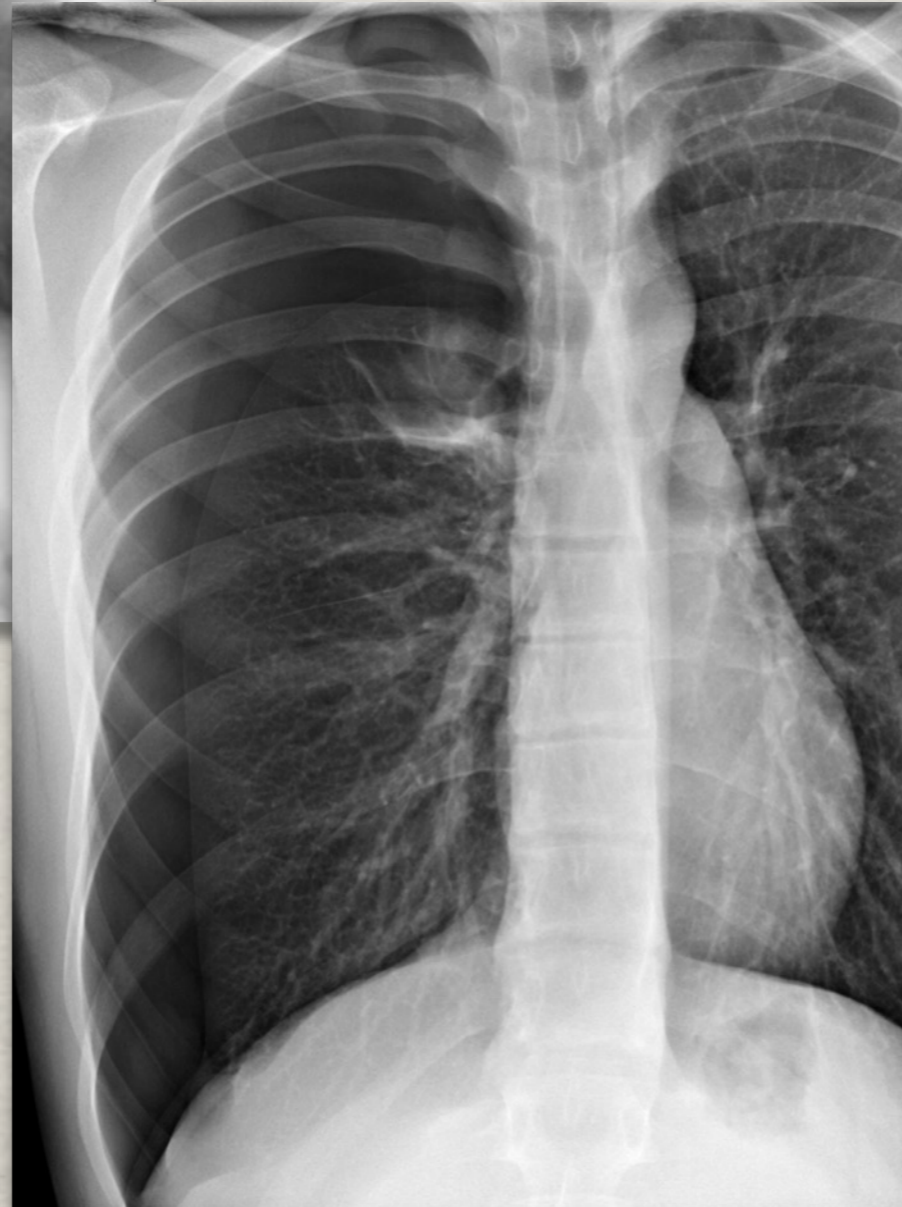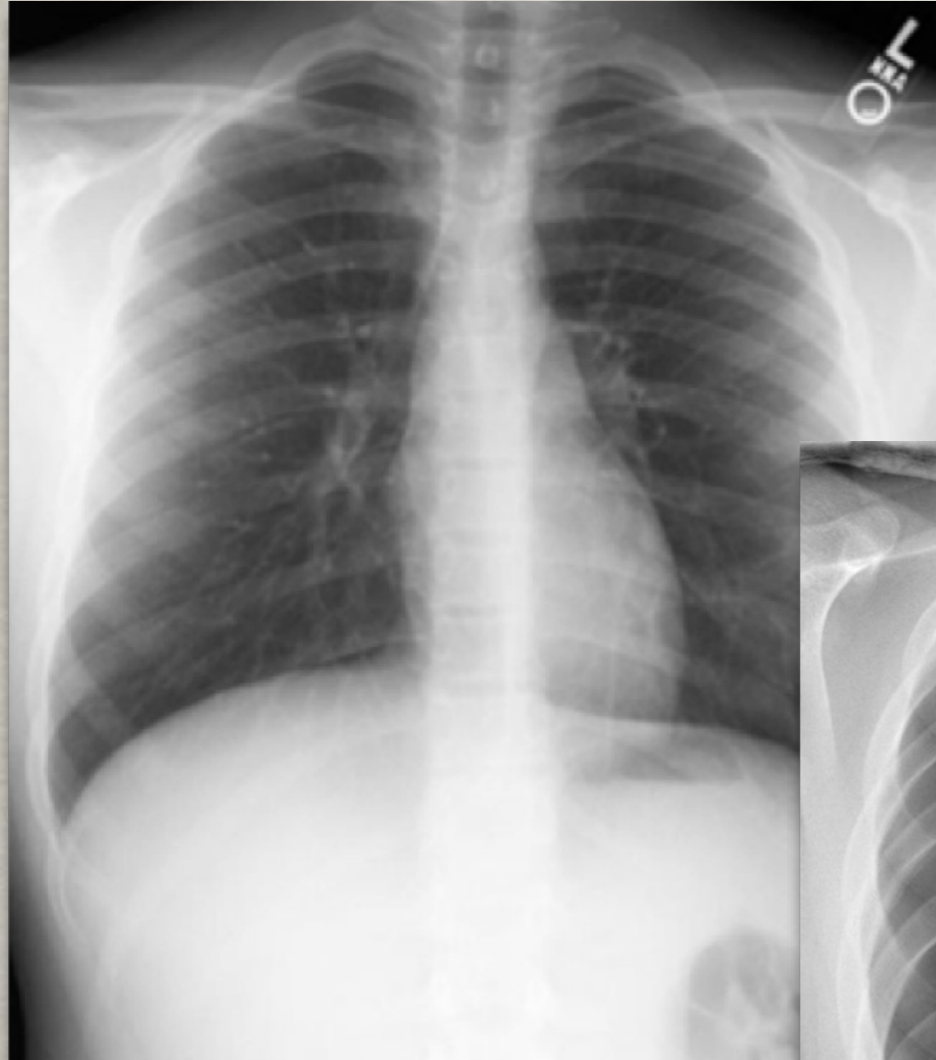
ΒΡΟΓΧΟΙ ΑΡΙΣΤΕΡΟΥ ΠΝΕΥΜΟΝΑ



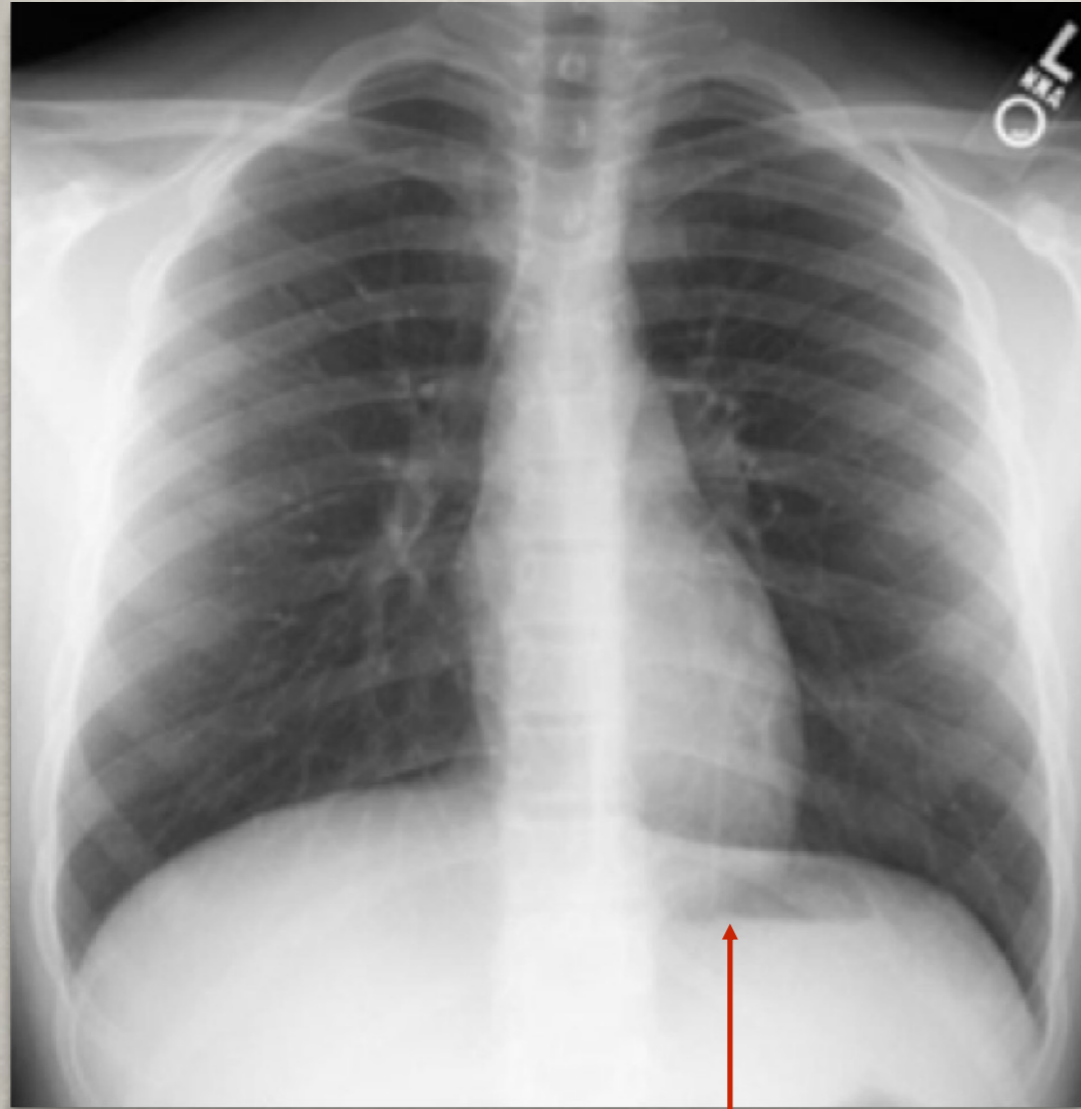Βρόγχος άνω λοβού



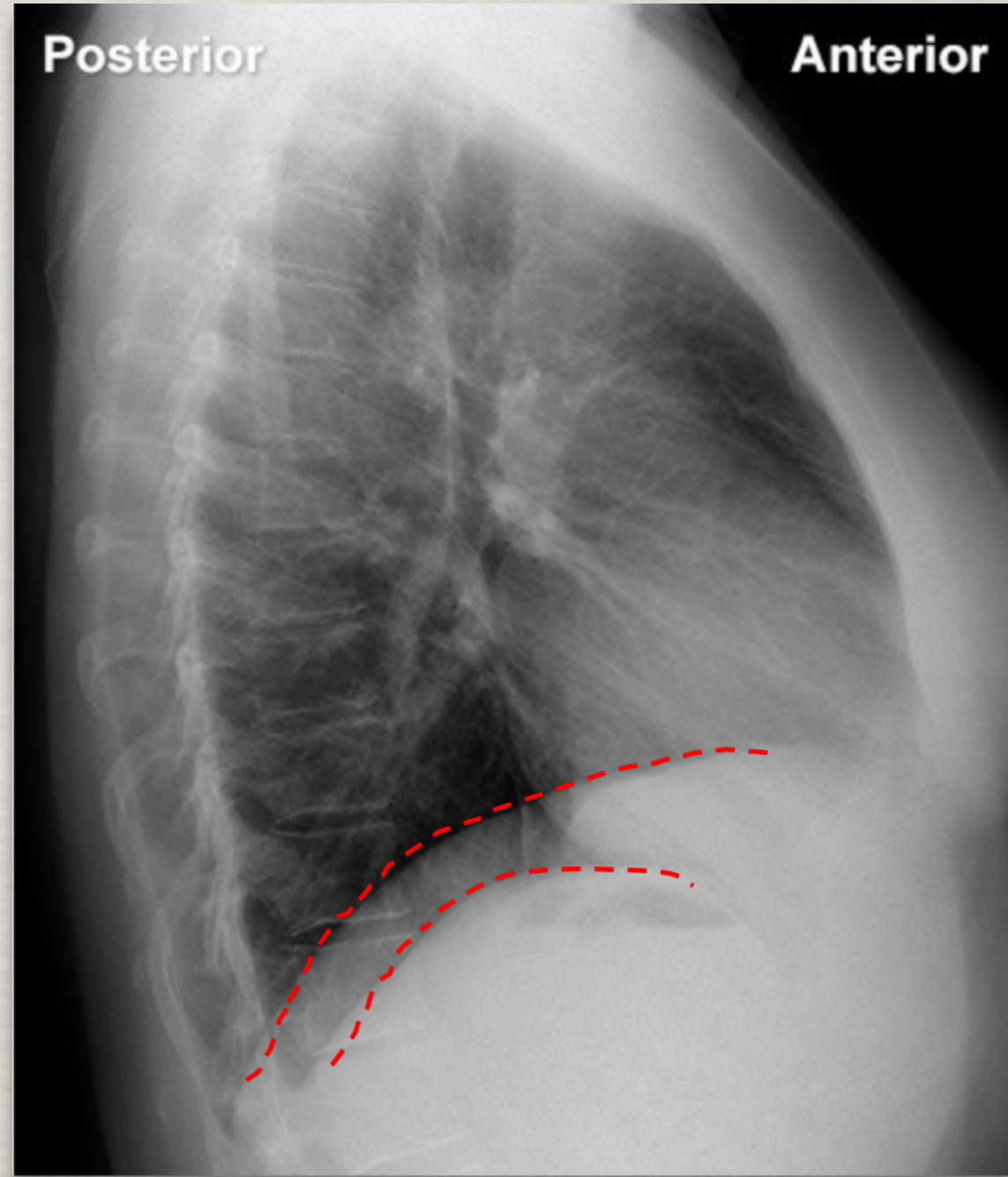
Βρόγχος κάτω λοβού



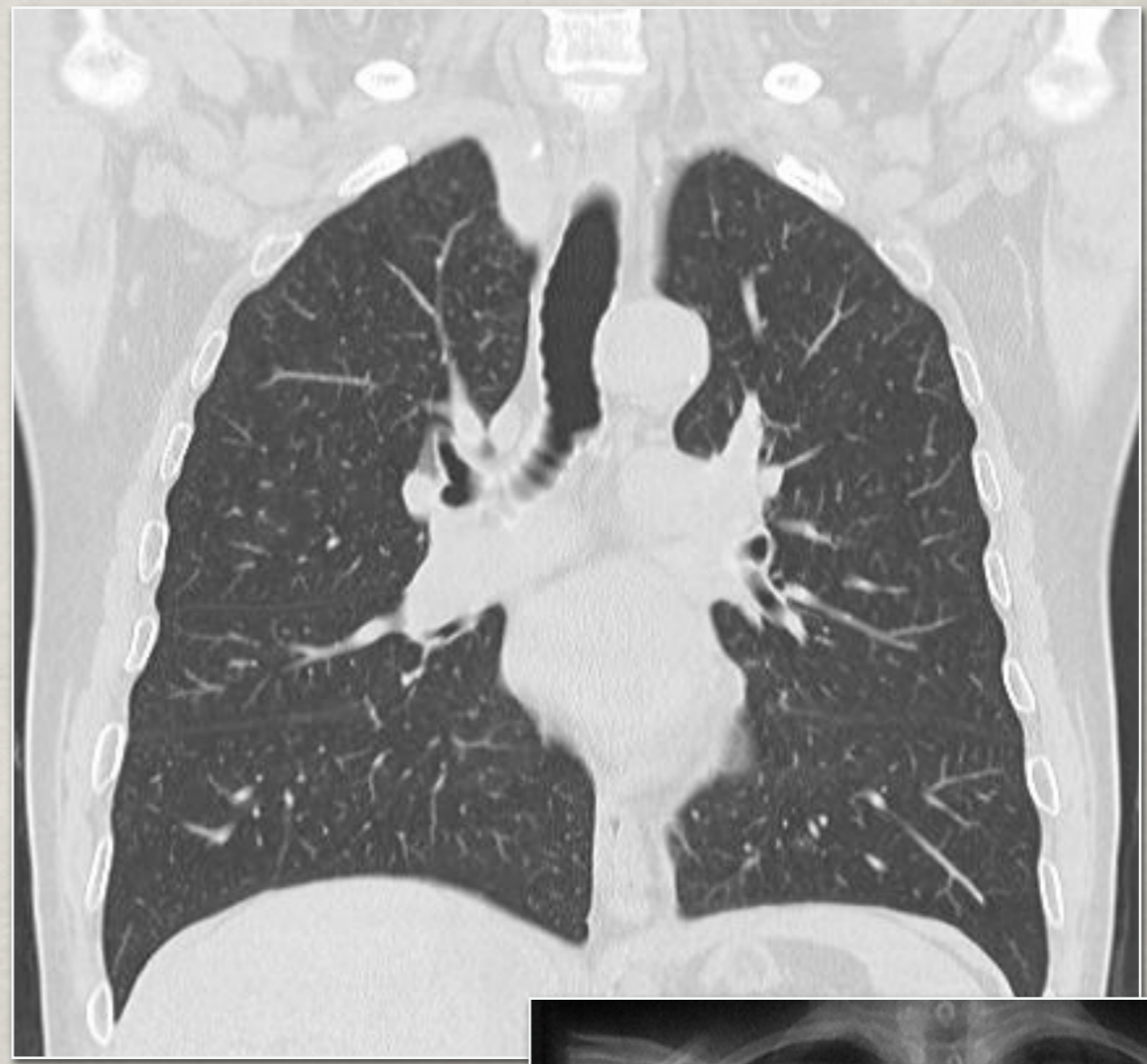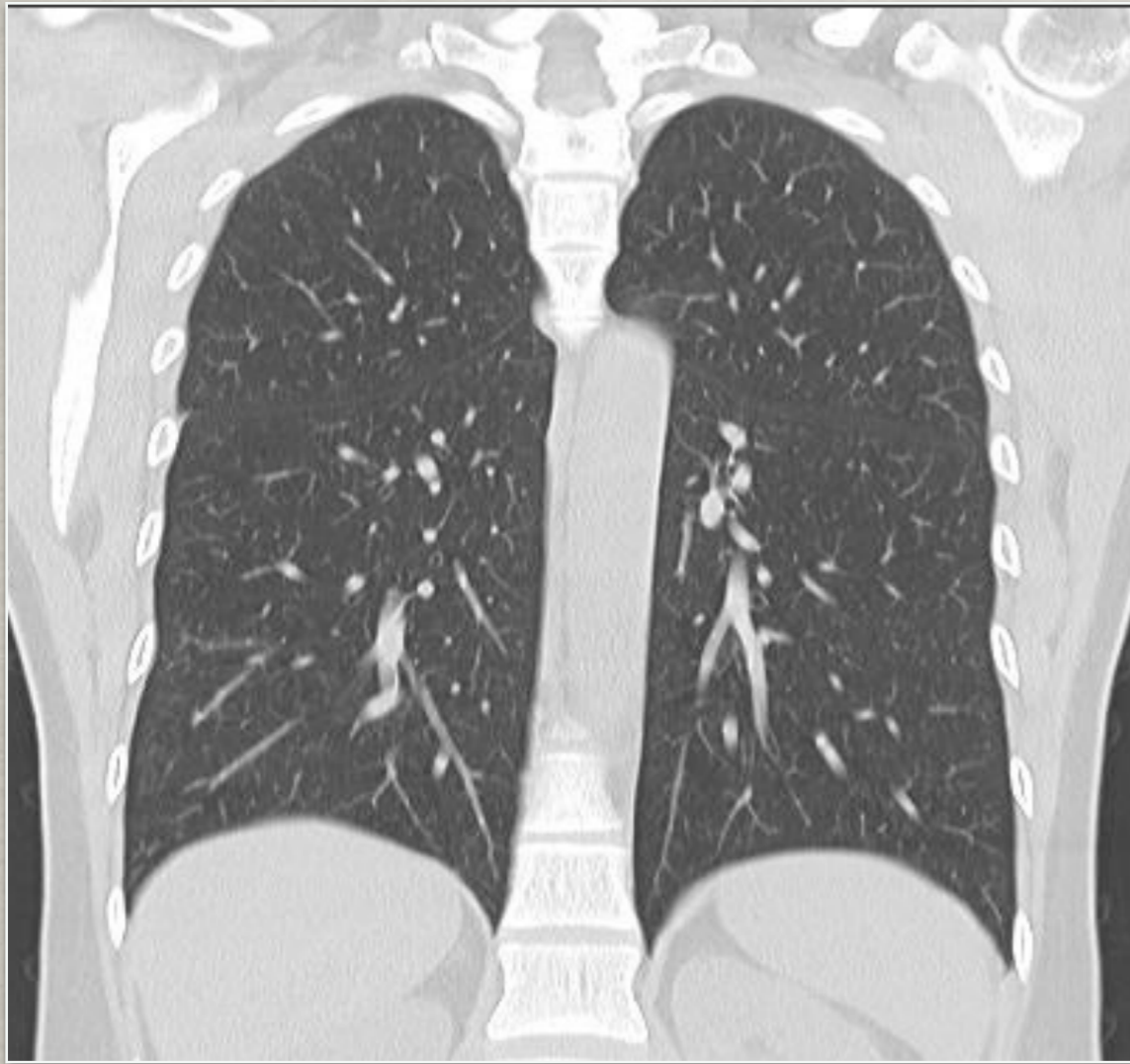ΥΠΕΡΩΚΟΤΑΣ



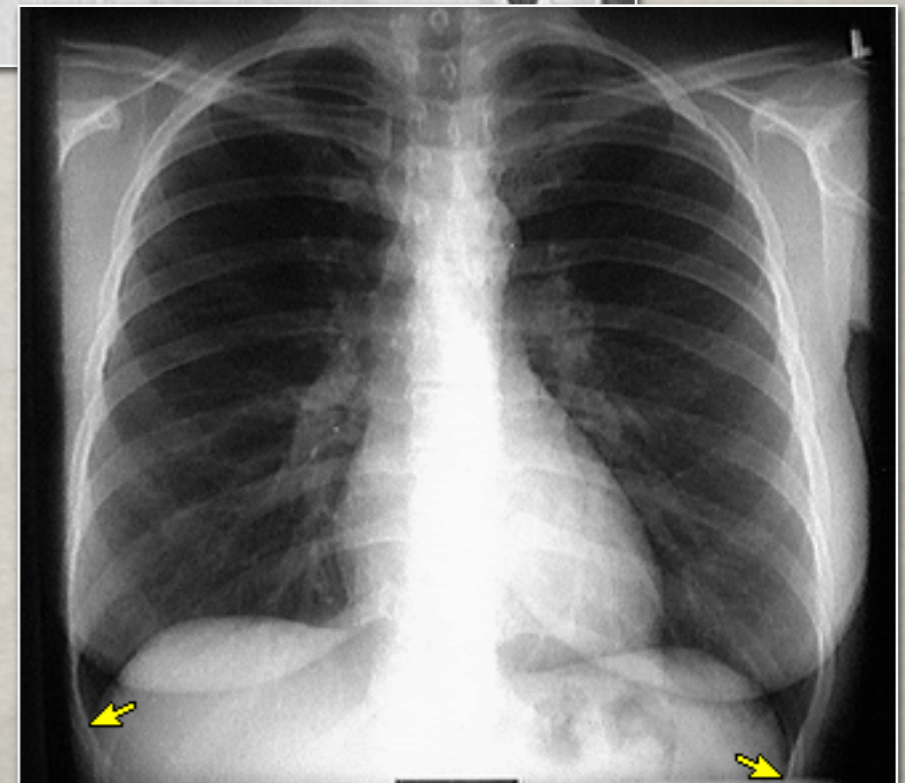
Γαστρική φυσαλίδα

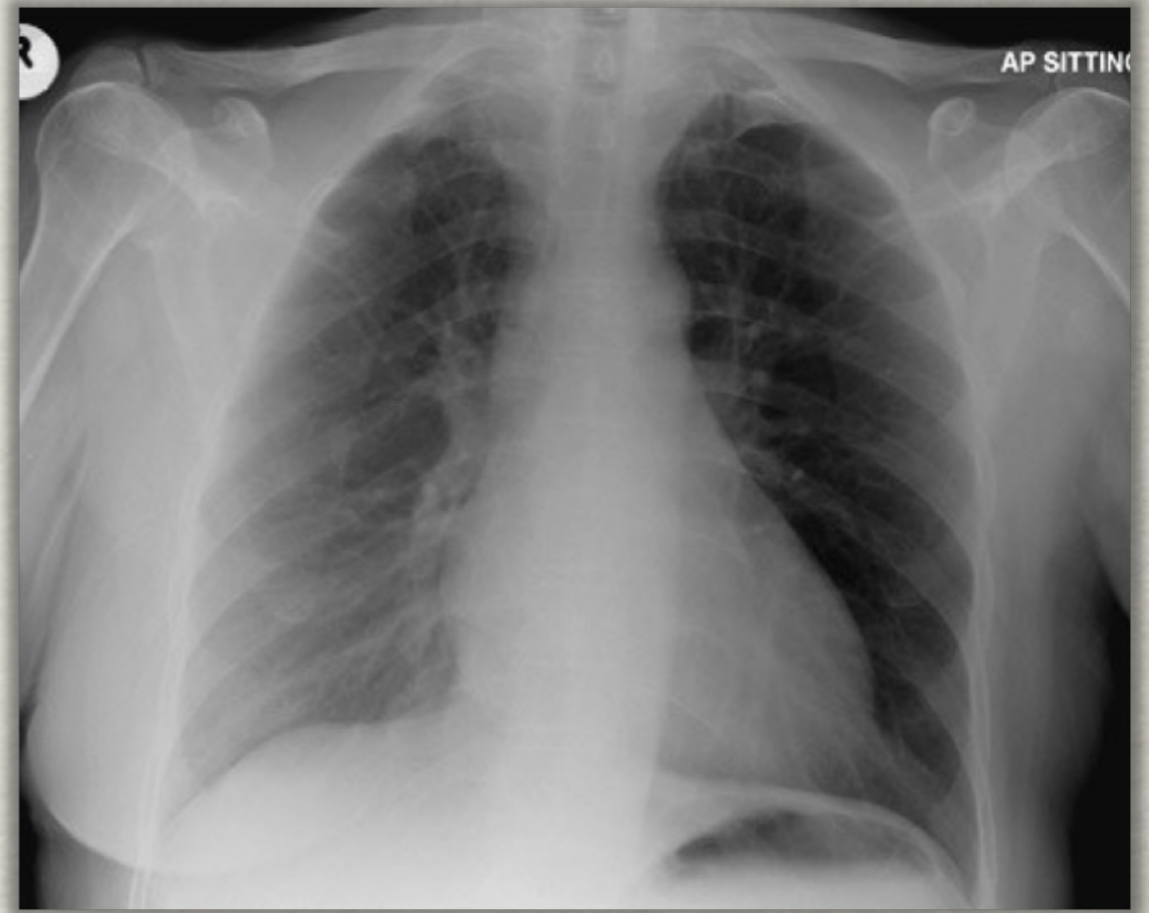
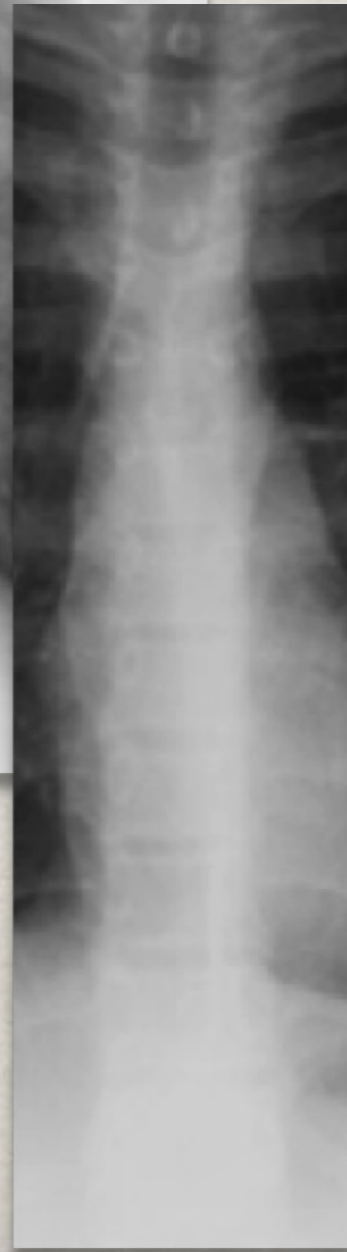
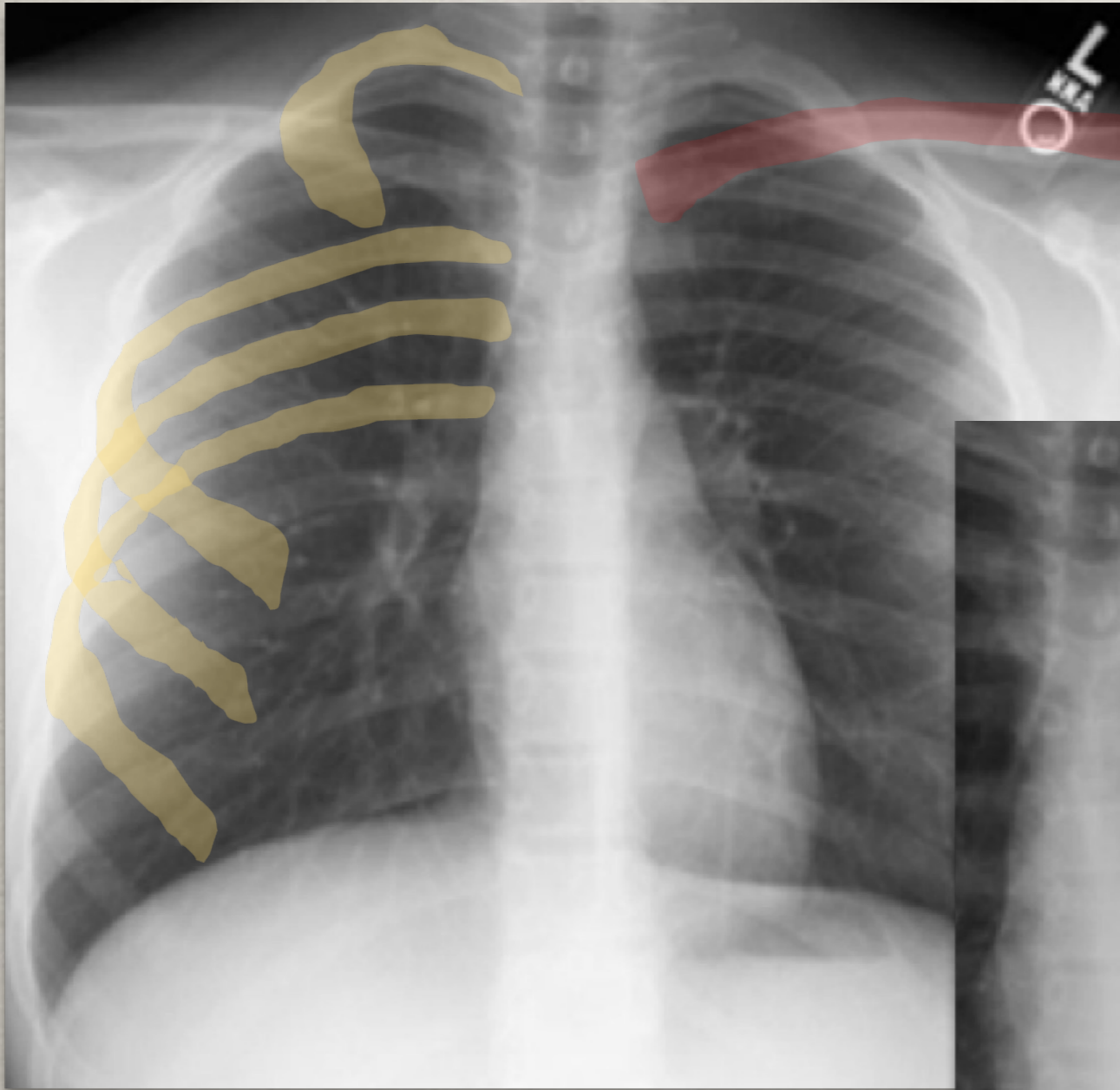


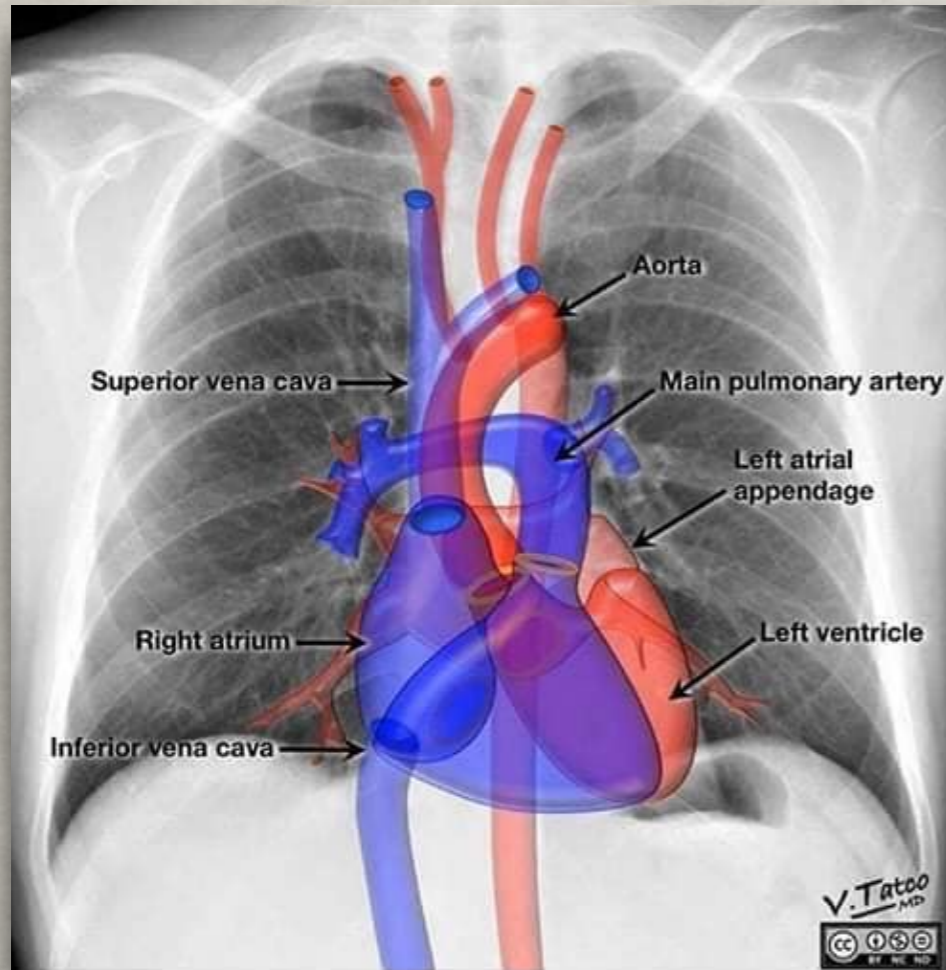
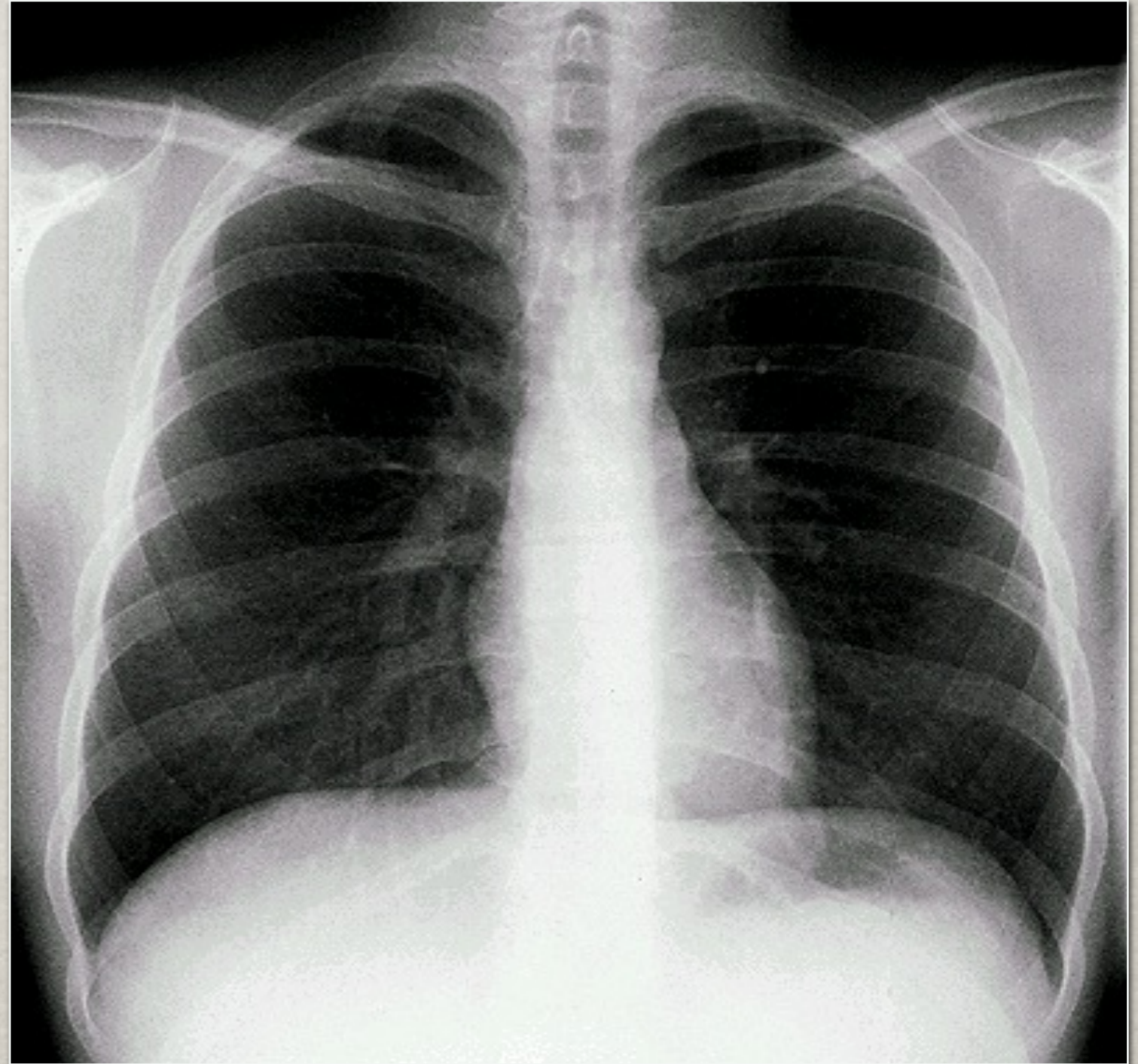
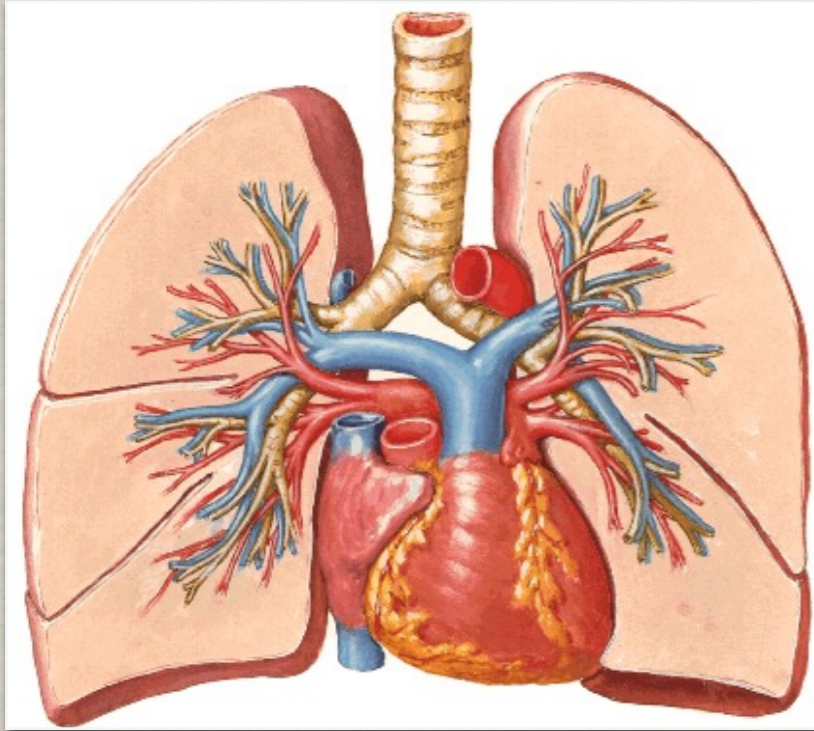
ΔΙΑΦΡΑΓΜΑ



Πλευροδιαφραγματικές γωνίες

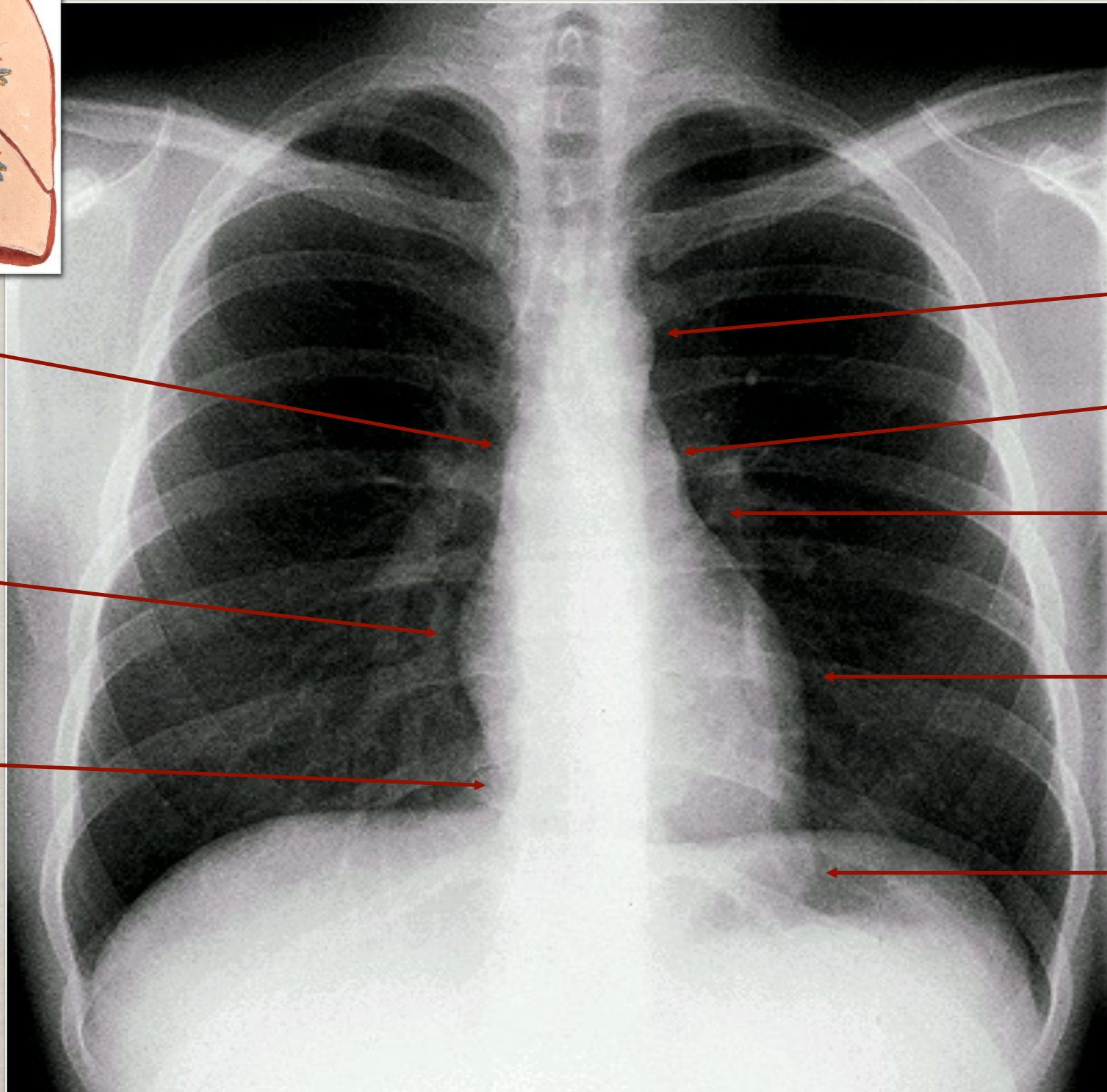
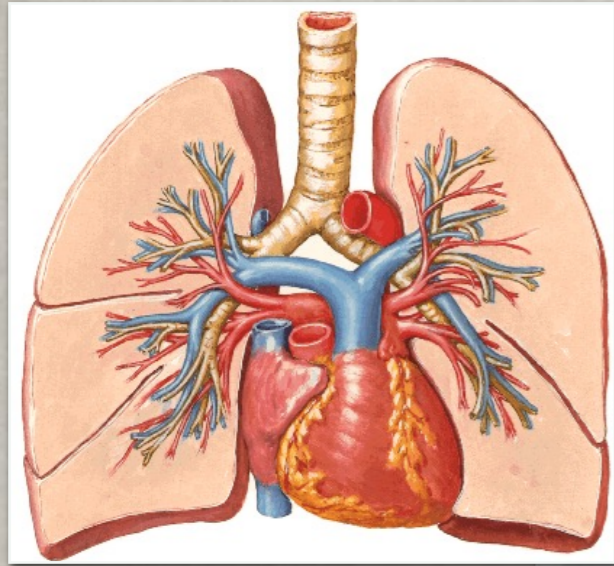






ΘΩΡΑΚΑΣ

ΚΑΡΔΙΑ



Άνω κοίλη φλ.

Δεξιός κόλπος

Κάτω κοίλη

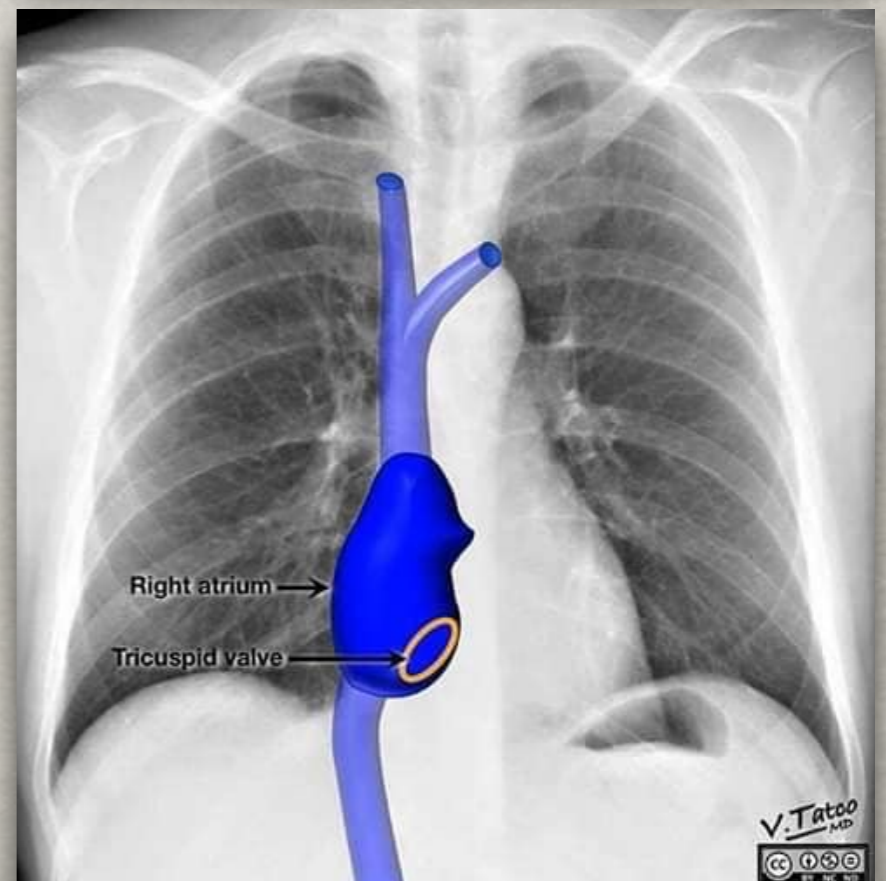
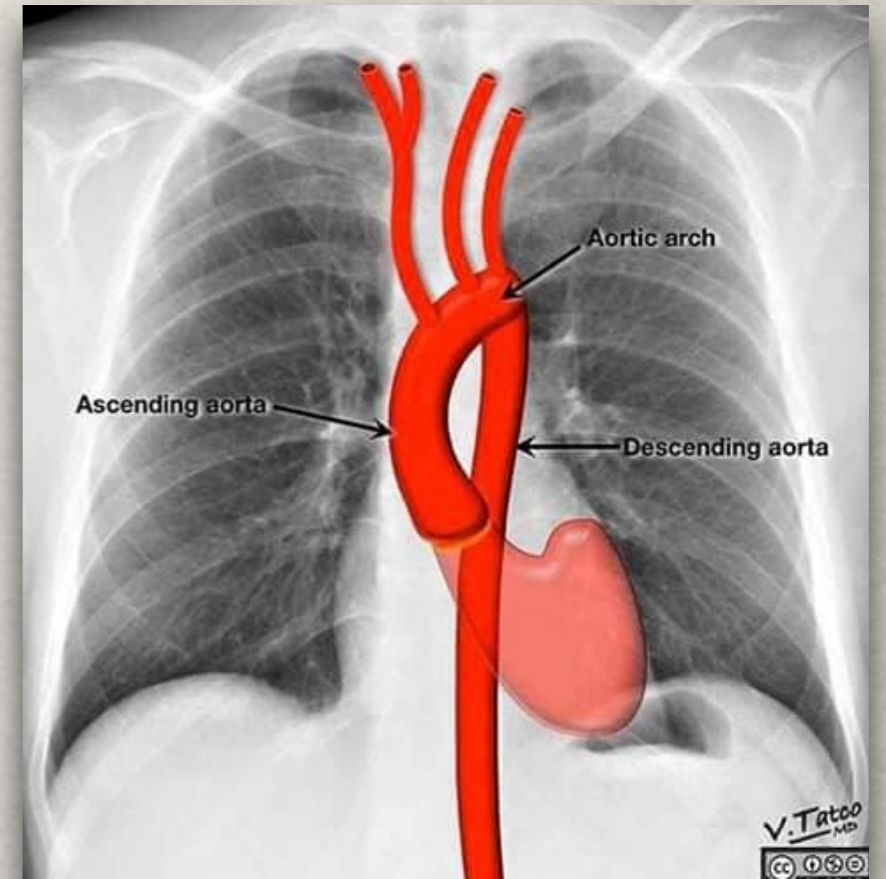
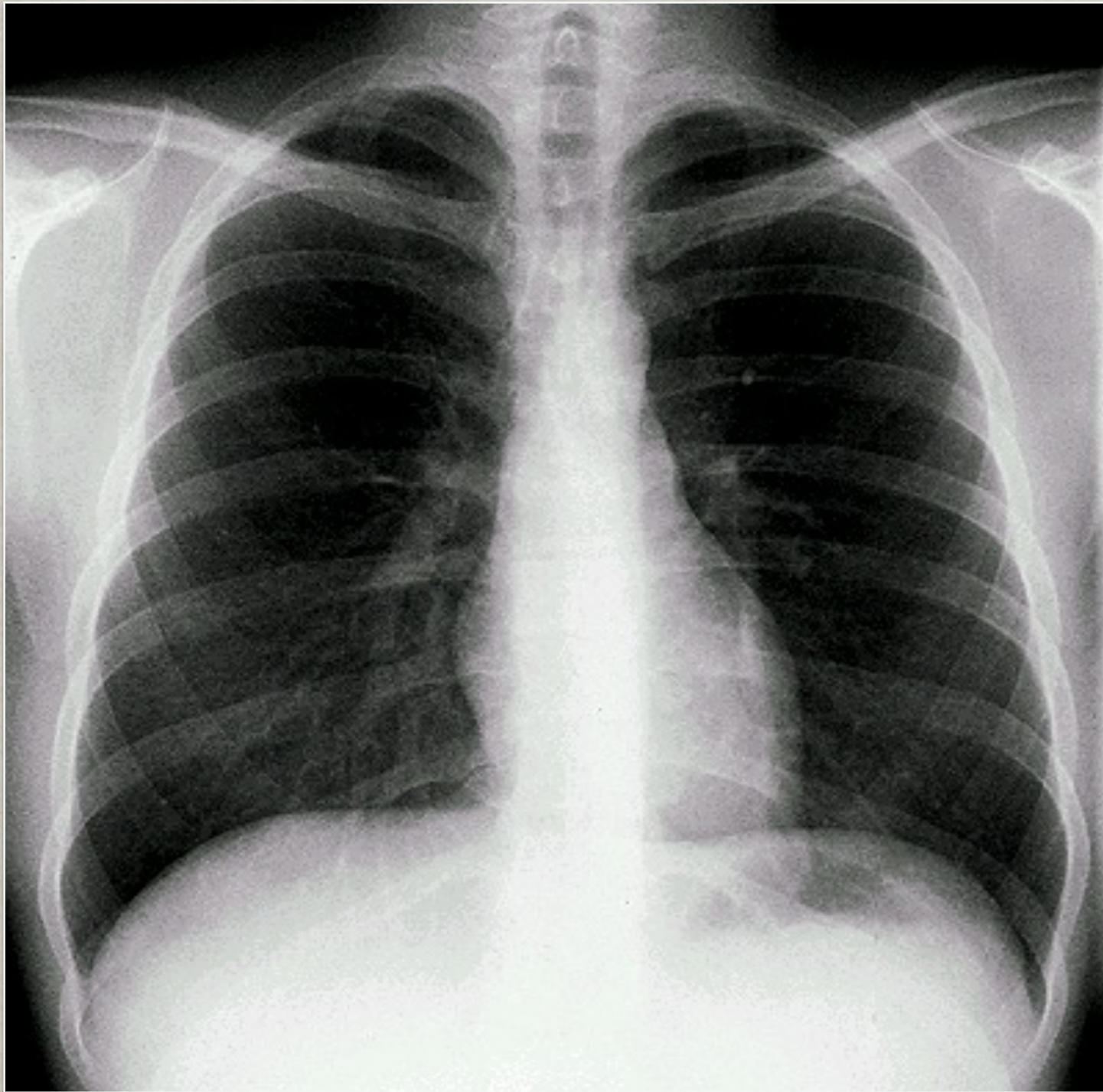
Αορτή

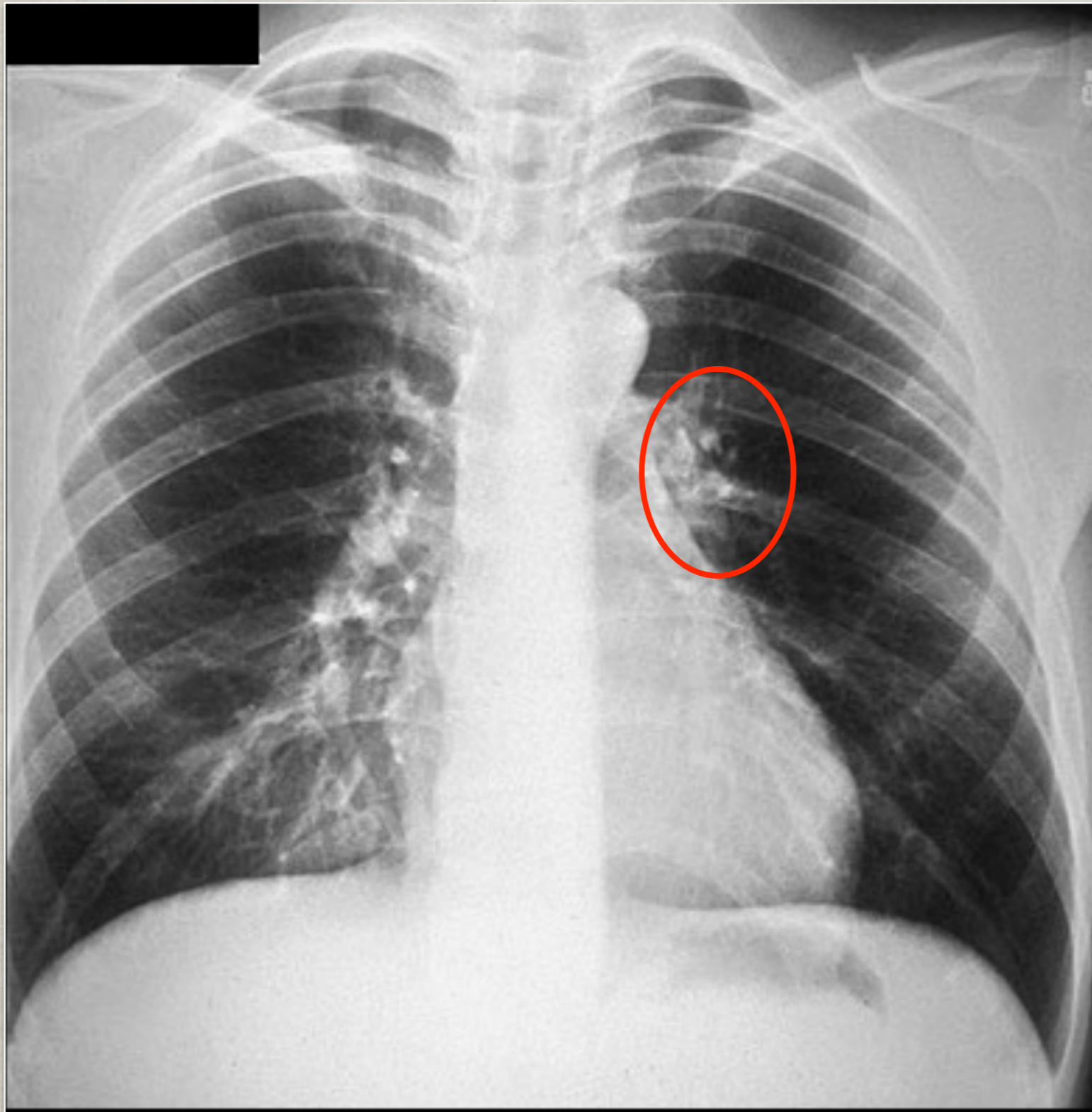
Κορμός
πνευμονικής

Ωτίο

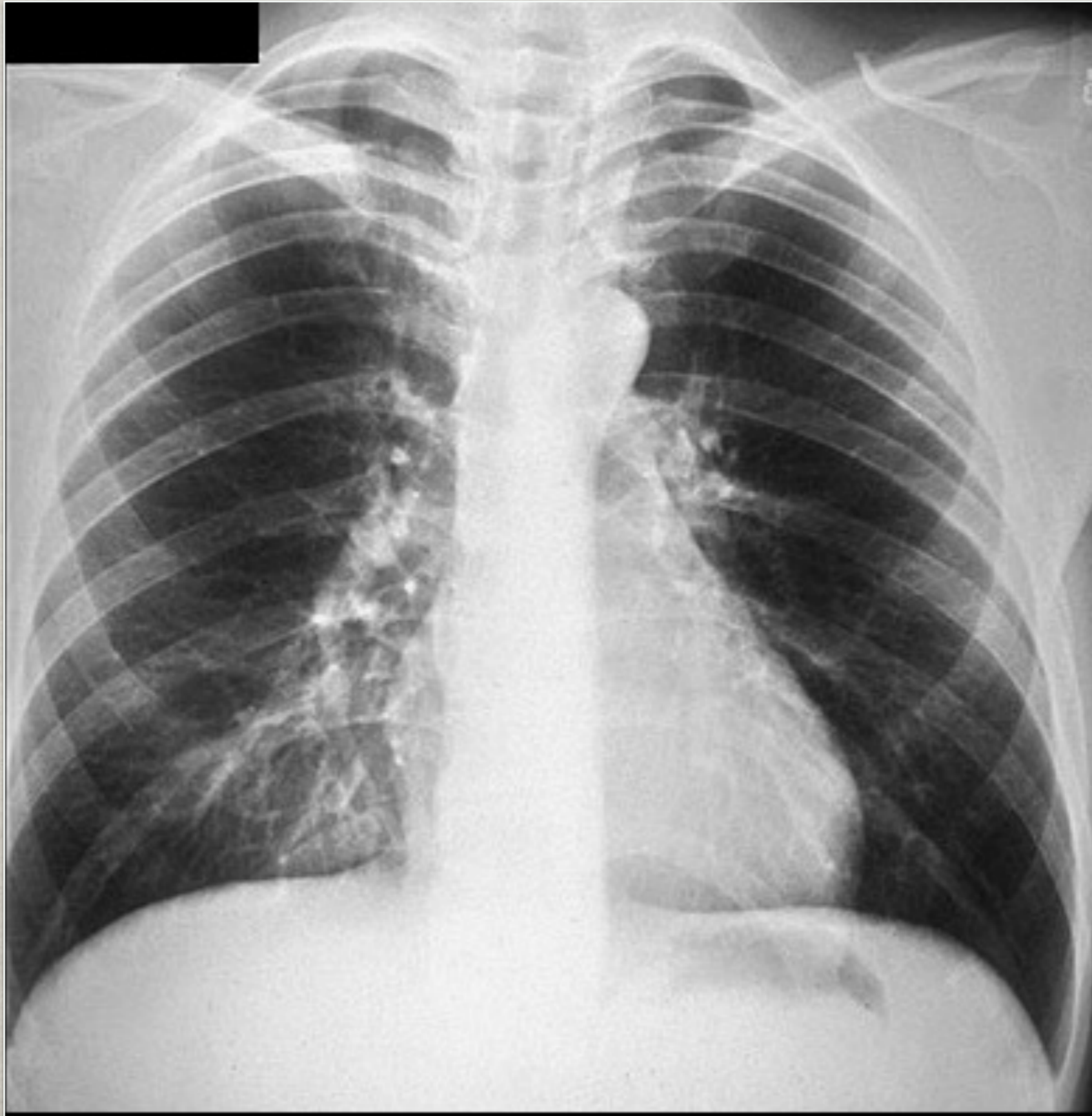
Αριστερή
κοιλία

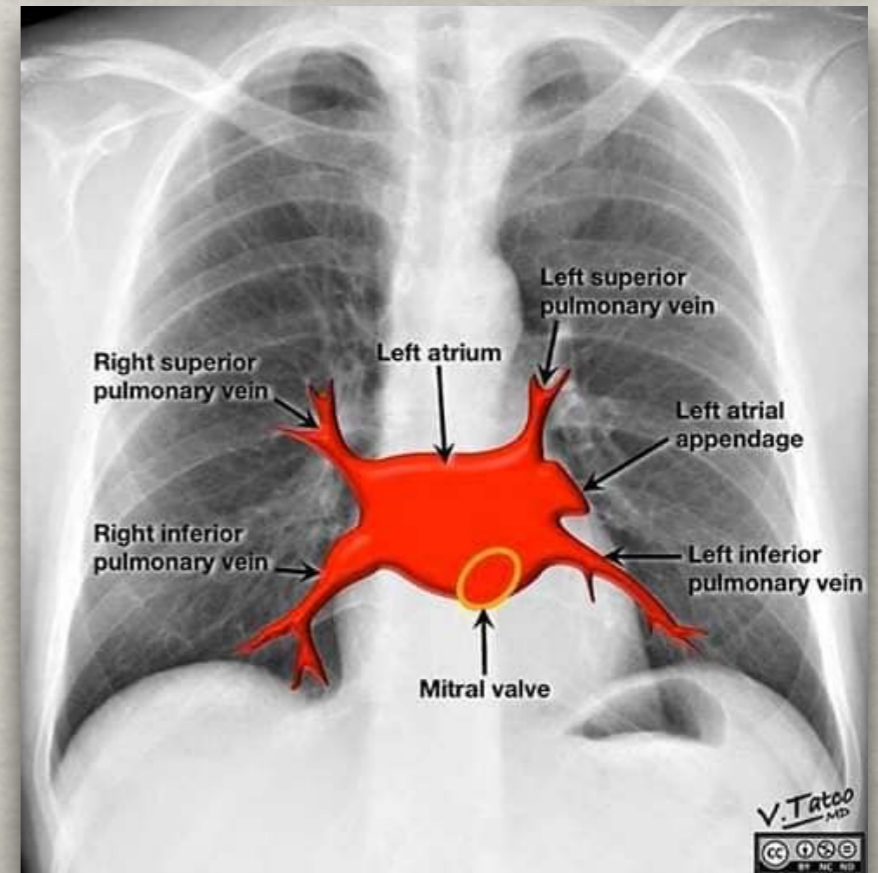
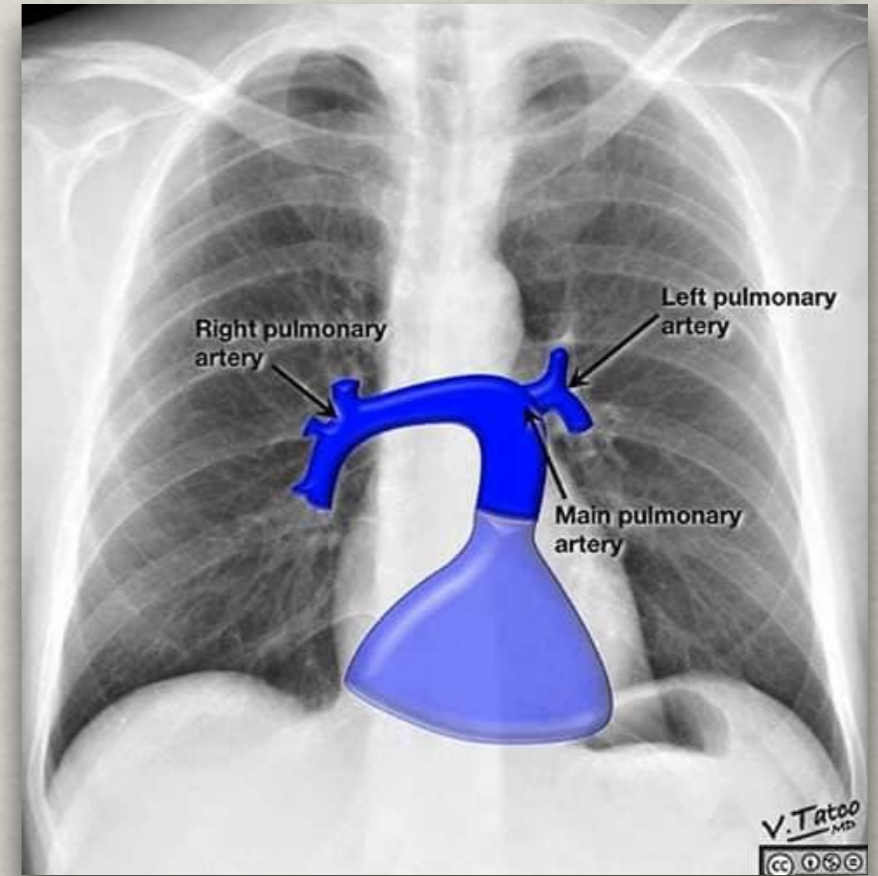
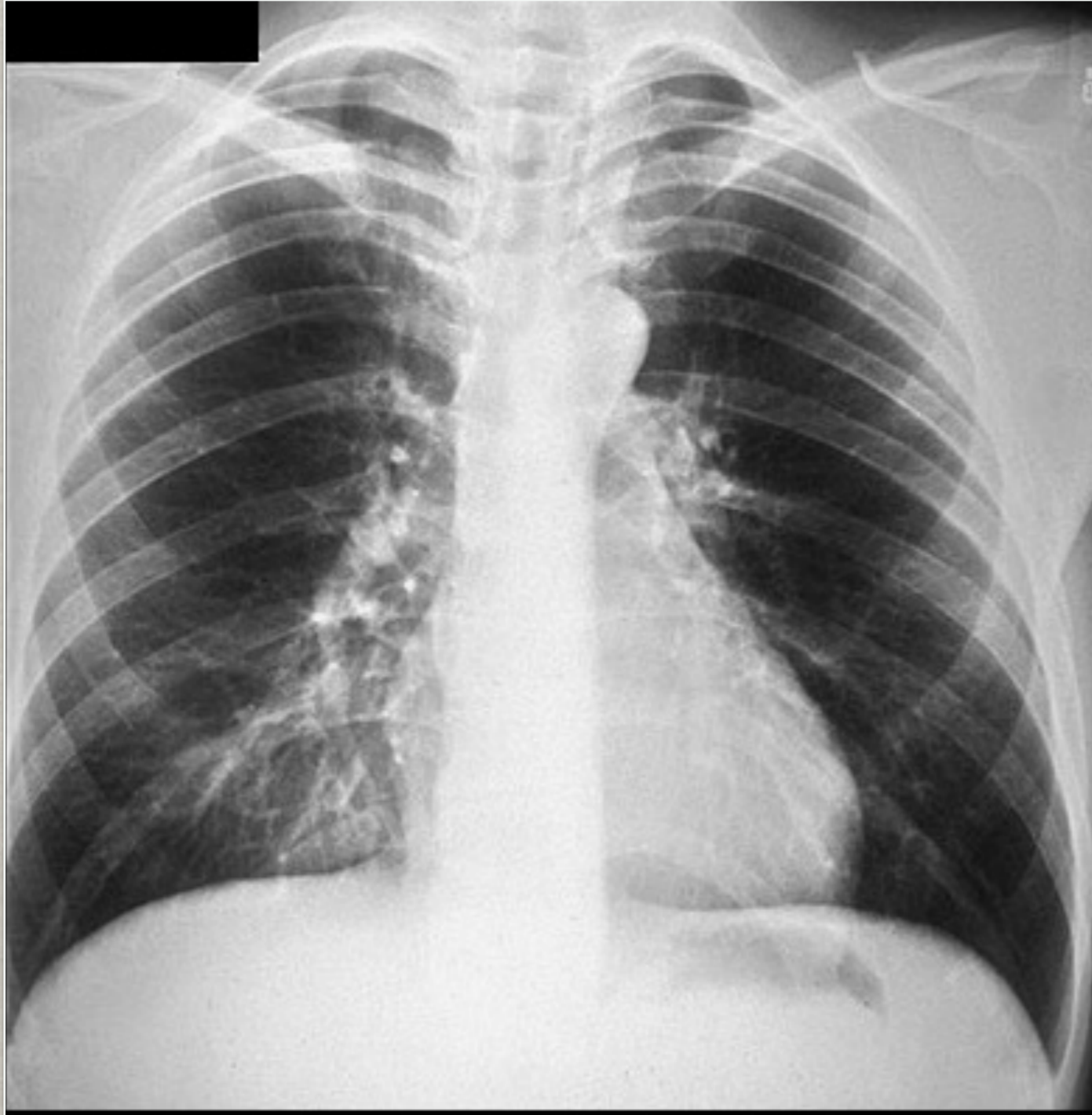
Κορυφή
καρδιάς

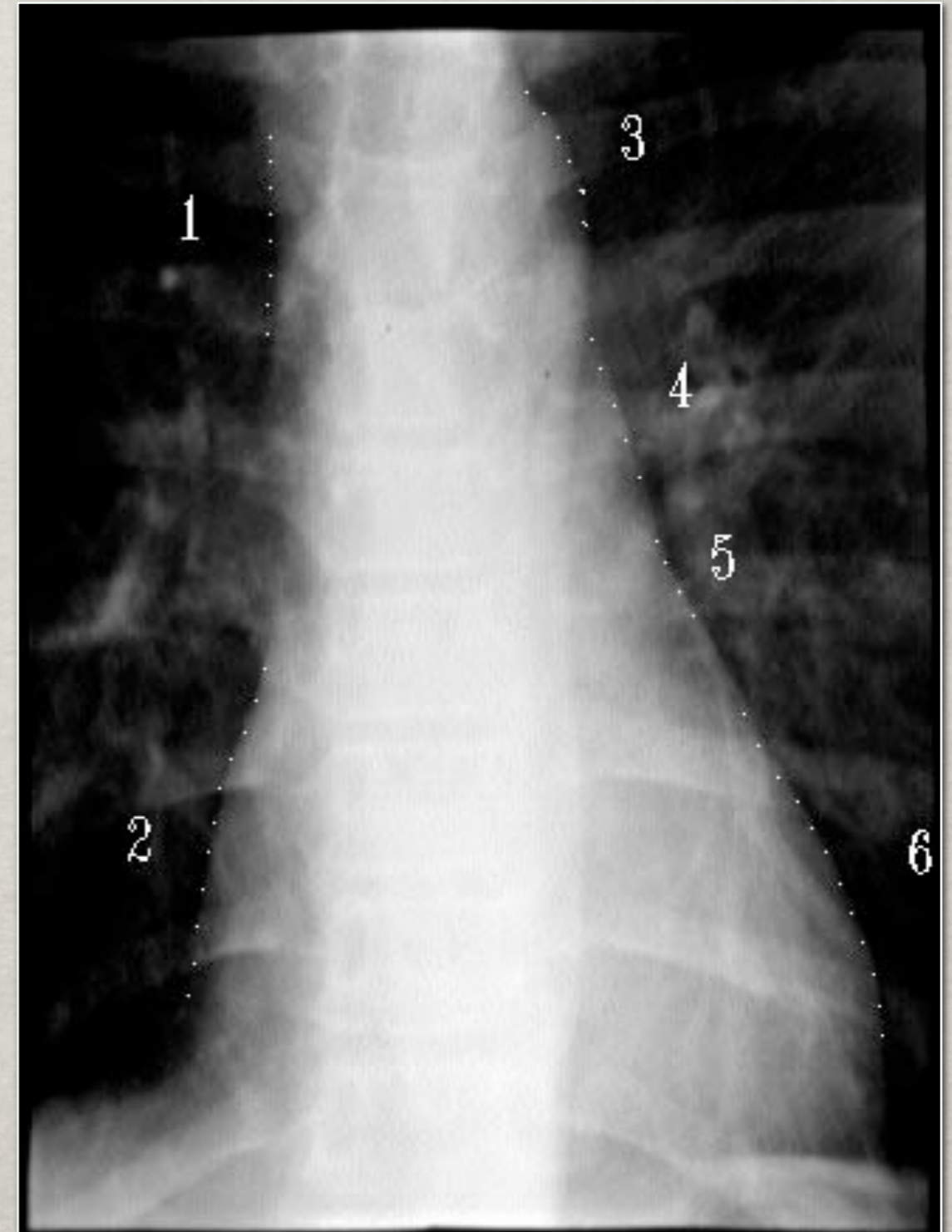
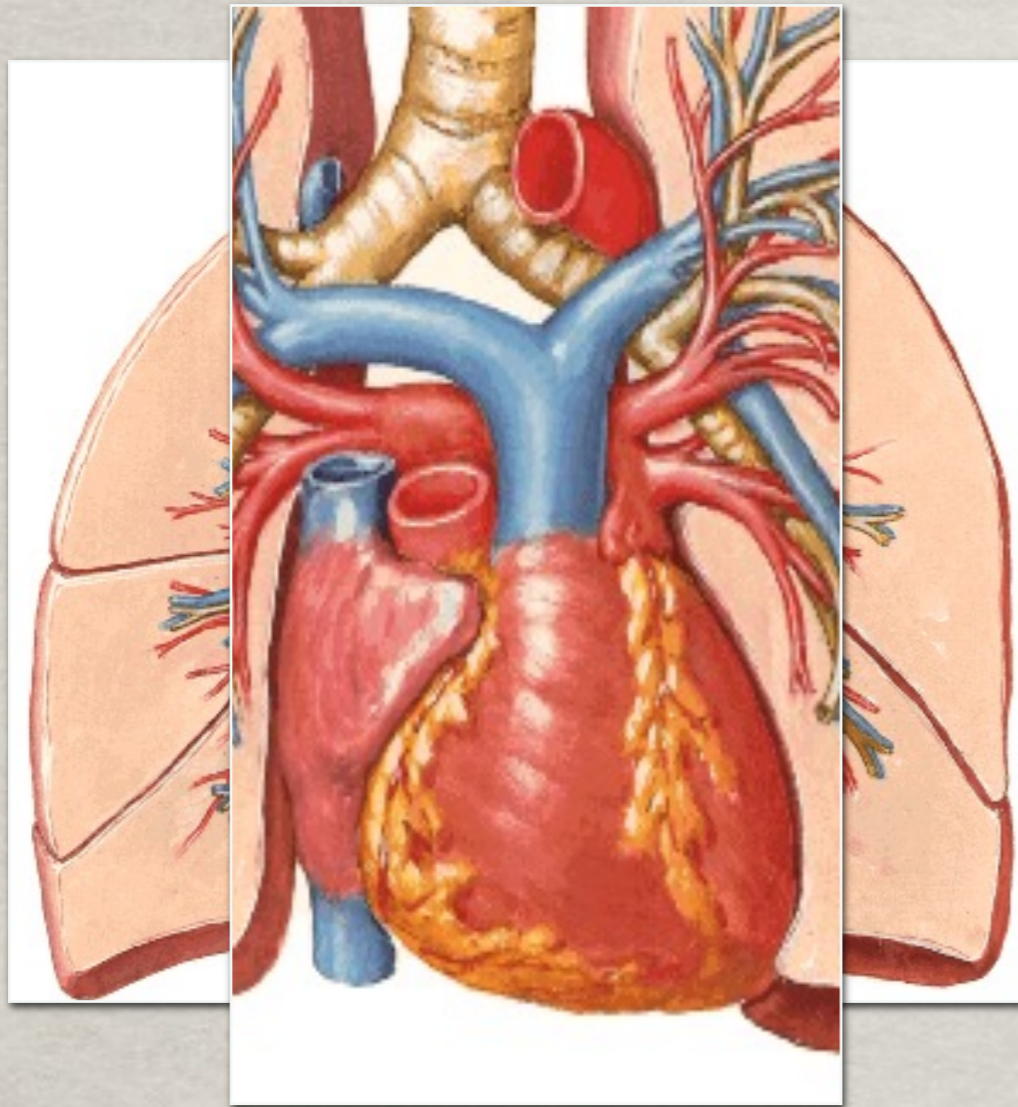




Πνευμονική αρτηρία

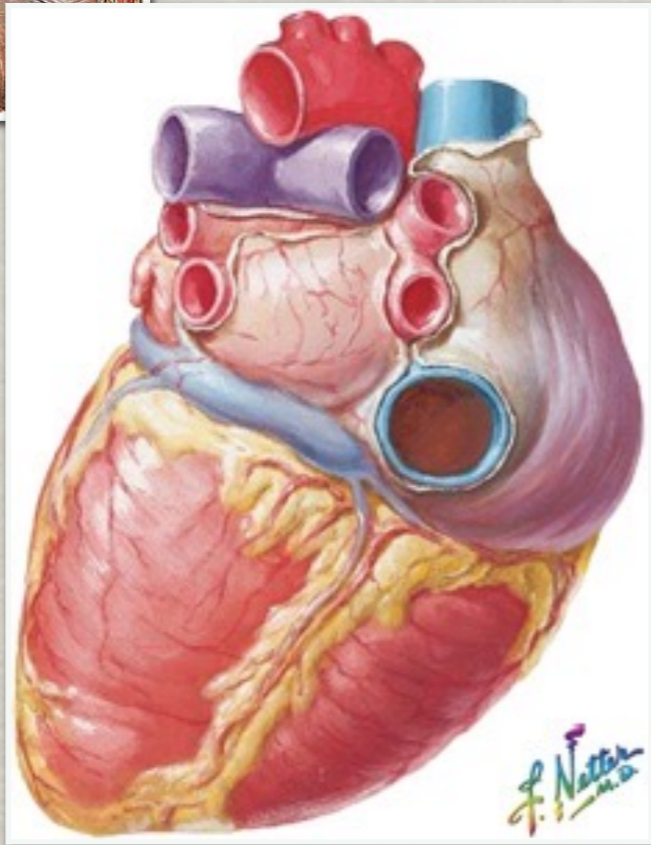
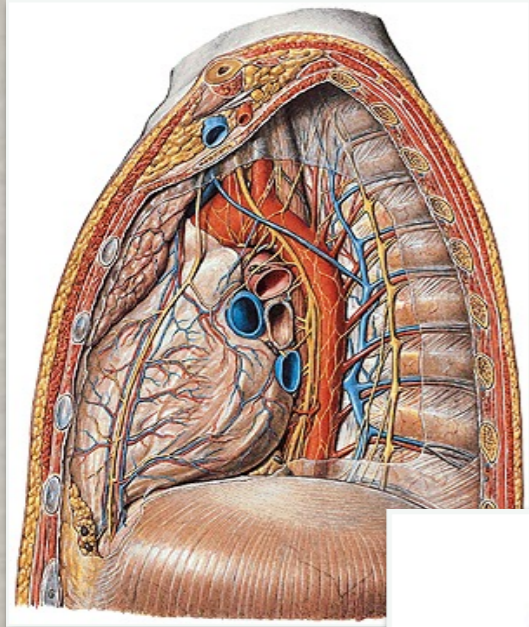




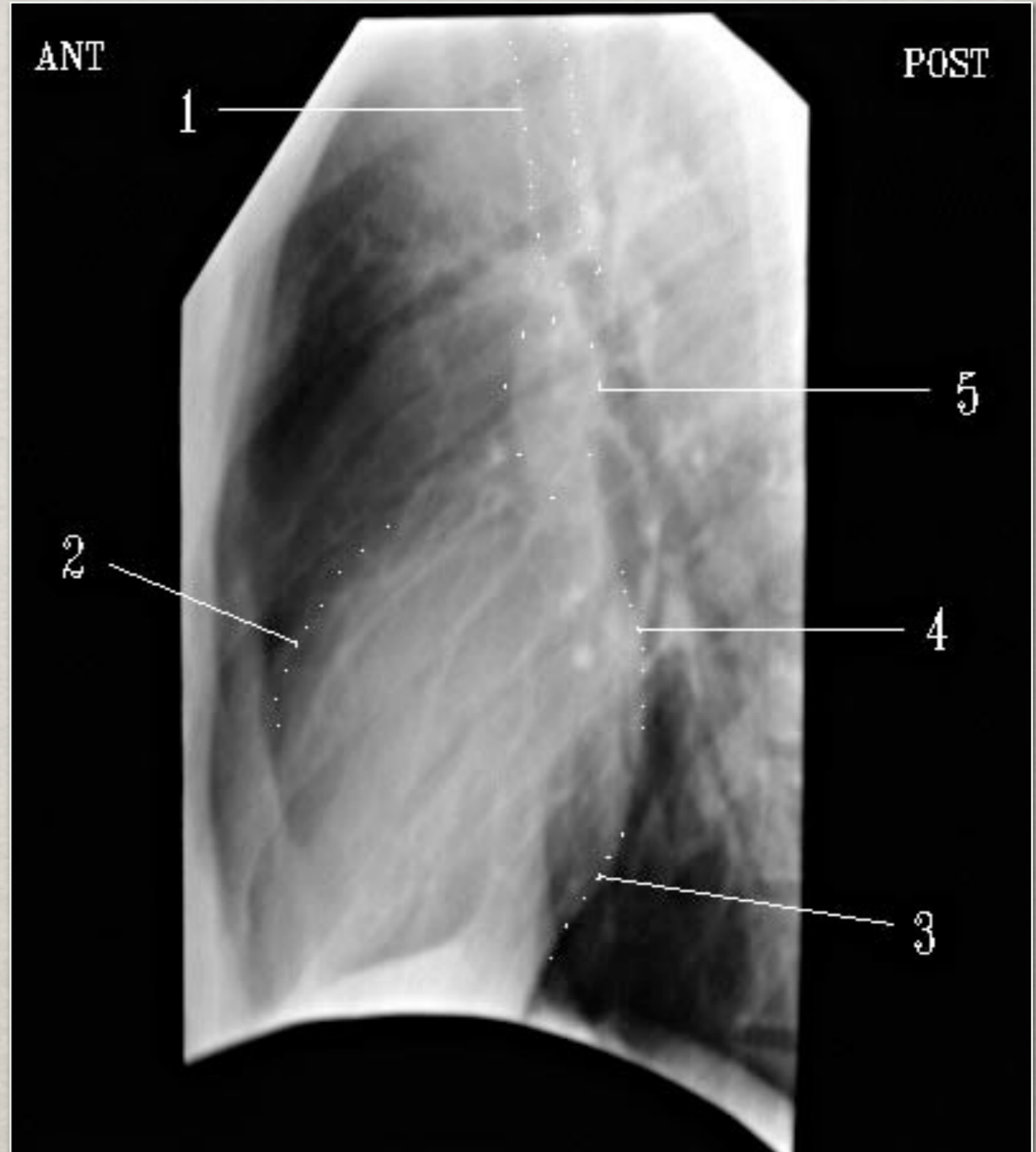


1. SVC
2. Δ. κόλπο
3. Αορτικό τόξο
4. Πνευμονική αρτηρία
5. Α. Κόλπος
6. Α. κοιλία

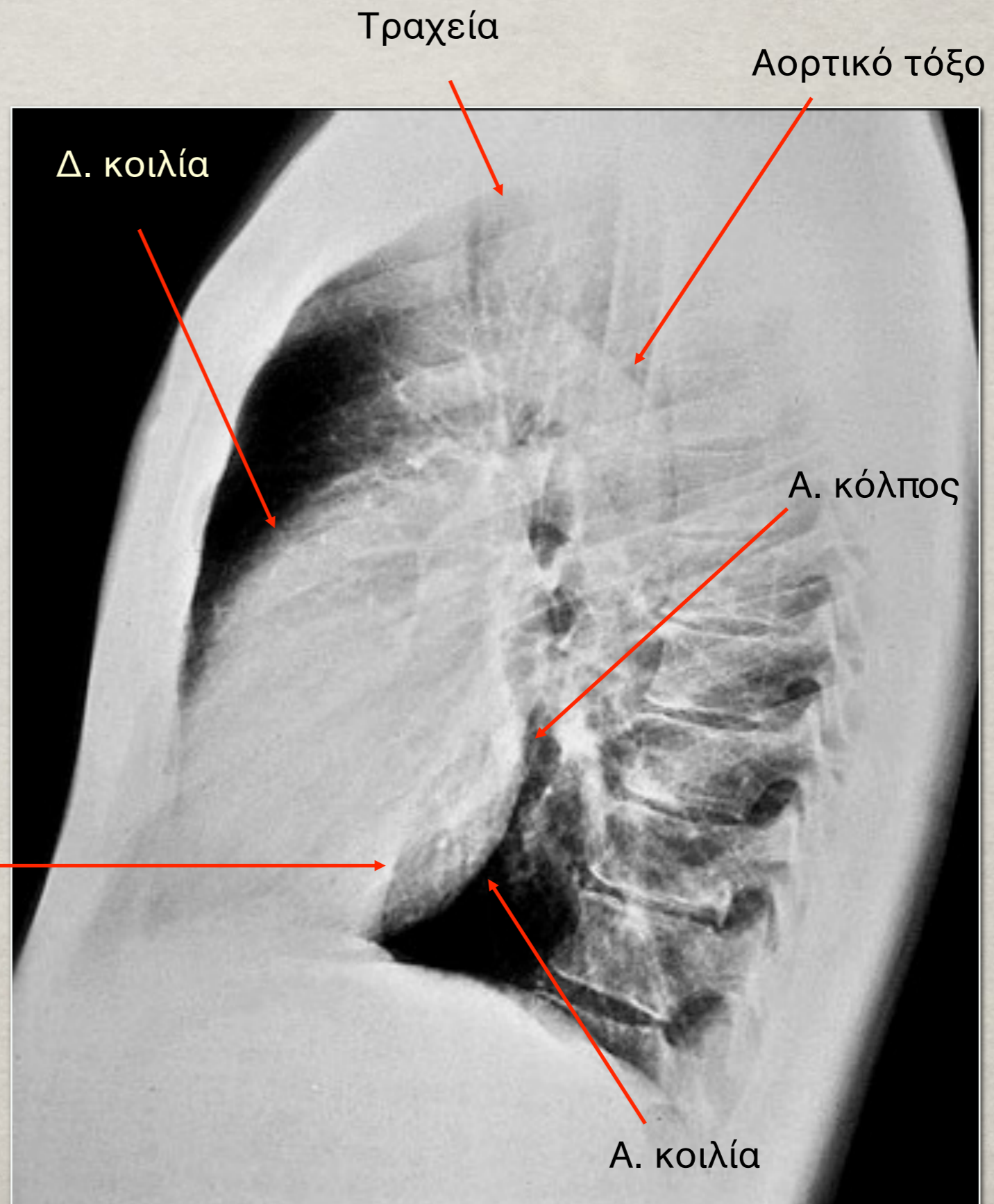
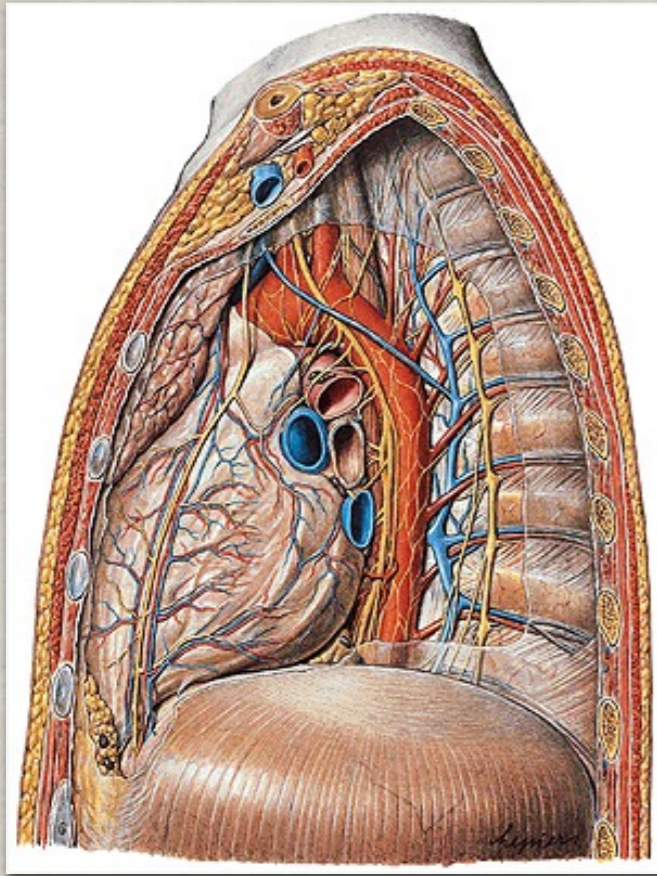
ΘΩΡΑΚΑΣ



1. Τραχεία
2. Δ. κοιλία
3. Α. κοιλία
4. Α. κόλπος
5. Δ. Πνευμονική αρτηρία



ΘΩΡΑΚΑΣ



Τραχεία

Αορτικό τόξο

Δ. κοιλία

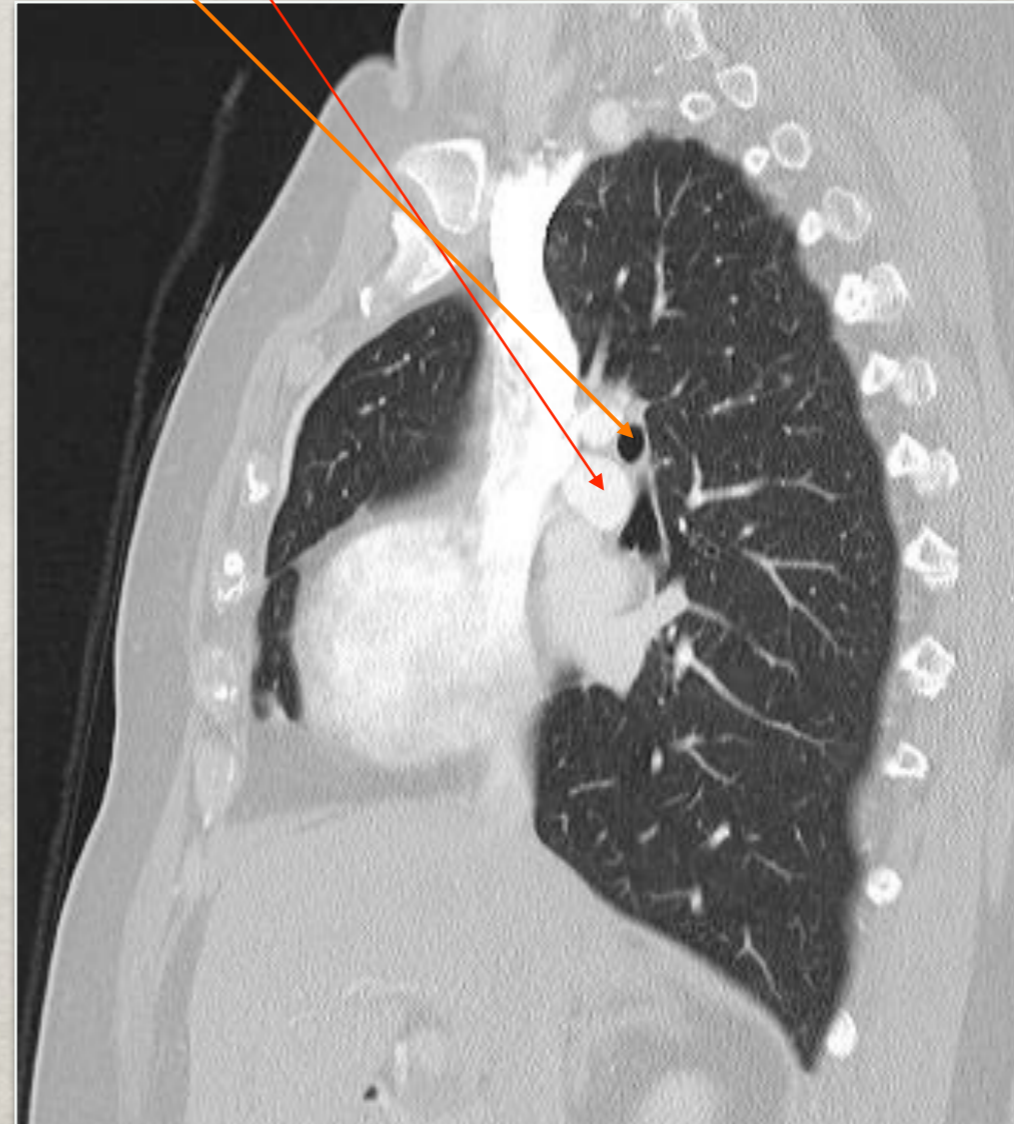
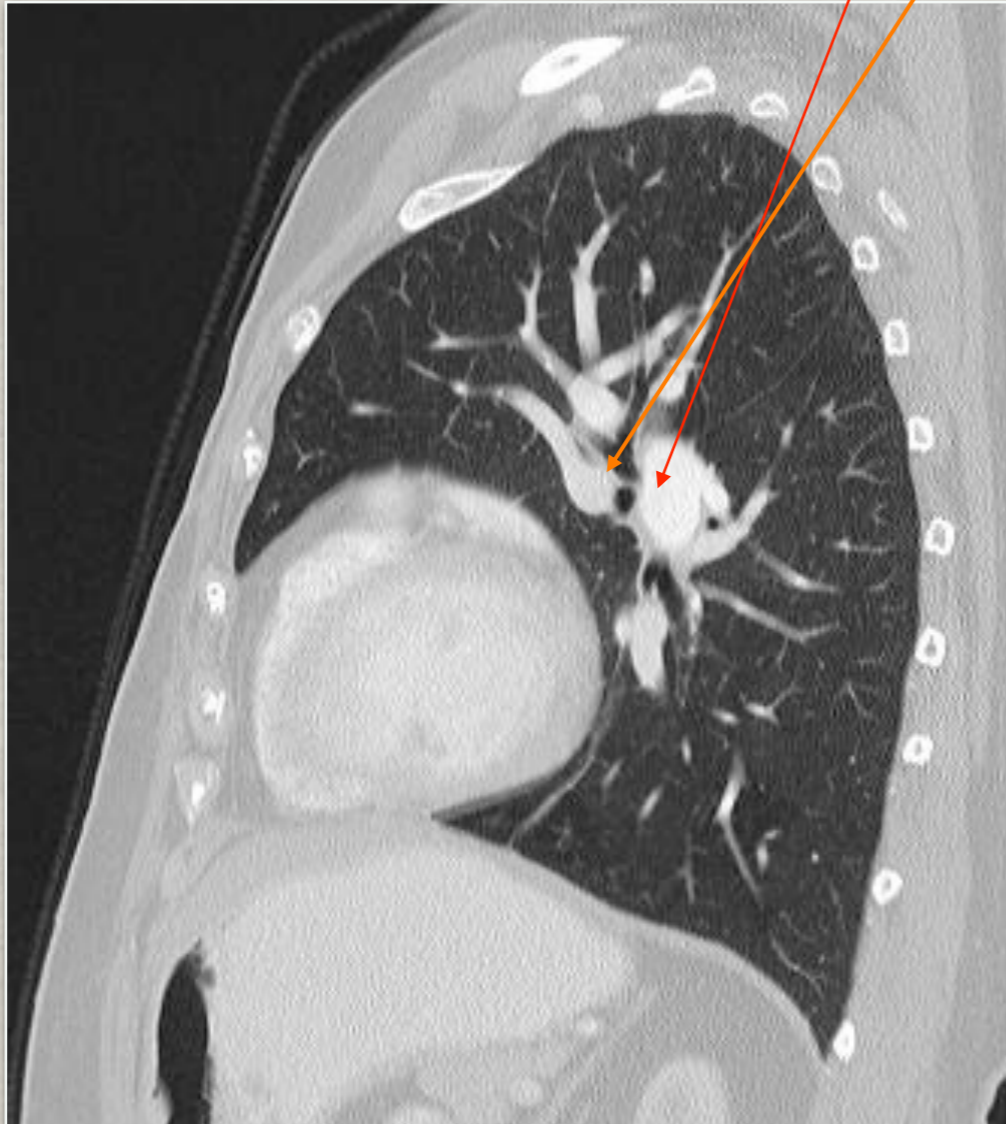
Α. κόλπος

Κάτω κοίλη
φλέβα

Α. κοιλία

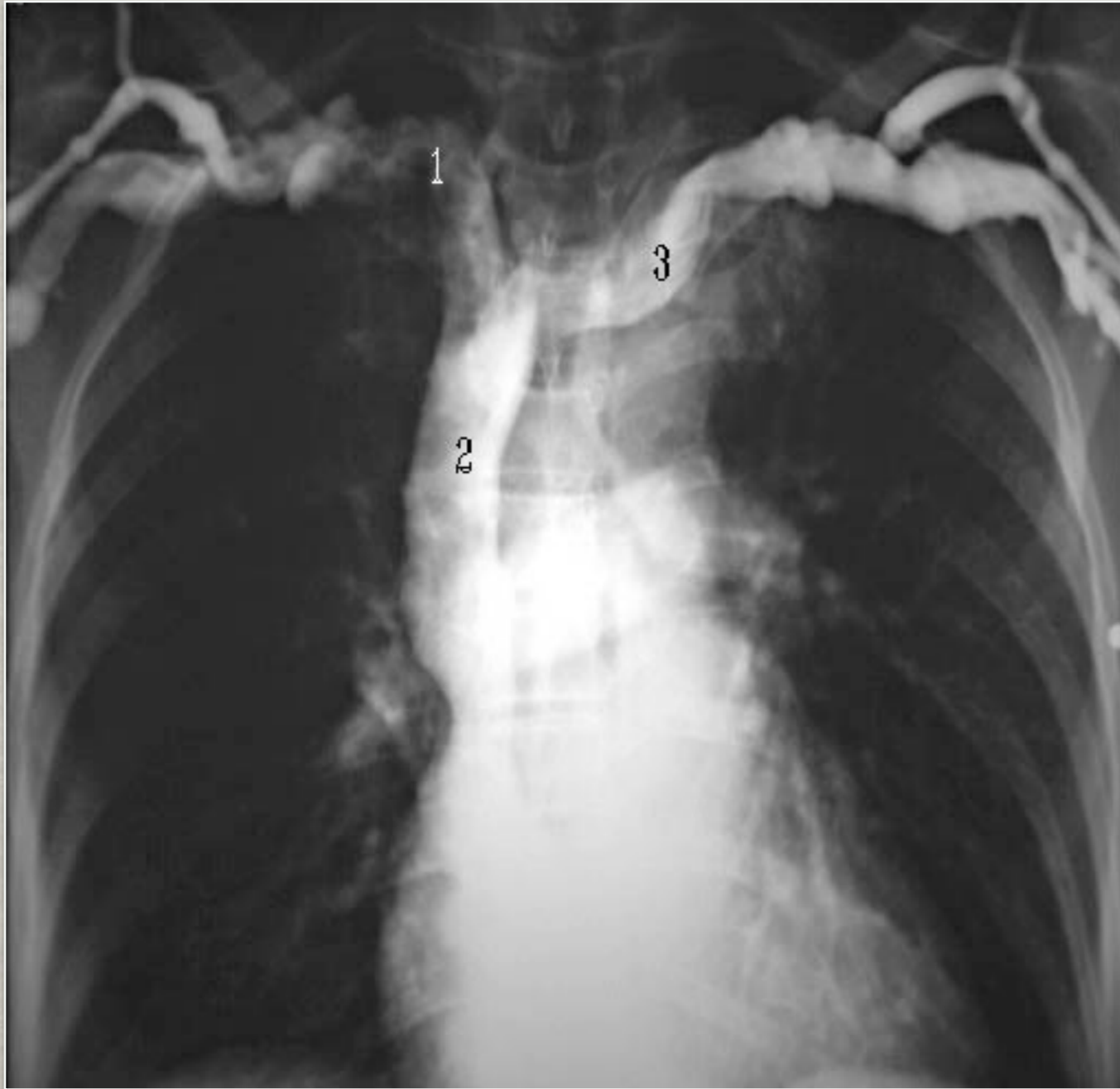Πνευμονική αρτηρία

Βρόγχος

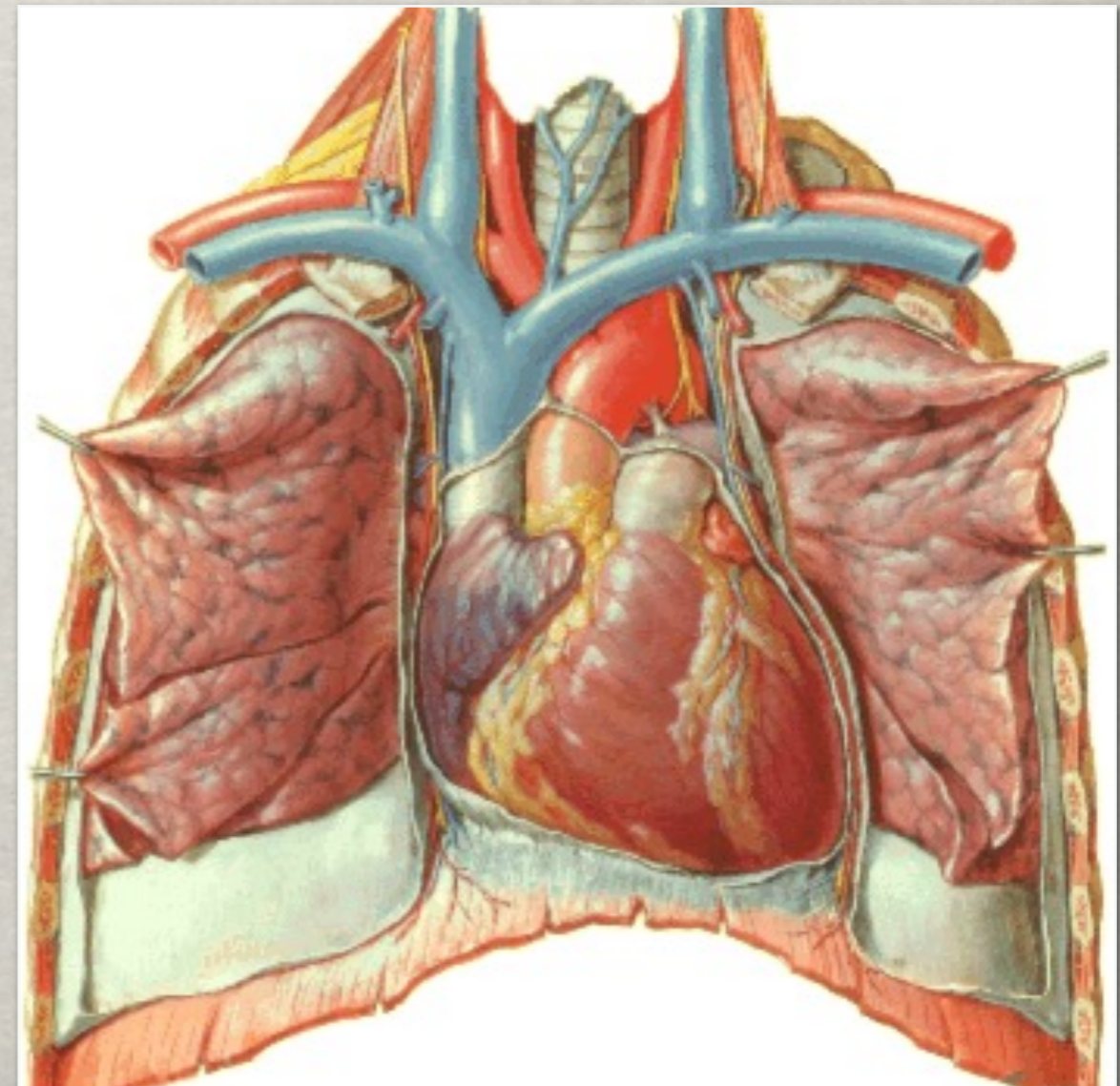


Αρ. πνευμονική πύλη

Δ. πνευμονική πύλη



- 1. Δ. Βραχιοκεφαλική φλέβα
- 3. Αρ. Βραχιοκεφαλική φλέβα
- 2. Ανω κοίλη φλέβα

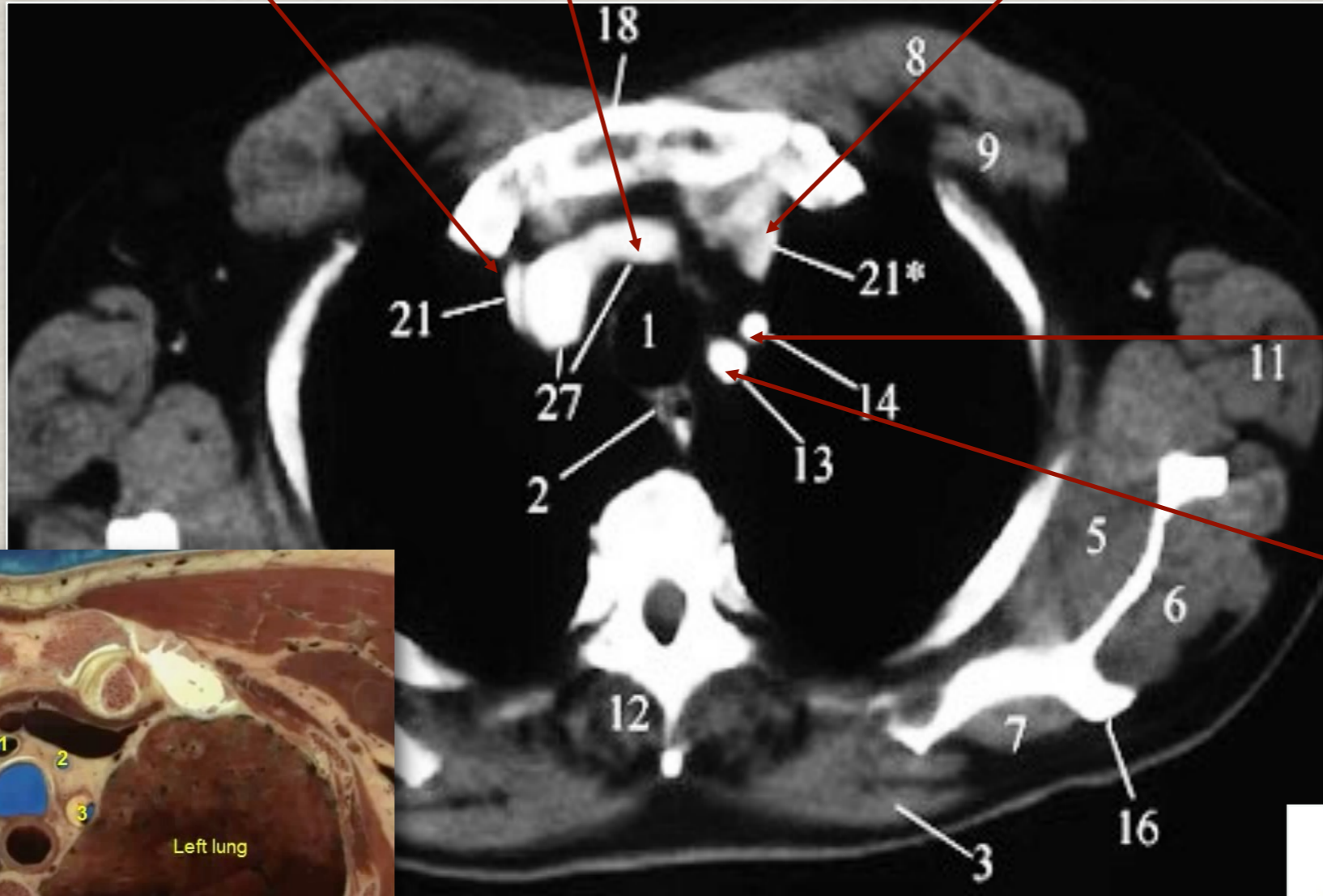


ΘΩΡΑΚΑΣ

Βραχιοκεφαλική
φλέβα

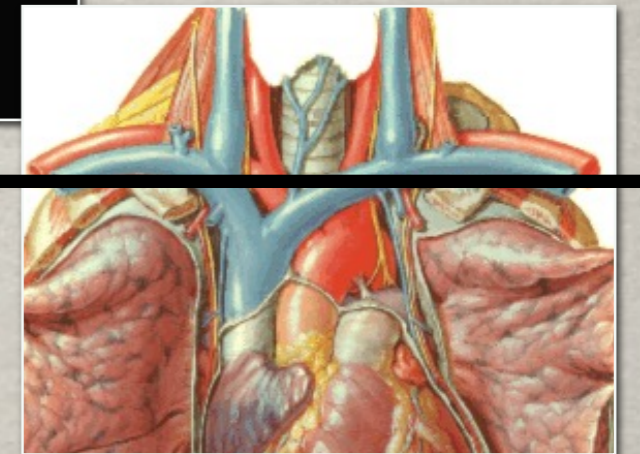
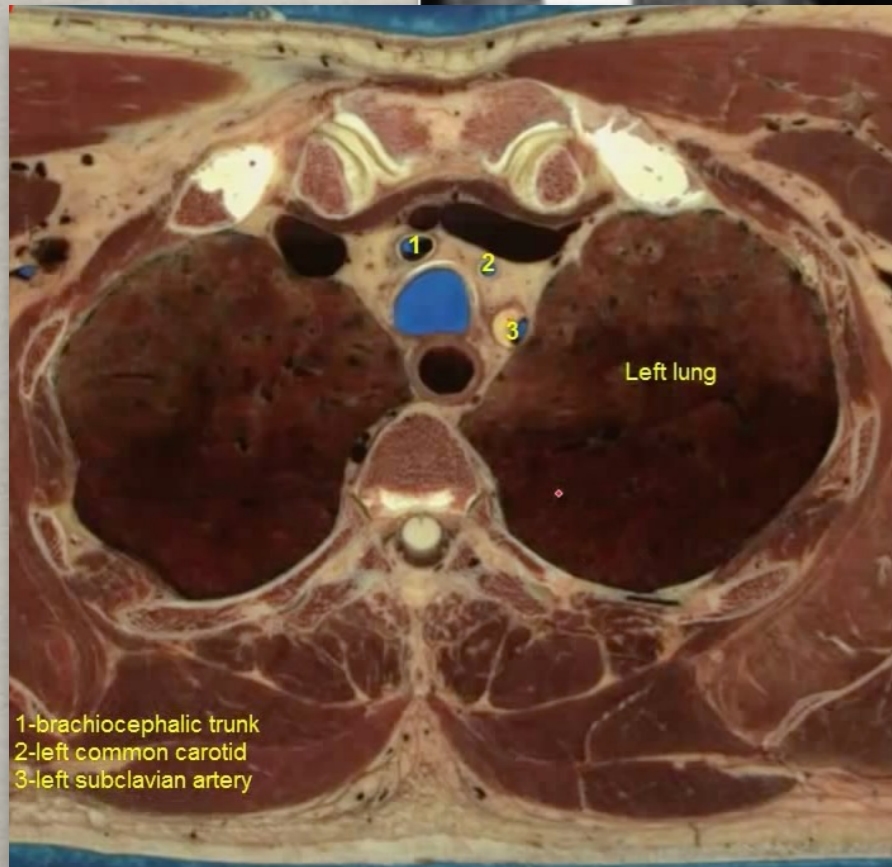
Βραχιοκεφαλική
αρτηρία

Βραχιοκεφαλική
φλέβα



Κοινή
καρωτίδα

Υποκλείδια
αρτηρία

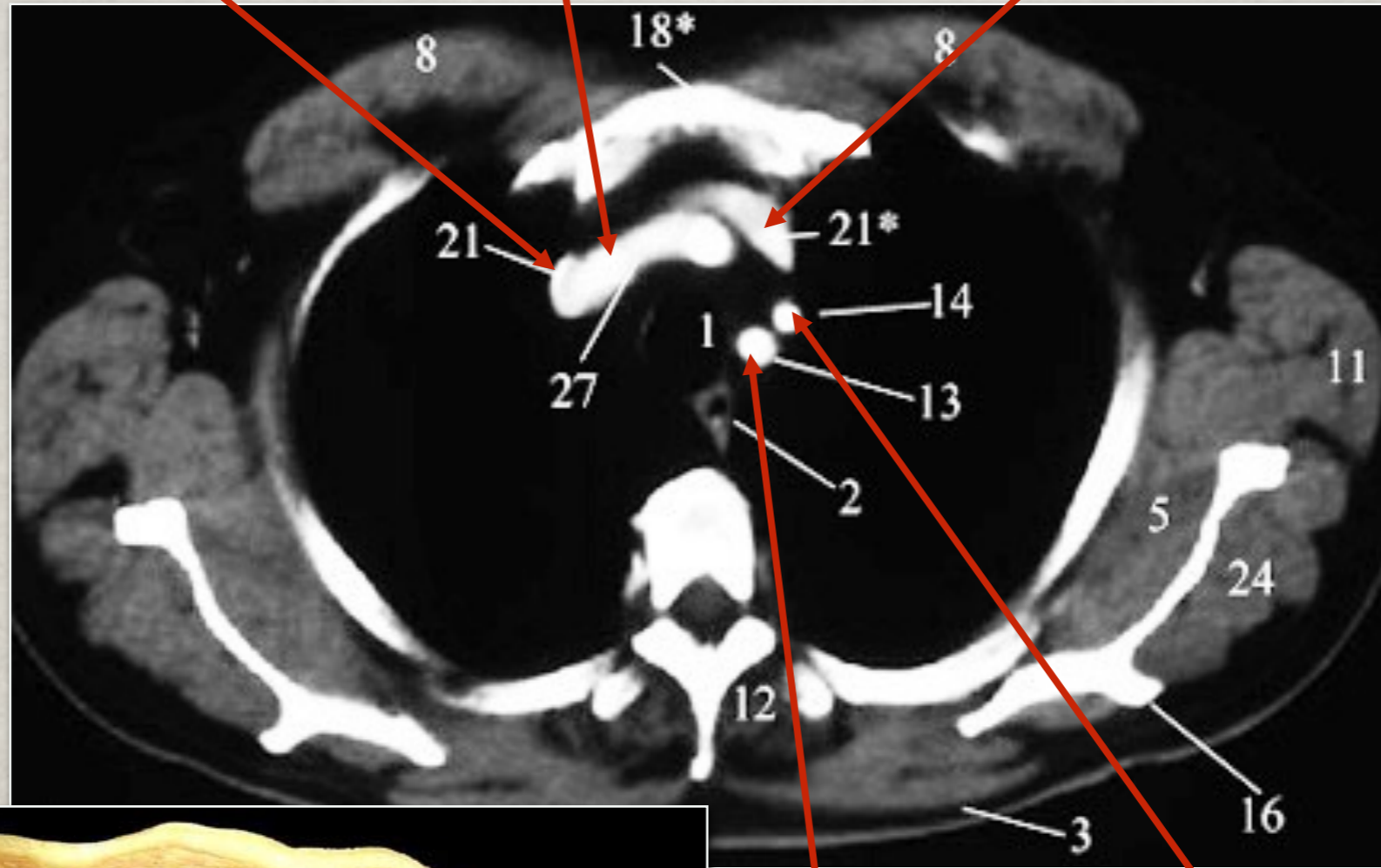


ΘΩΡΑΚΑΣ

Βραχιοκεφαλική
φλέβα

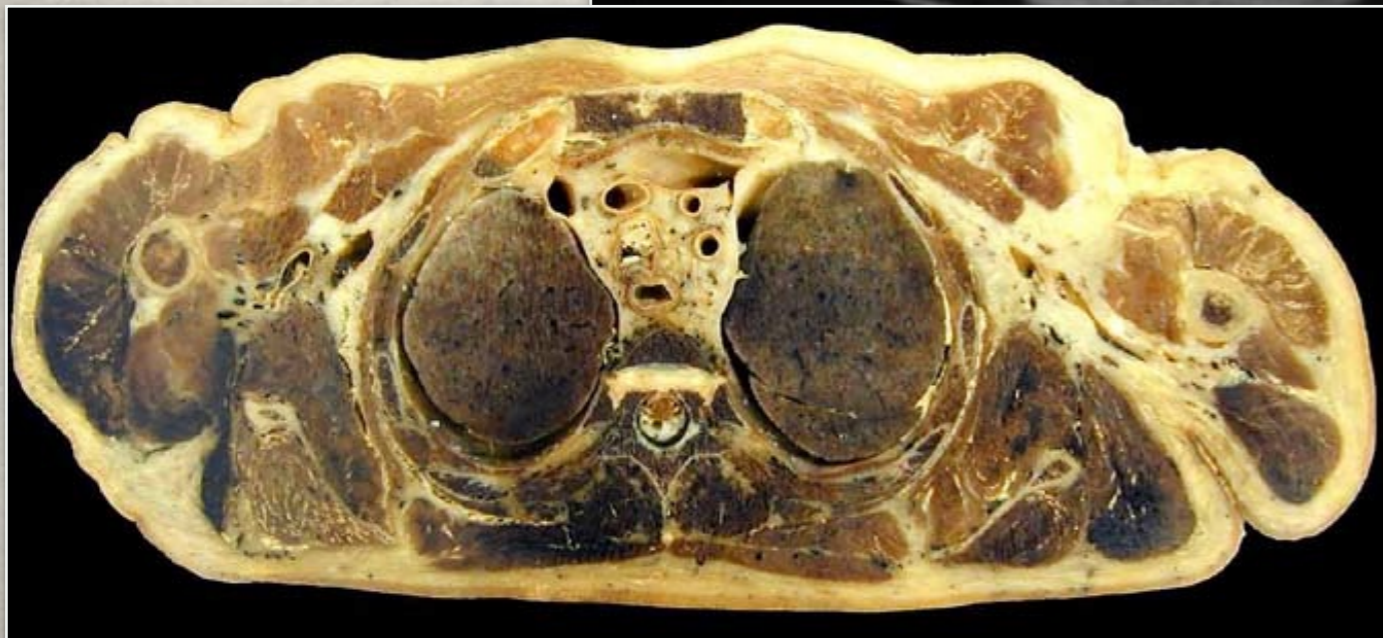Βραχιοκεφαλική
αρτηρία

Βραχιοκεφαλική
φλέβα

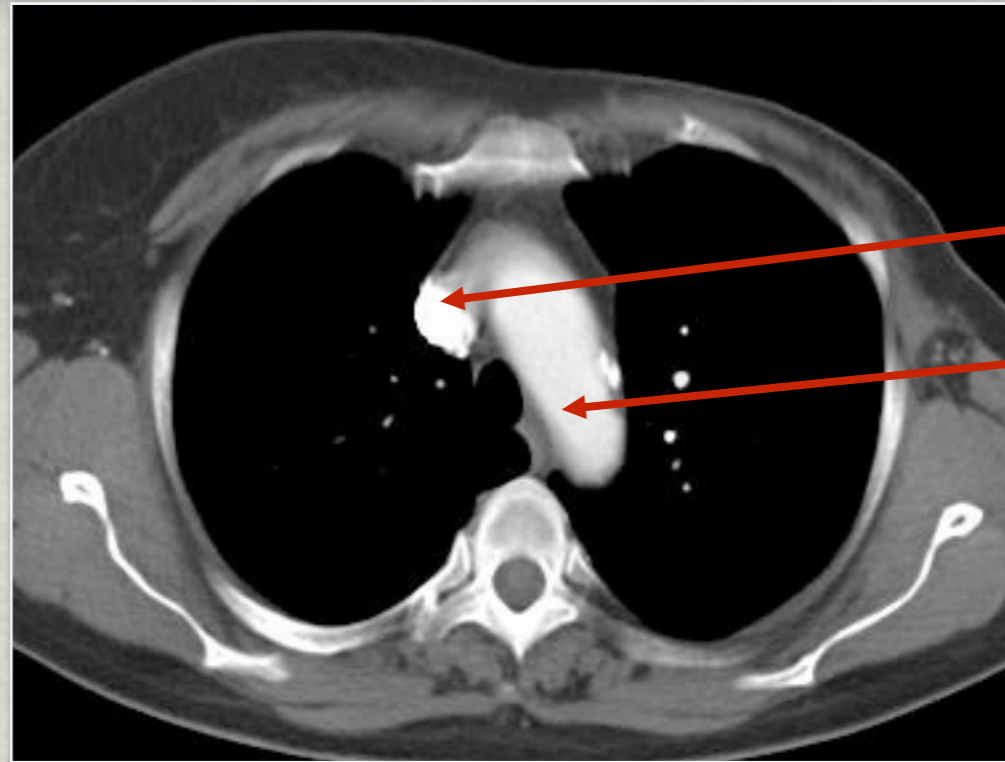
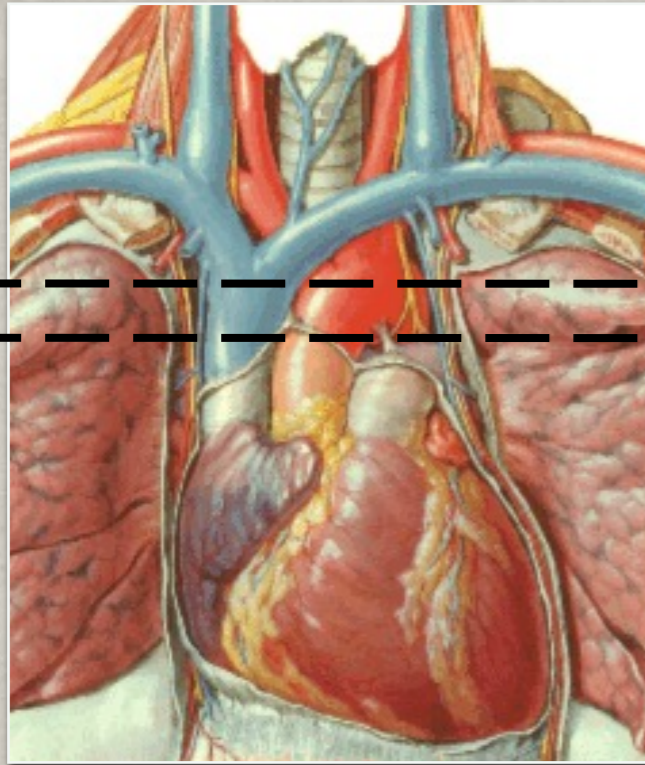


Υποκλείδια
αρτηρία

Κοινή
καρωτίδα

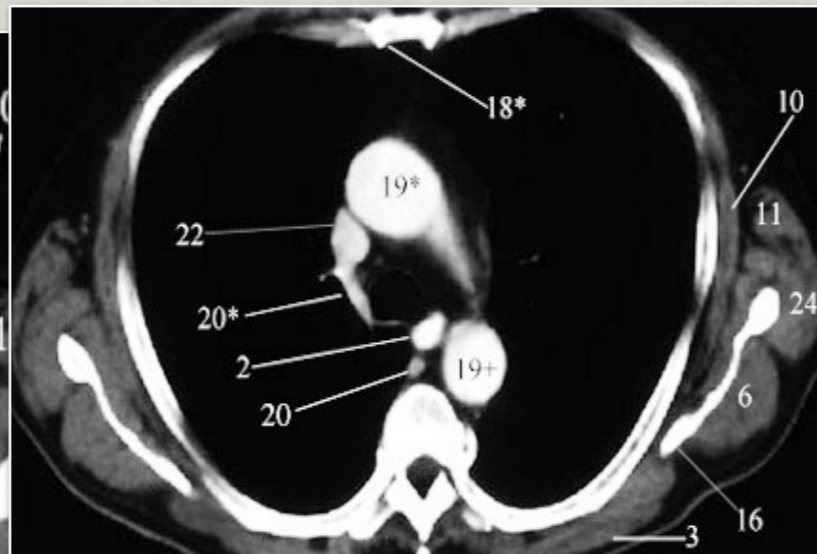
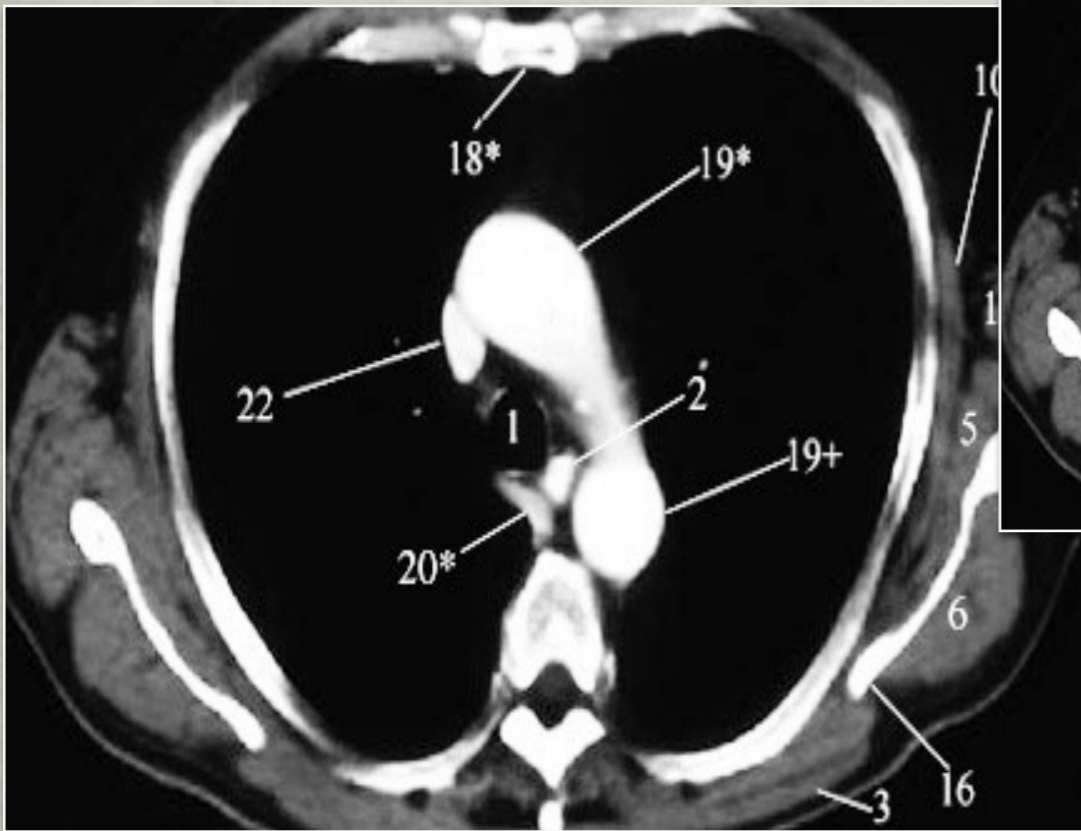
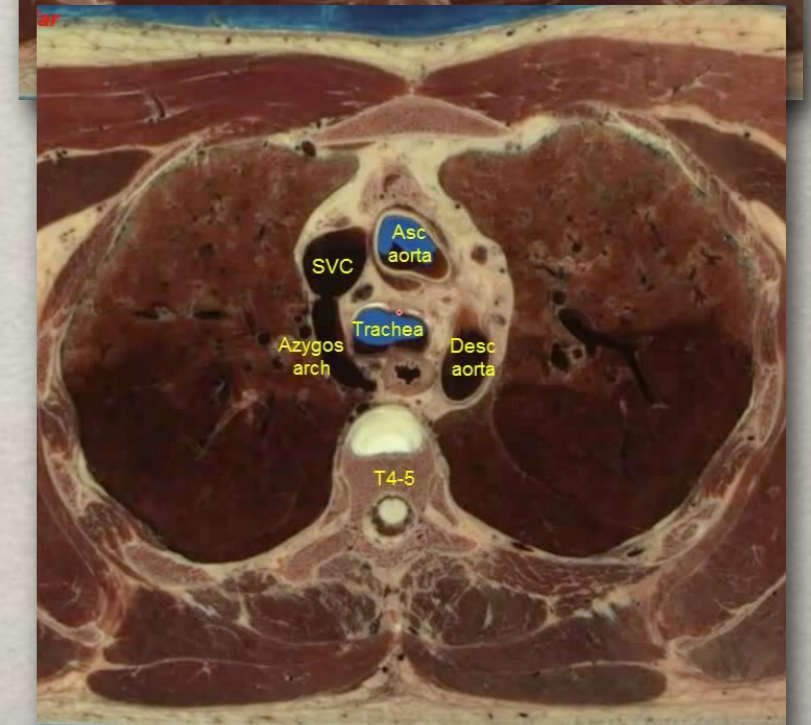
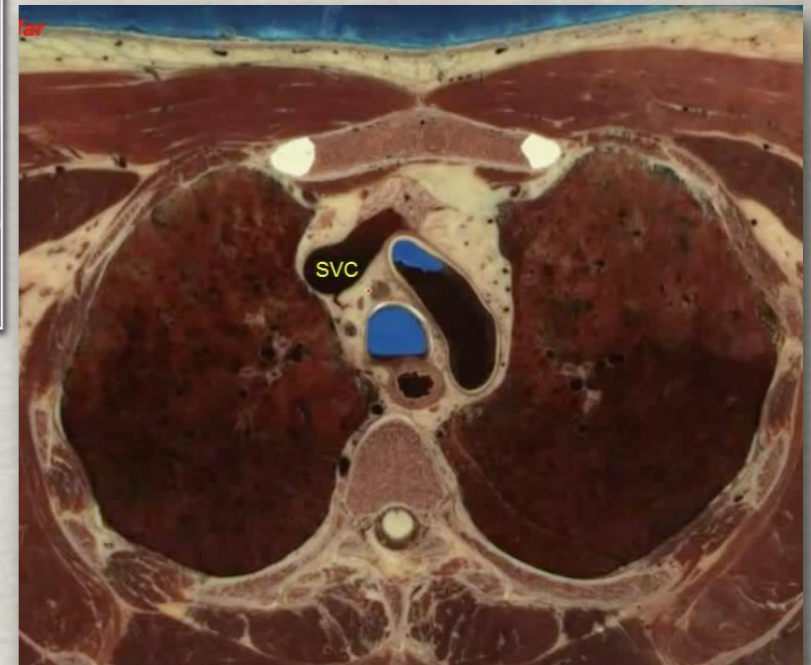

ΘΩΡΑΚΑΣ



Ανω κοίλη φλέβα

Αορτικό τόξο



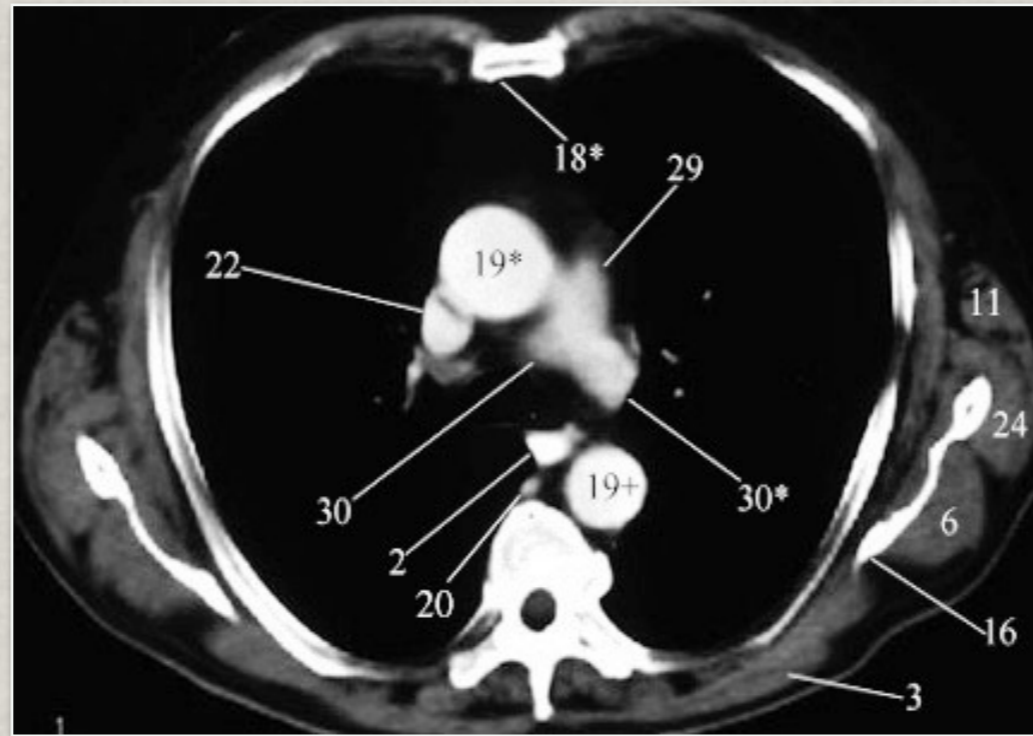
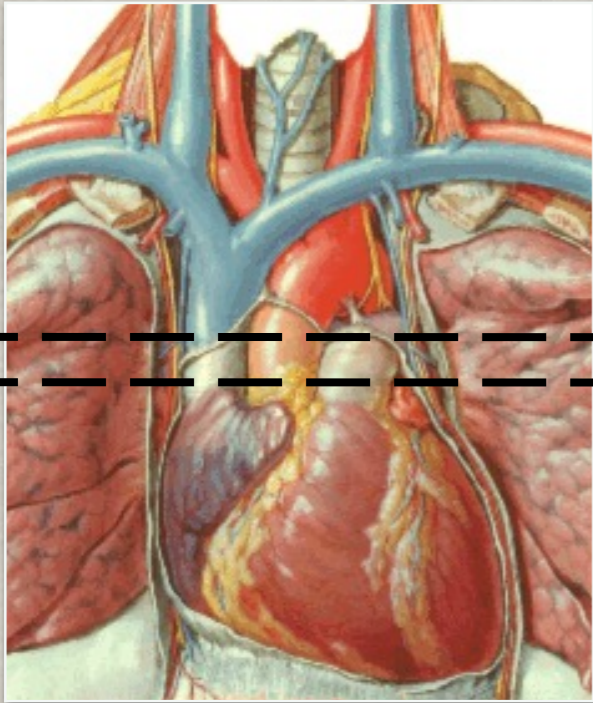
19* Ανιούσα αορτή

19+ Κατιούσα αορτή

20 Αζυγη φλέβα

22 Ανω κοίλη φλέβα

ΘΩΡΑΚΑΣ



19* Ανιούσα αορτή

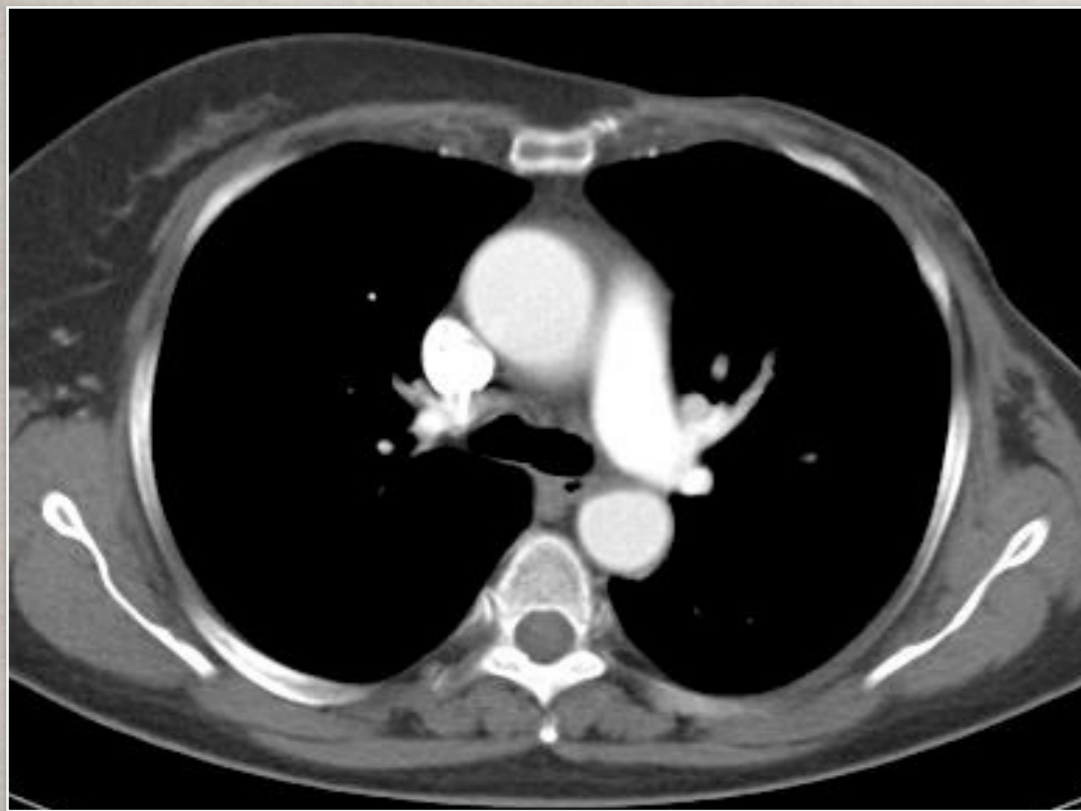19+ Κατιούσα αορτή

20 Αζυγη φλέβα

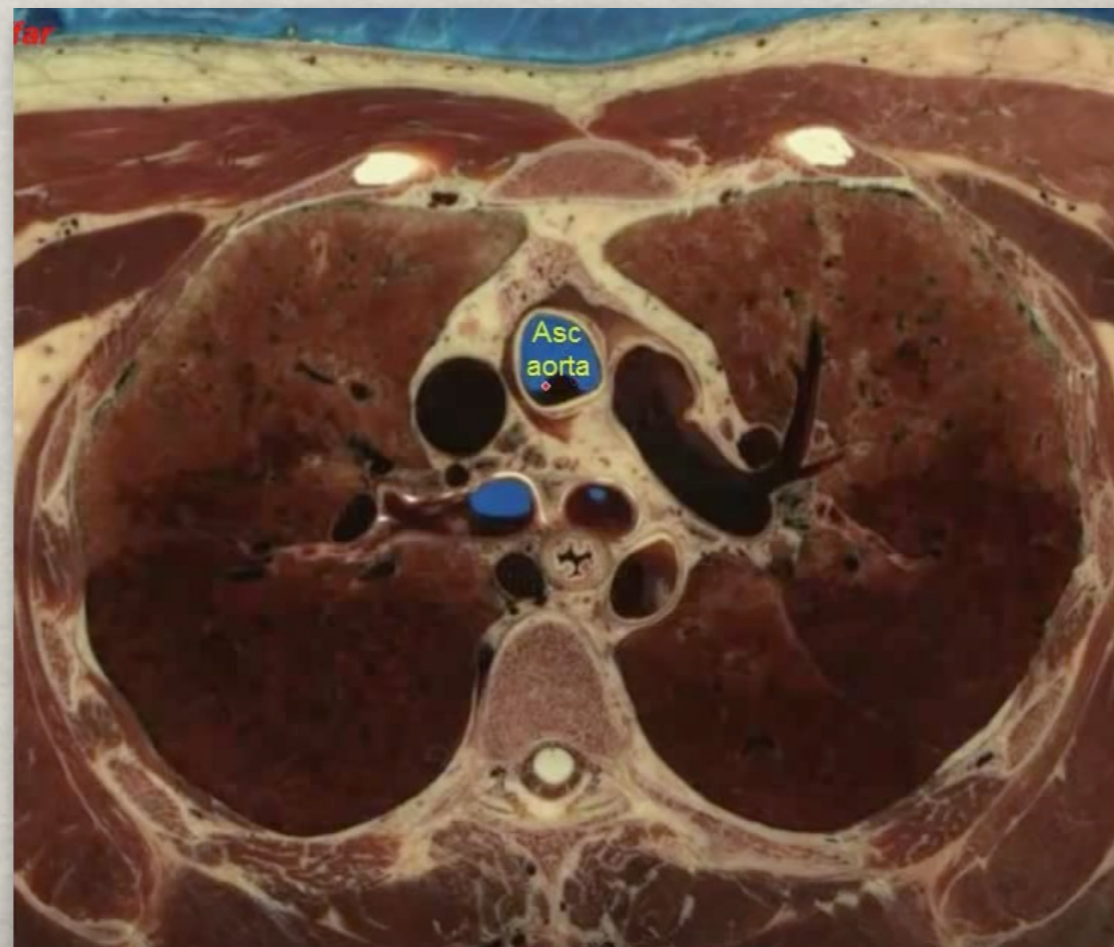
29 Κορμός πνευμονικής αρτηρίας

30 Δεξιά πνευμονική αρτηρία

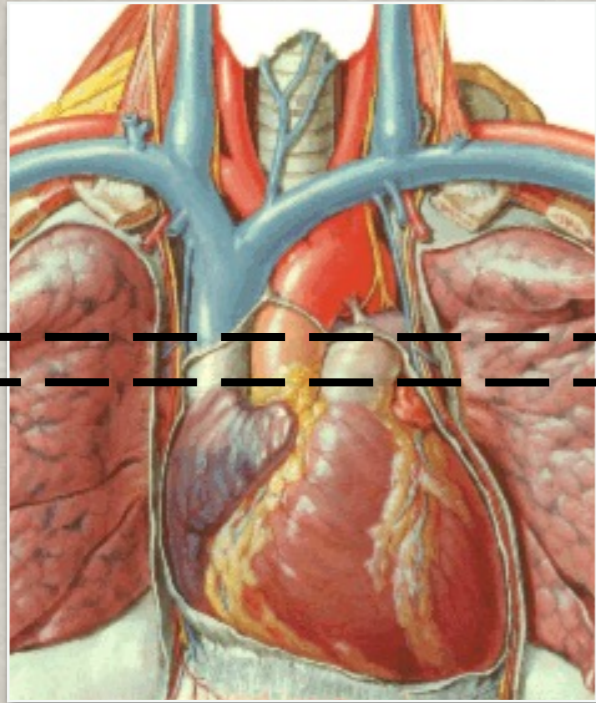
30* Αριστερή πνευμονική αρτηρία



22 Ανω κοίλη φλέβα

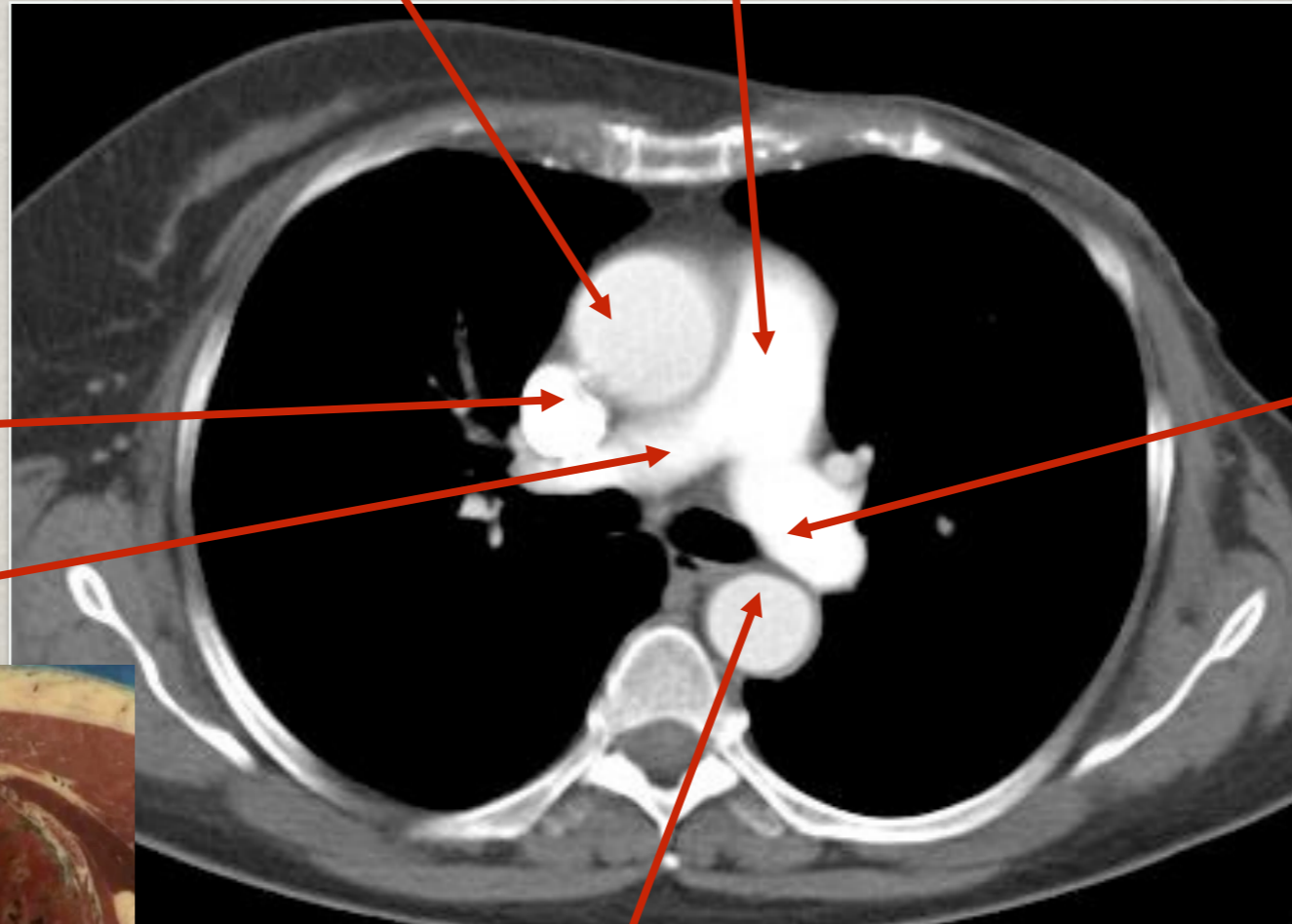


ΘΩΡΑΚΑΣ



Ανιούσα αορτή

Κορμός πνευμονικής
αρτηρίας

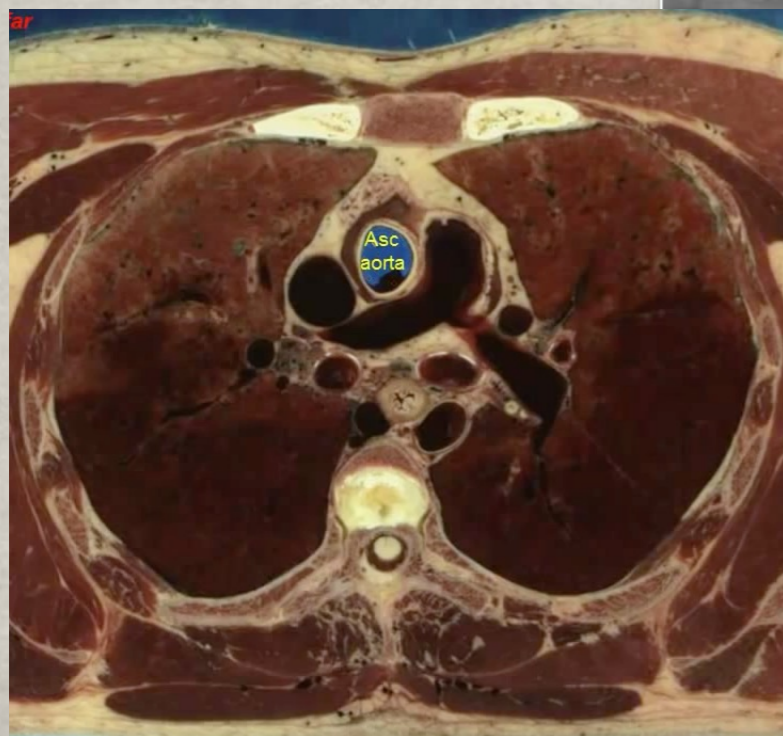


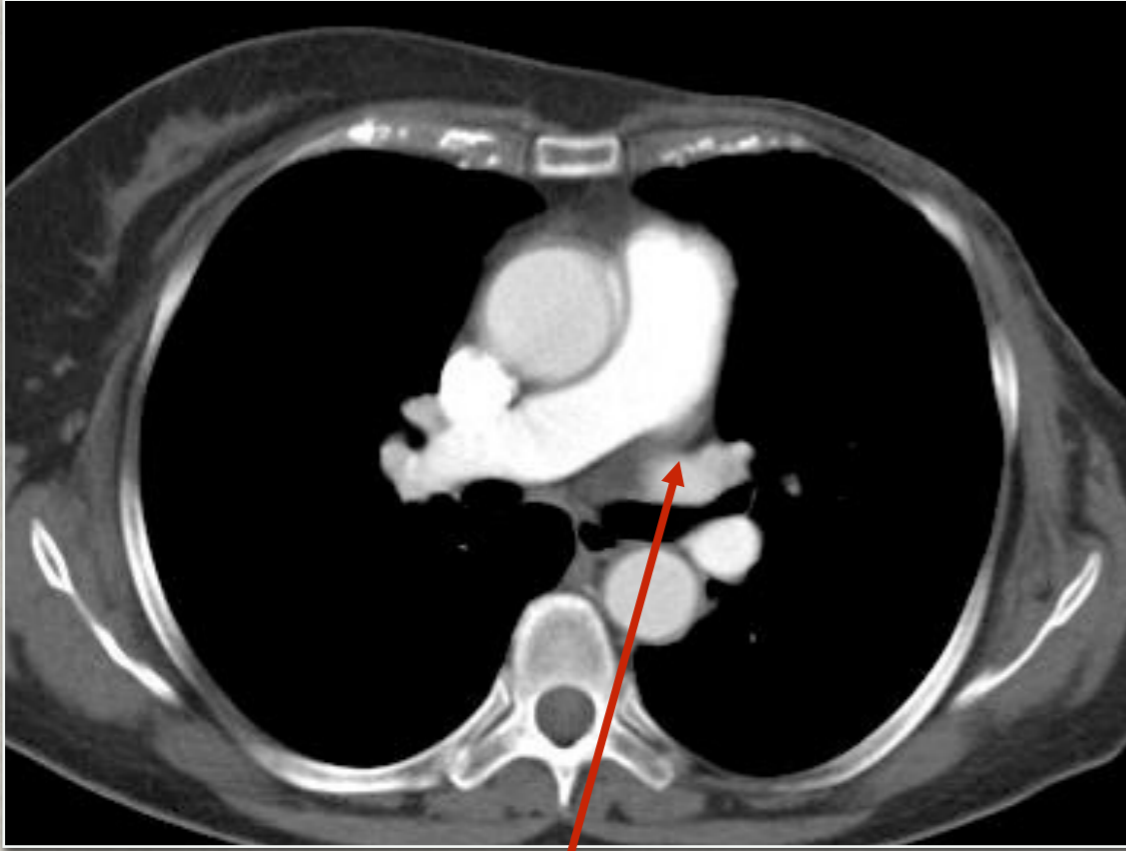
Αριστερή πνευμονική
αρτηρία

Ανω κοίλη φλέβα

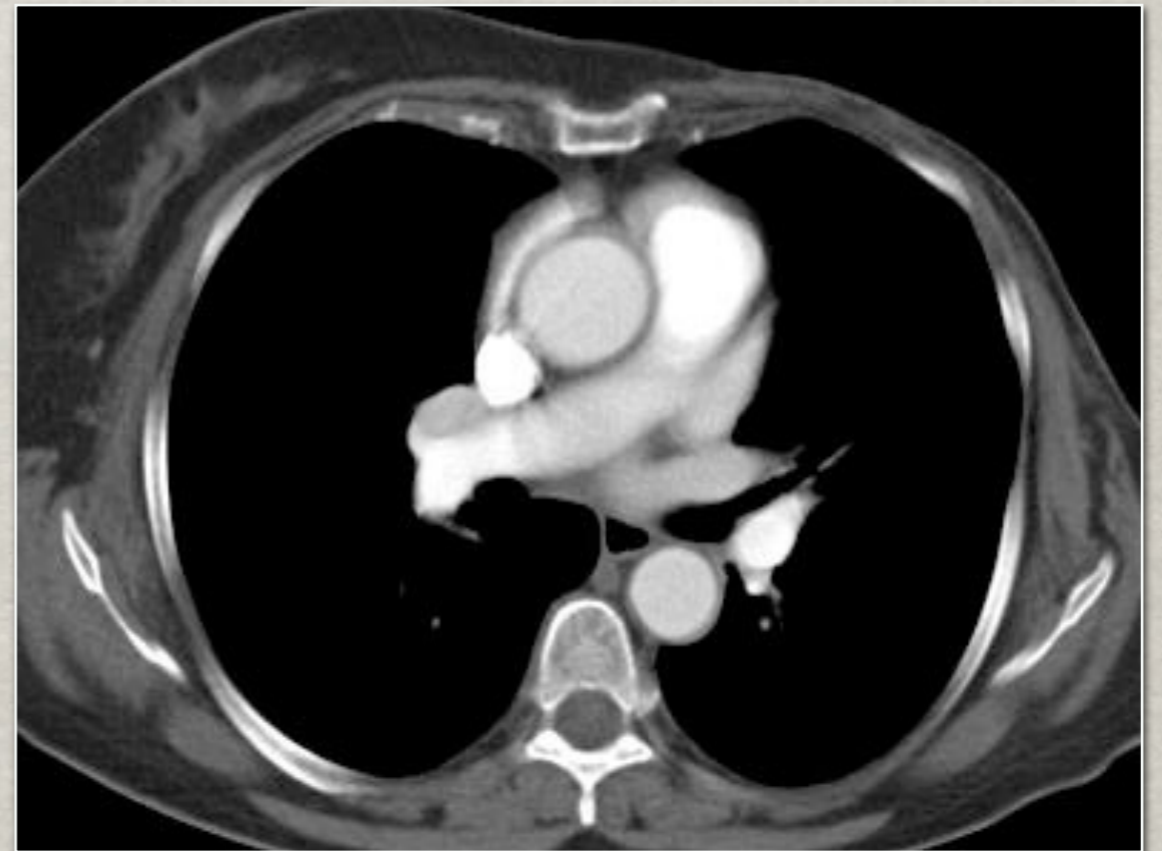
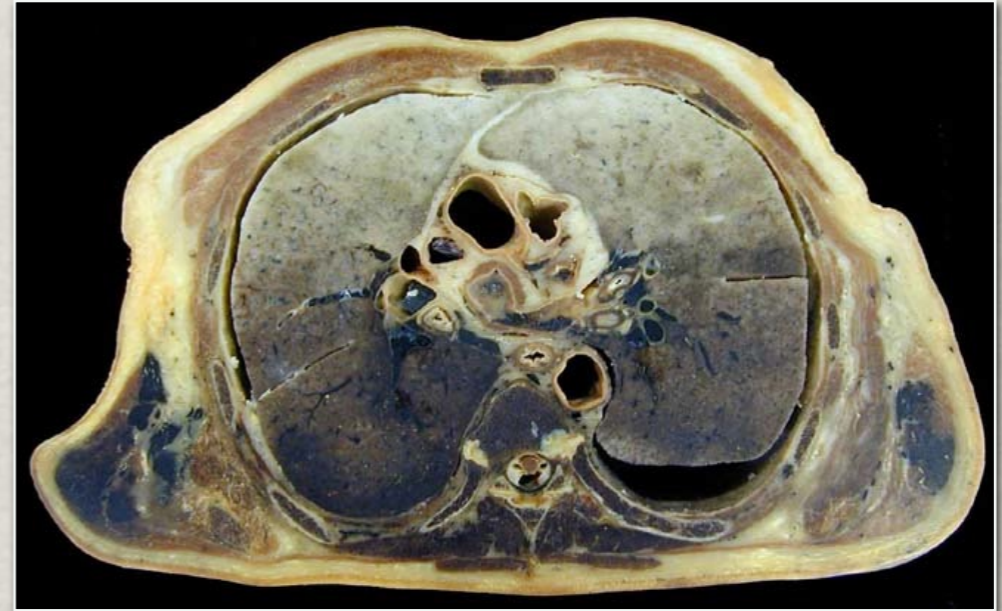Δεξιά πνευμονική αρτηρία

Κατιούσα αορτή

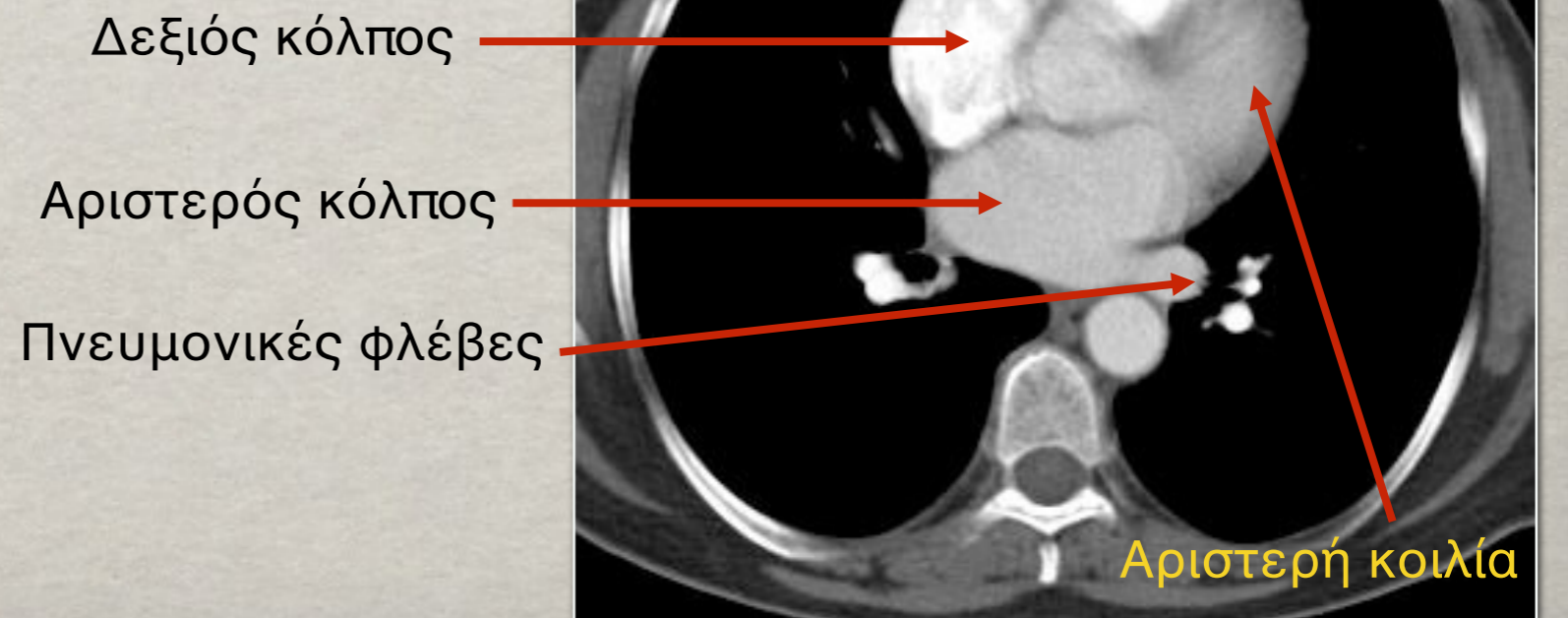
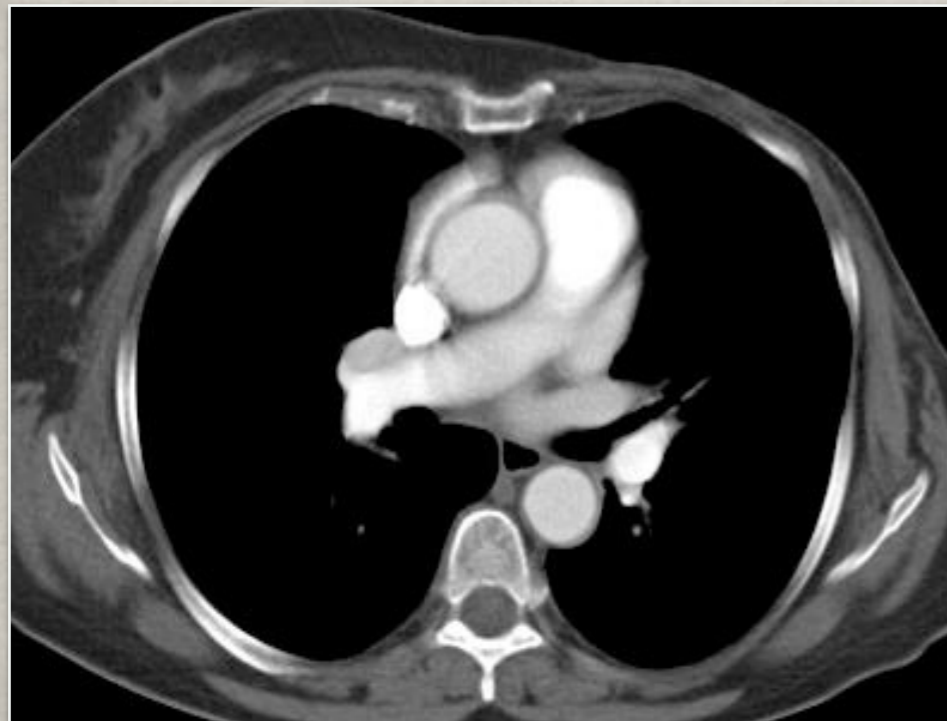
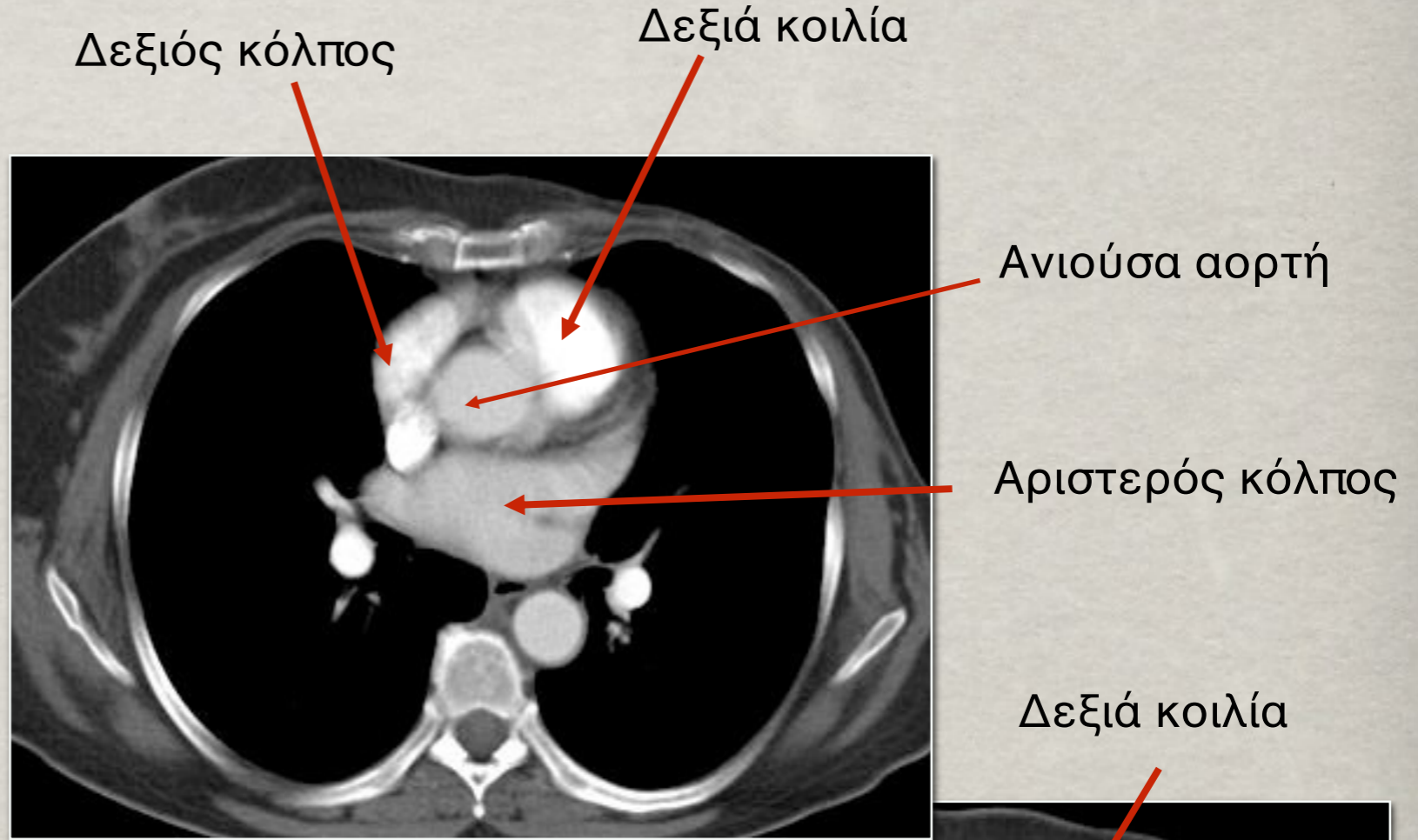
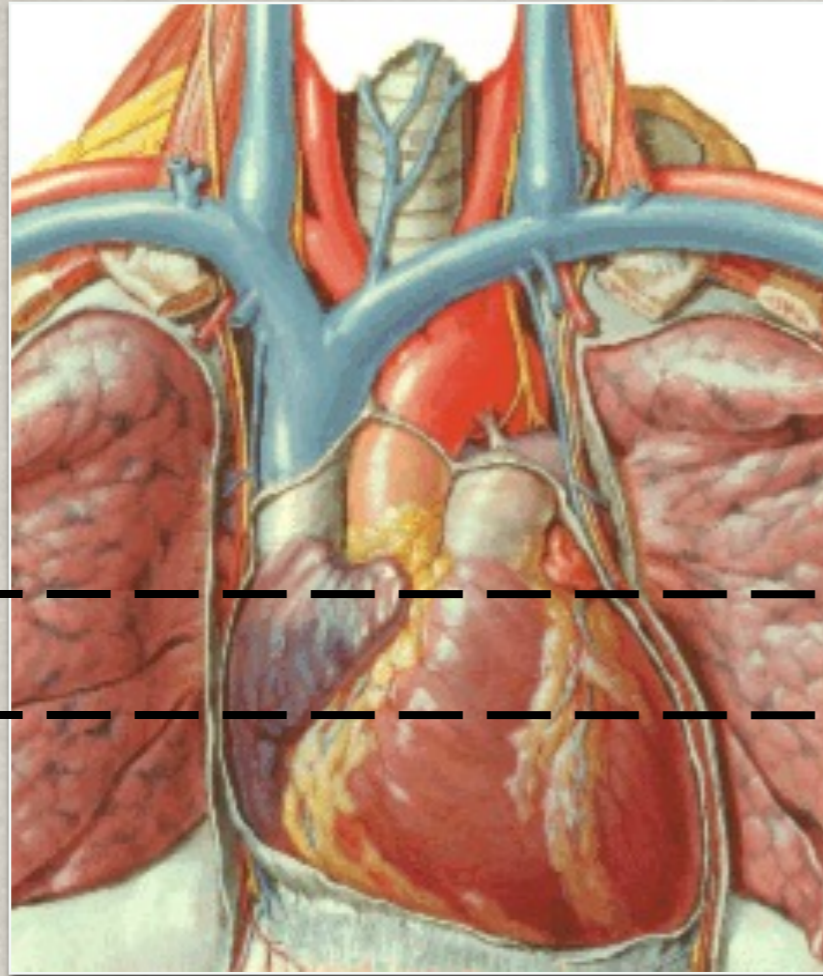


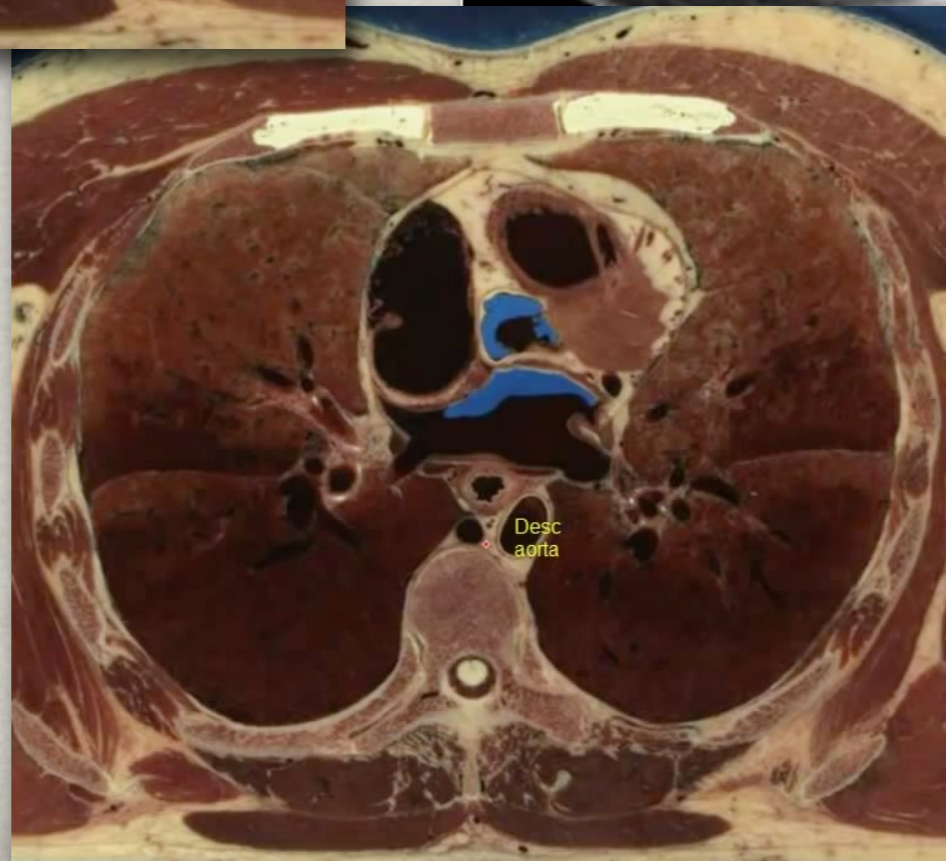
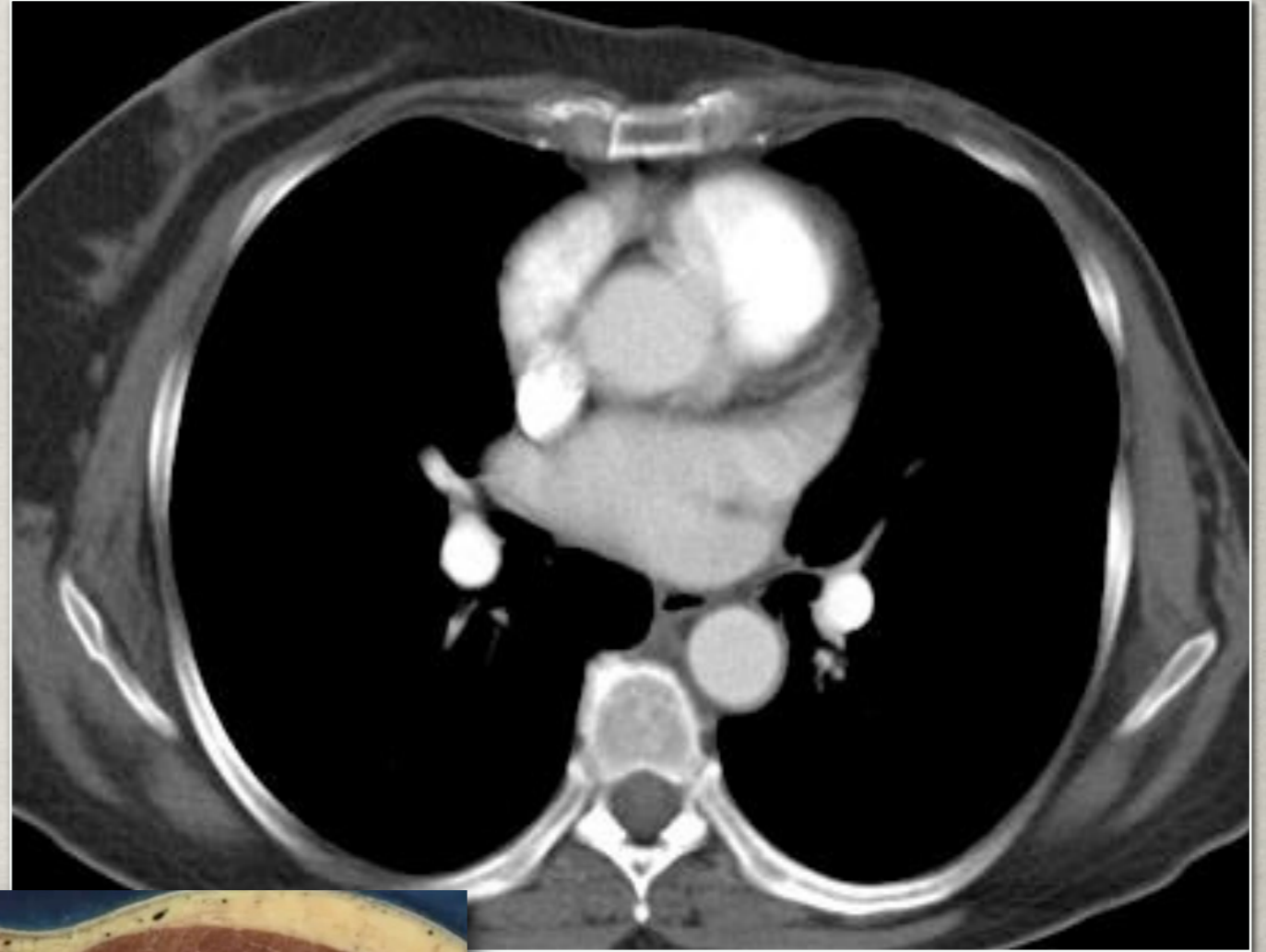
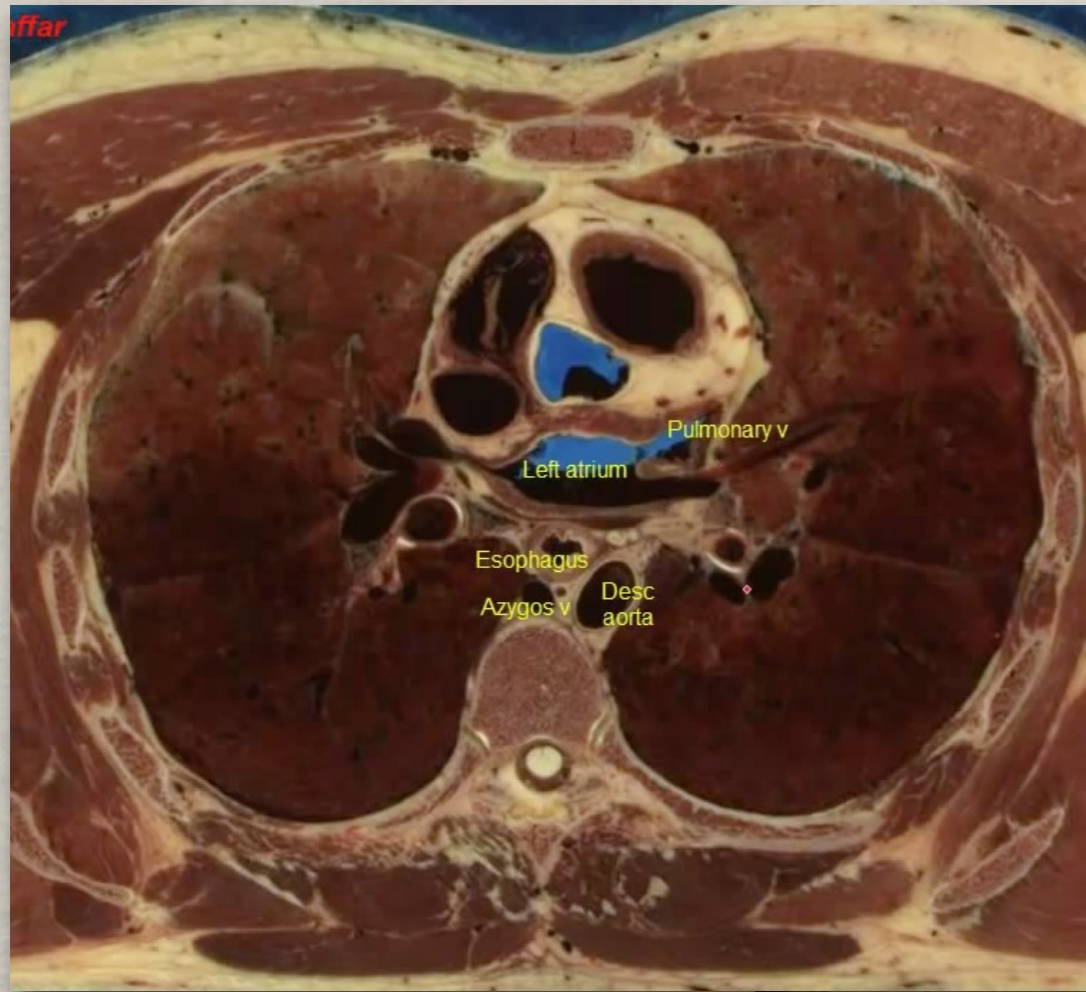


Πνευμονικές φλέβες

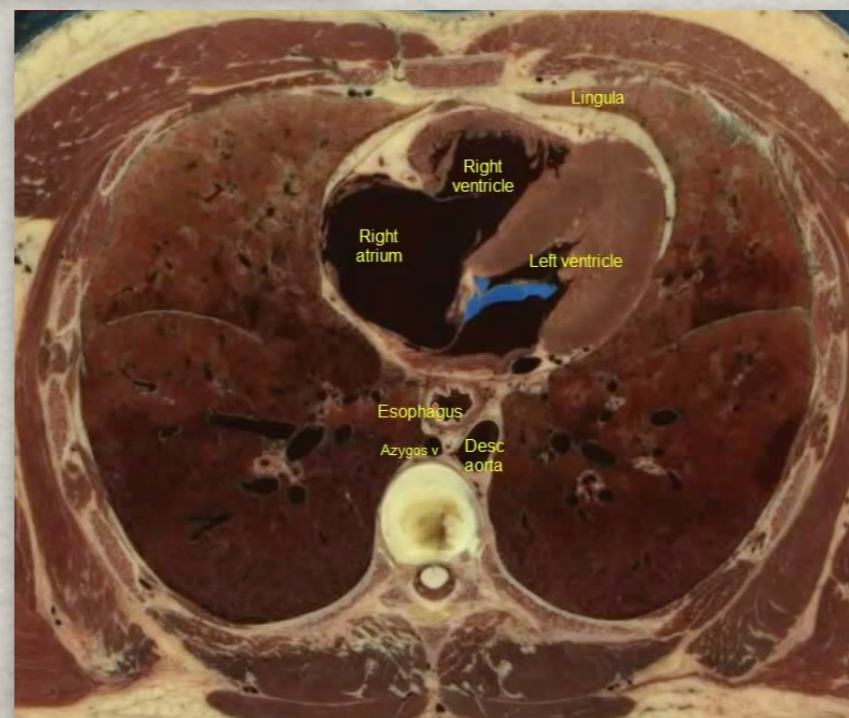
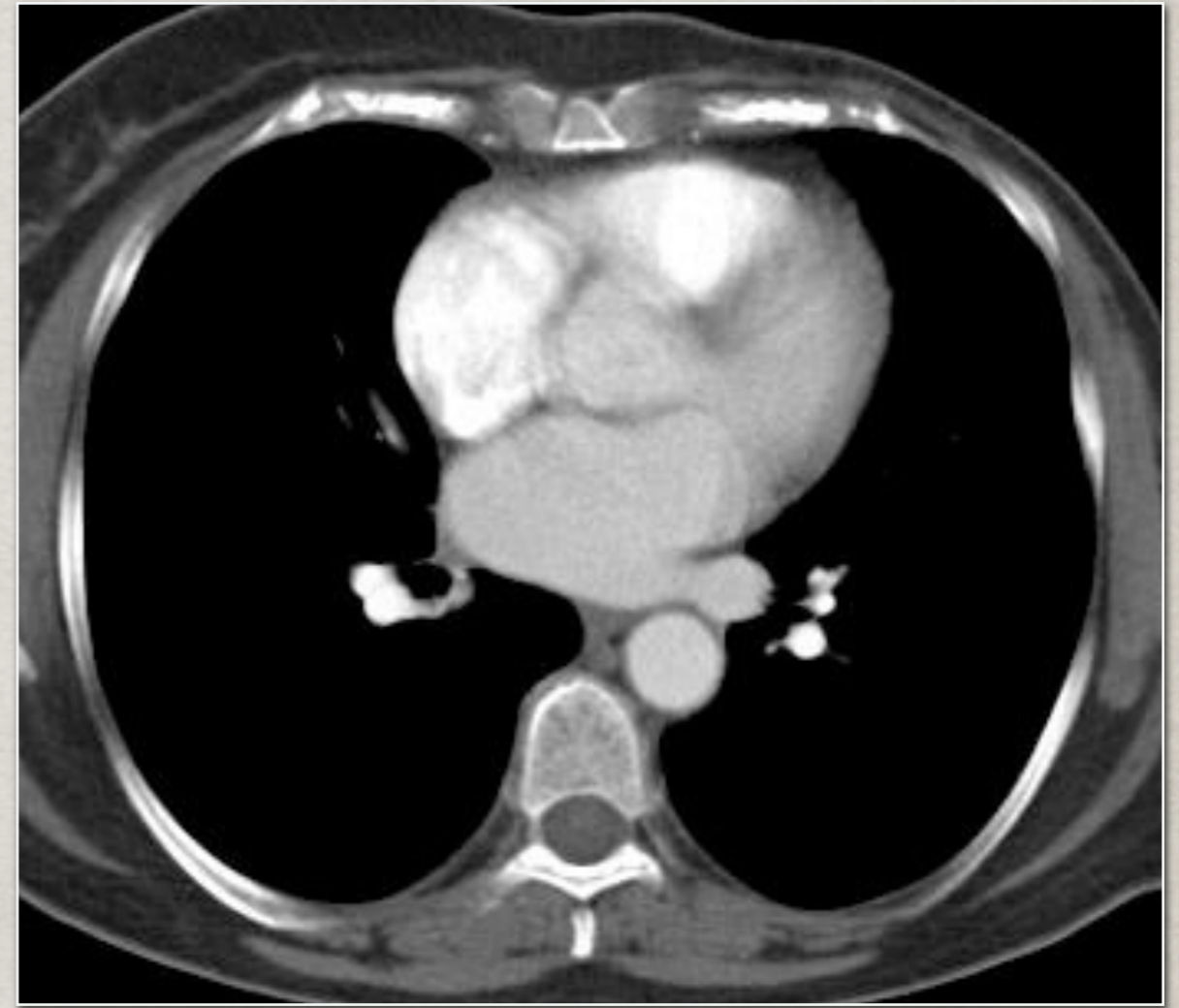
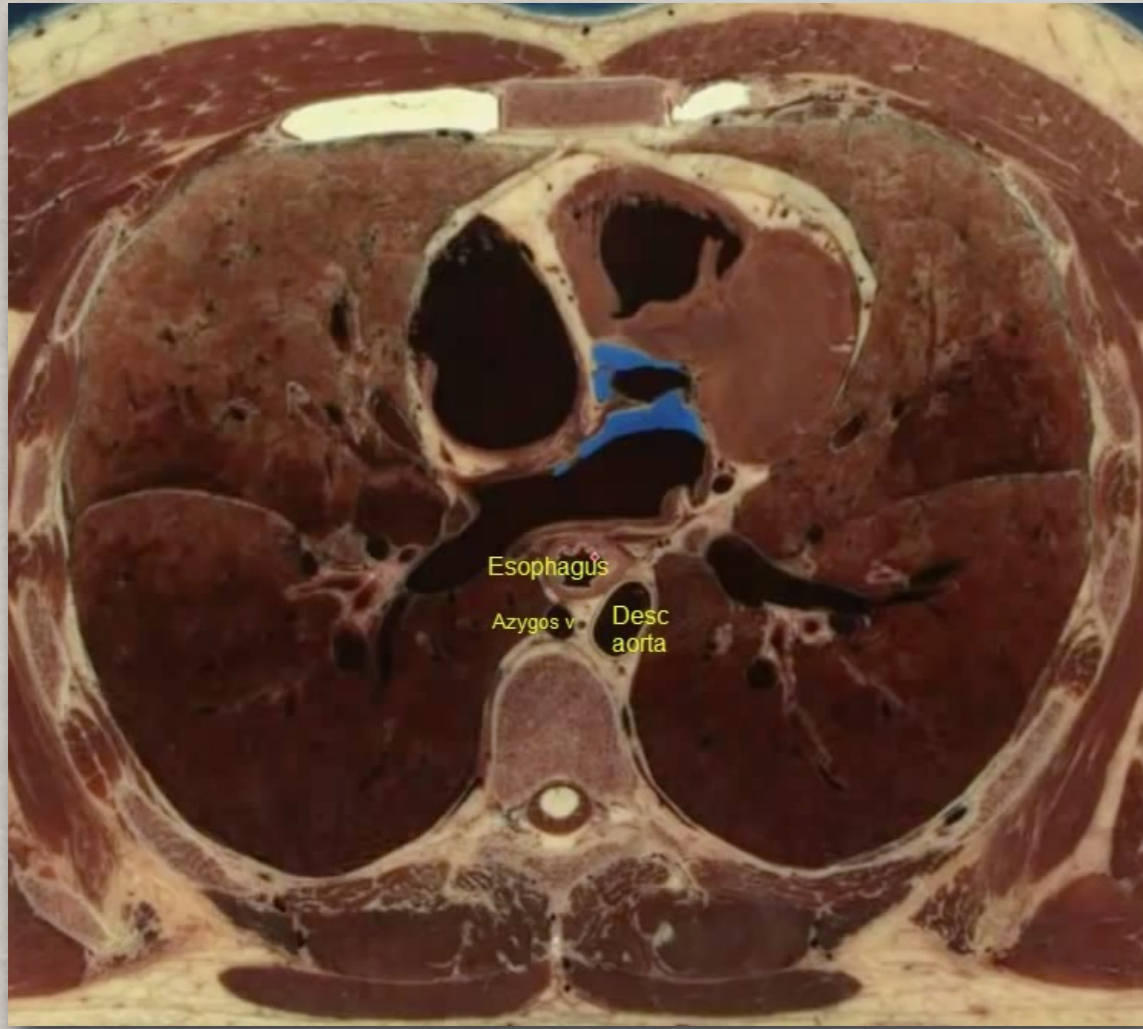


ΘΩΡΑΚΑΣ

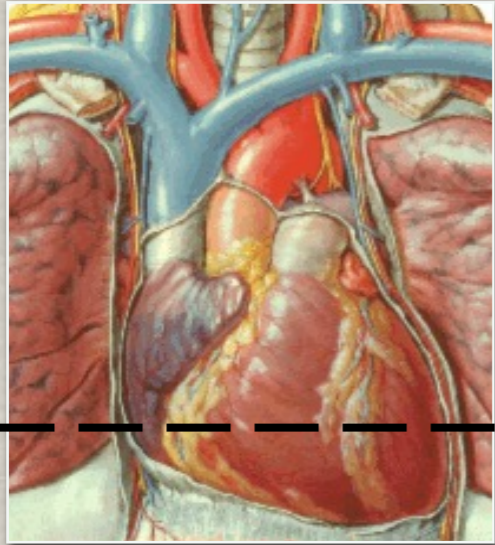




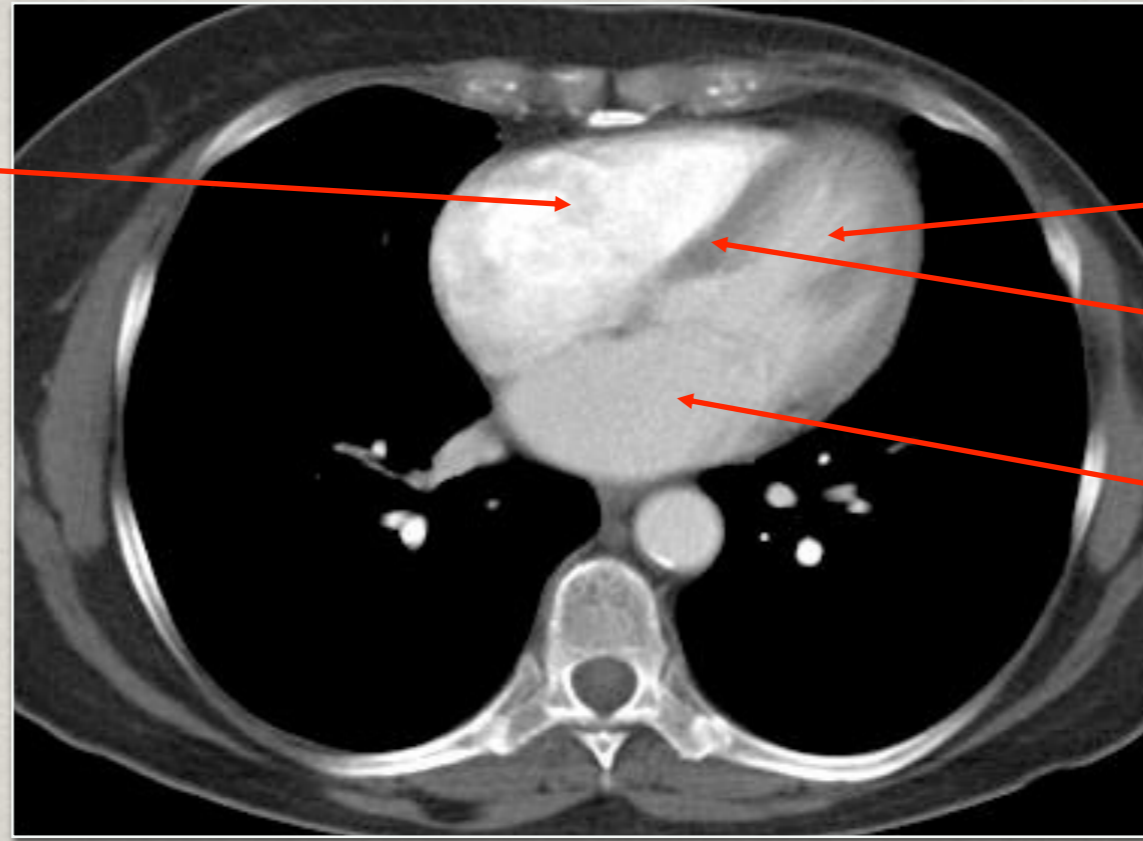
ΘΩΡΑΚΑΣ



ΘΩΡΑΚΑΣ



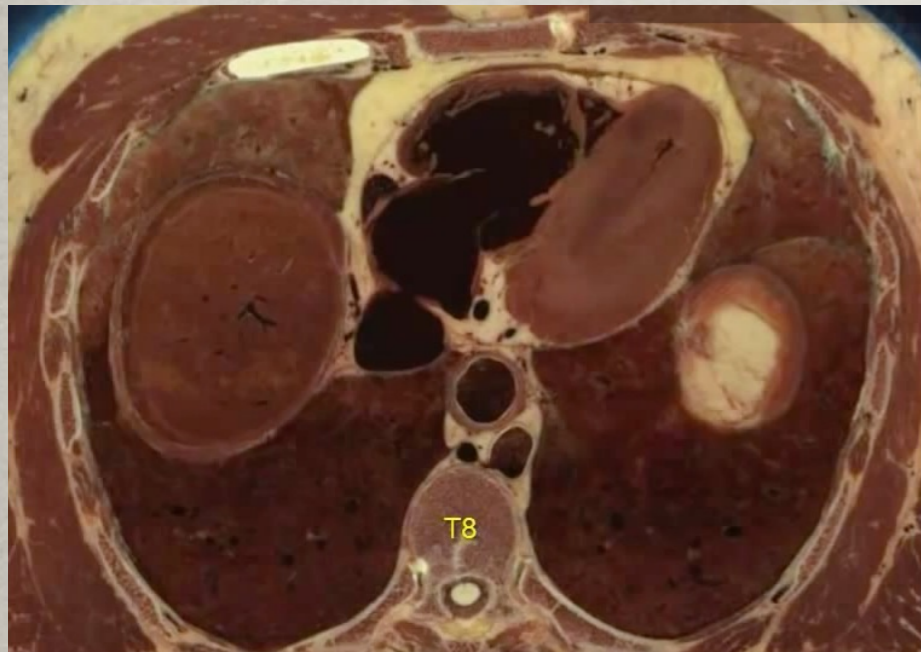
Δεξιά κοιλία



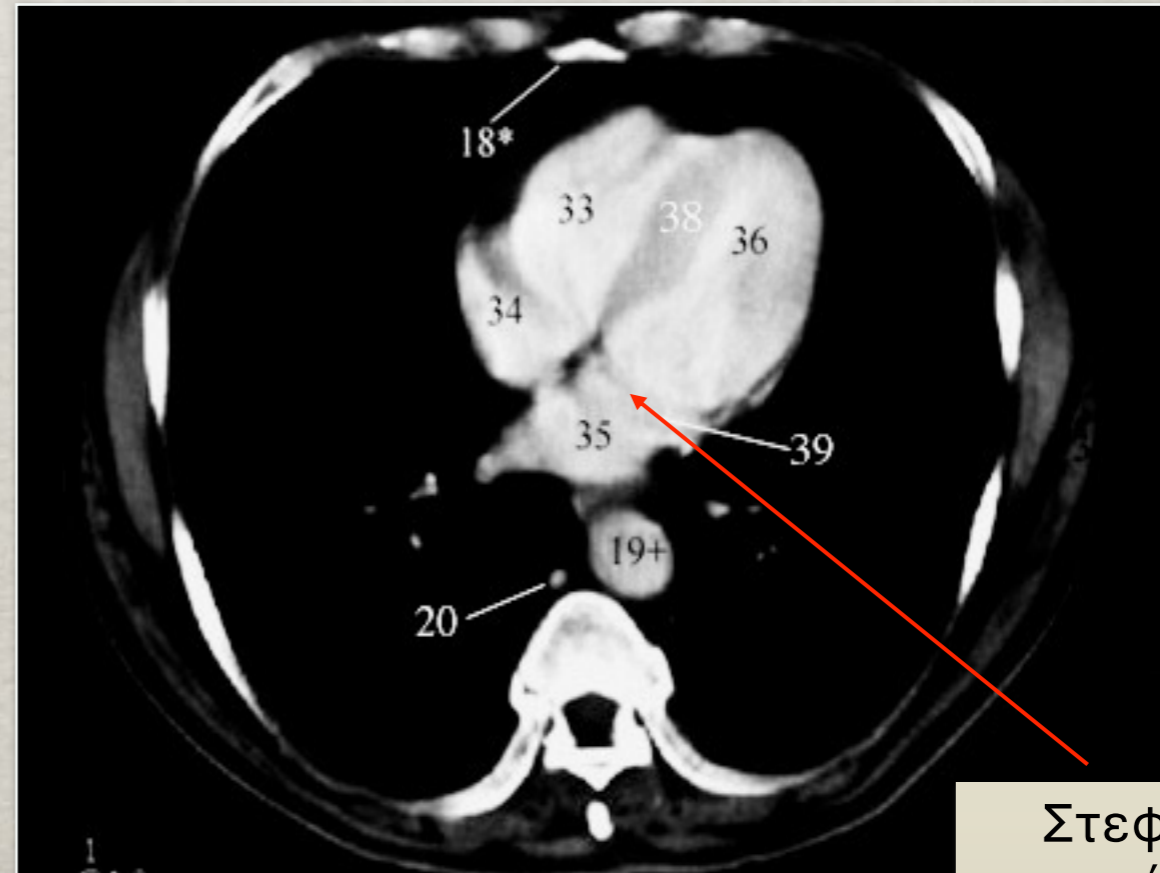
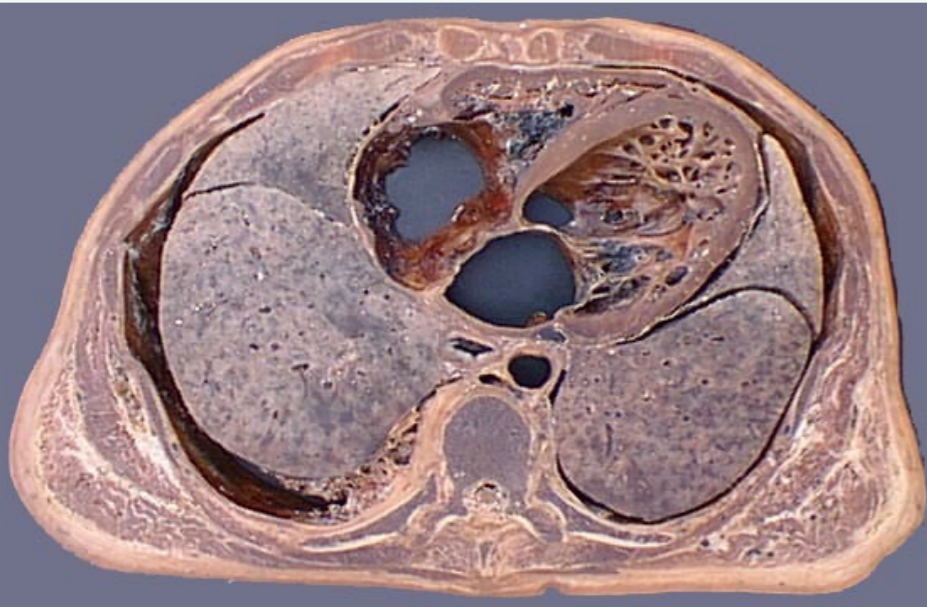
Αριστερή κοιλία

Μεσοκοιλιακό
διάφραγμα

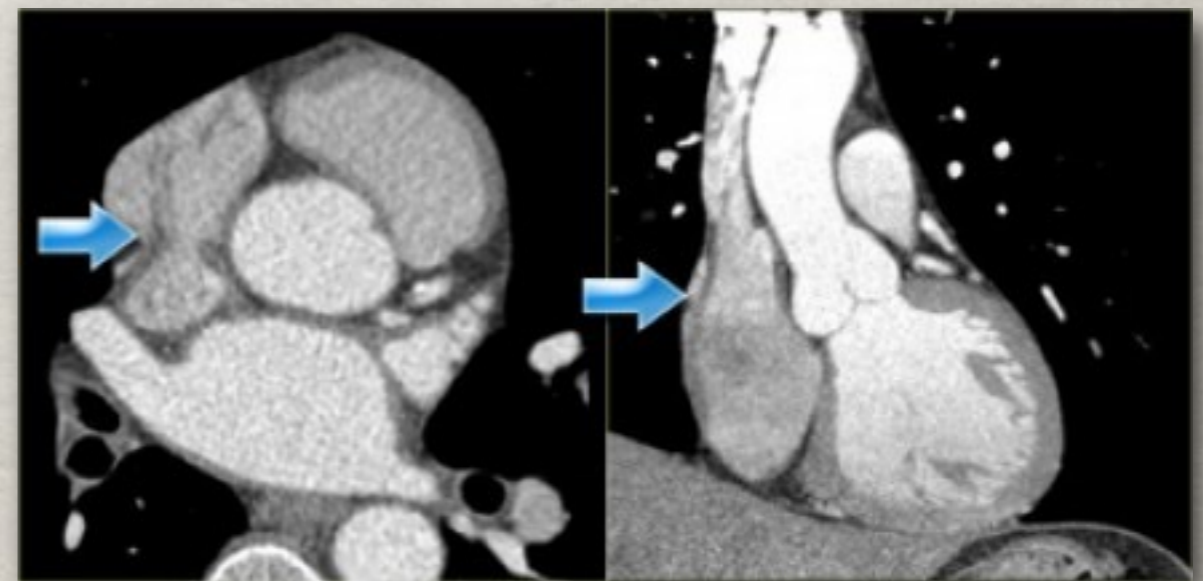
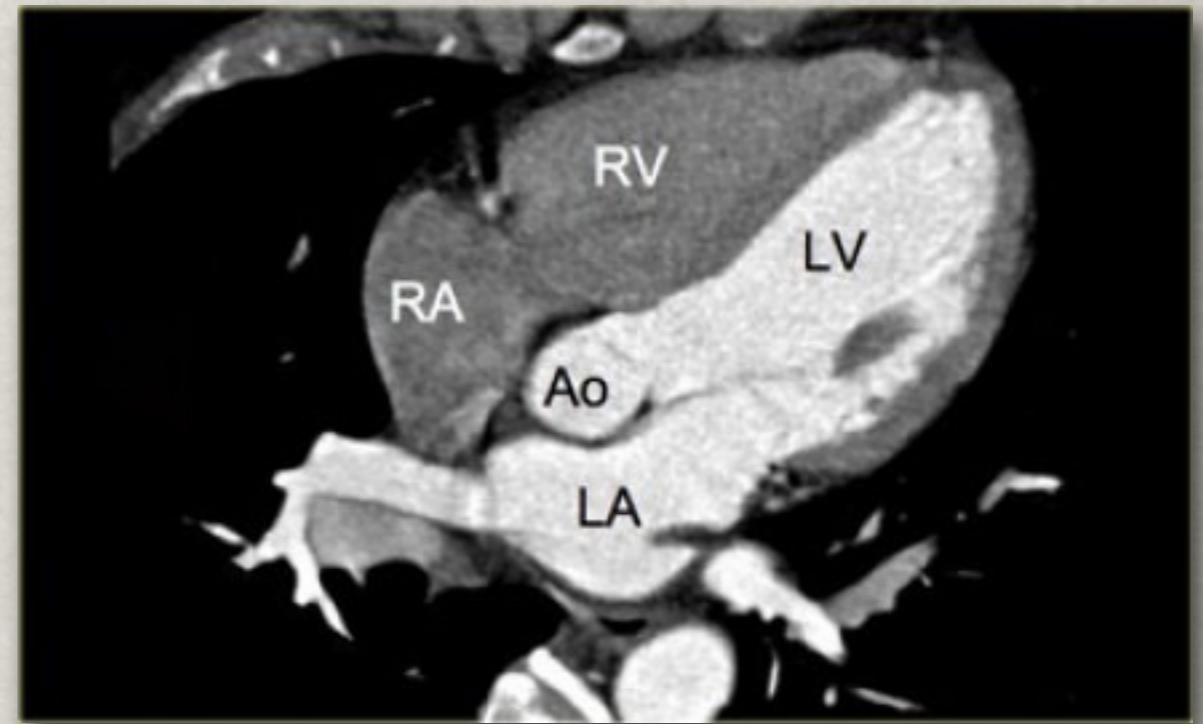
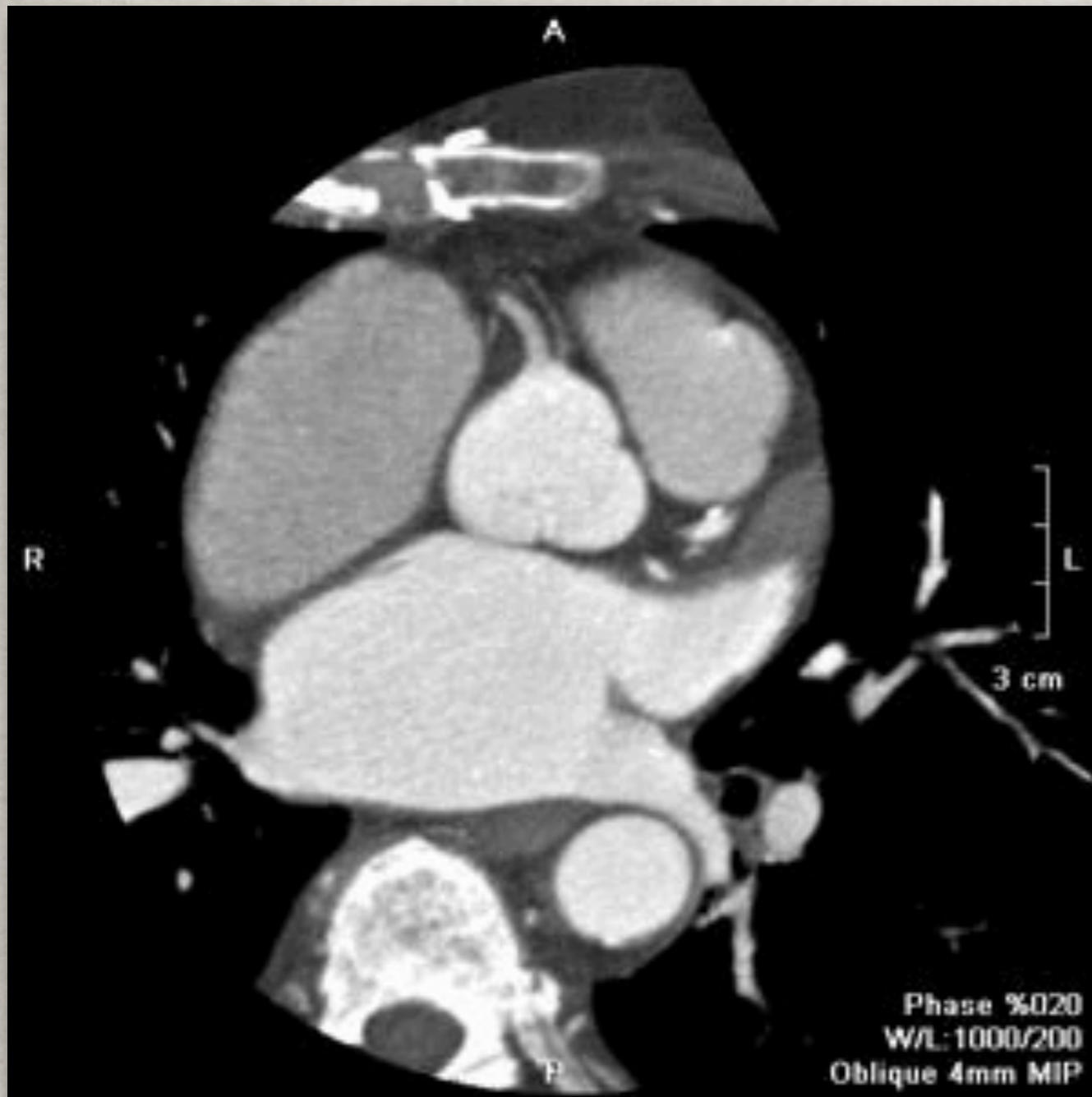Αριστερός κόλπος



T8



Στεφανιαίος
κόλπος



Τελική ακρολοφία

